




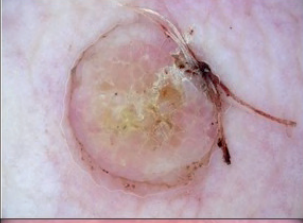

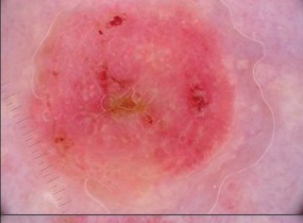



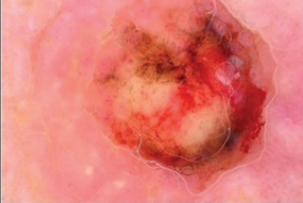
Patient	Clinical presentation	Dermoscopic appearance
1		
2		
3		
4		
5		

Fig. S1. Clinical and dermoscopic appearance in 5 patients with mammary Paget's disease.