

## SHORT COMMUNICATION

## CHILD Syndrome: Effective Treatment of Ichthyosiform Naevus with Oral and Topical Ketoconazole

Tao Liu<sup>1#</sup>, Ge Qian<sup>2#</sup>, Xiao Xia Wang<sup>1</sup> and Yan Guo Zhang<sup>1\*</sup><sup>1</sup>Department of Dermatology, Tangdu Hospital, The Fourth Military Medical University, No. 569 Xinsi Road, 710038 Xi'an, and <sup>2</sup>Department of Dermatology and Venereology, Zhengzhou Children's Hospital, Zhengzhou, China. \*E-mail: mengxh@fmmu.edu.cn<sup>#</sup>These authors contributed equally to this work and should be considered as first authors.

Accepted Apr 1, 2014; Epub ahead of print Apr 3, 2014

Congenital hemidysplasia with ichthyosiform naevus and limb defects (CHILD) syndrome is an X-linked dominant disorder with fatality for male embryos (1, 2). The disorder is caused by mutations in *NSDHL* (NAD[P]H steroid dehydrogenase-like protein), which is of importance in the cholesterol biosynthetic pathway (3). CHILD naevus, representing a peculiar inflammatory keratinocytic naevus, is a characteristic feature of CHILD syndrome (1). In most cases, this skin disorder shows a distinctive lateralisation pattern with a strict midline demarcation and affinity to body folds (4, 5). Recently, new therapeutic approaches based on the pathogenesis have been developed (6, 7). A body of evidences show that ketoconazole can influence cholesterol biosynthesis via cytochrome P450 enzyme (8); that ketoconazole might thus be a promising agent to the cutaneous lesions of congenital ichthyoses induced by cholesterol metabolic disturbances.

## CASE REPORT

A 15-year-old girl presented with inflammatory skin lesions involving several regions on the left side of her body. The cutaneous changes had been noted shortly after birth. Clinical examination showed well demarcated, mildly exudative and crusted inflammatory lesions in the left axillary and vulvar areas with strict lateralisation, ptychotropism, and hypertrophy of the ipsilateral labium majus (Fig. 1). She did not complain about uncomfortable feelings such as itching, burning and pain. The left hand had multiple periungual hyperkeratoses with onychodystrophy of all left fingers (Fig. 1c). All of her left toes were also involved with brownish onychogryphosis, whereas the right hand and foot were unaffected. Ipsilateral hypoplasia of bones was also noted. X-ray examination showed hypophalangism of the left index finger and little finger. Comprehensive laboratory tests including routine

analysis of blood and urine, liver and kidney function tests were normal. Blood lipids were within normal limits, and related imaging of visceral organs yielded normal results. Histopathologic examination of the skin lesion involving the left axilla showed hyperkeratosis, parakeratosis, acanthosis and papillomatosis with scattered lymphocytic infiltrates in the dermis. Microscopic examination for the presence of fungi and fungal cultures of scratched scales and bioptic material, repeated 3 times were negative. Molecular analysis of DNA derived from lesional skin revealed a missense mutation c.395 C→T within the *NSDHL* gene. Her parents and younger brother were healthy. Based on the clinical and molecular data, a diagnosis of CHILD syndrome was made.

Before the presentation, her lesions had resisted to many remedies, including corticosteroids and systemic and topical retinoids. After obtaining informed consent, she was given 200 mg/day of ketoconazole as a tentative approach, which was stopped after 1 week because of elevation of serum alkaline phosphatase levels above twice the upper limit of normal. As the patient had begun to show a good response to oral ketoconazole therapy, we decided to apply topical ketoconazole (2%) in zinc oxide oil. A 90% reduction of cutaneous lesions in the left axillary and vulvar areas was observed on day 10 after onset of topical therapy (Fig. 2). After 3 months of maintenance topical treatment, no reoccurrence was observed, and then the topical treatment was stopped. During the following 4 years signs of reoccurrence in the form of rather small lesions were noted about 2 times a year, which promptly cleared after 2–4 weeks of topical ketoconazole therapy.

## DISCUSSION

CHILD naevus shows a unique lateralisation pattern with strict midline demarcation and ptychotropism (3, 9). In the X-linked dominant CHILD syndrome, the cholesterol biosynthesis is blocked by mutations in the *NSDHL* gene (3). Cholesterol, one of 3 important stratum corneum lipids, is needed to form the normal extracellular lamellar bilayer system that mediates barrier function (10).

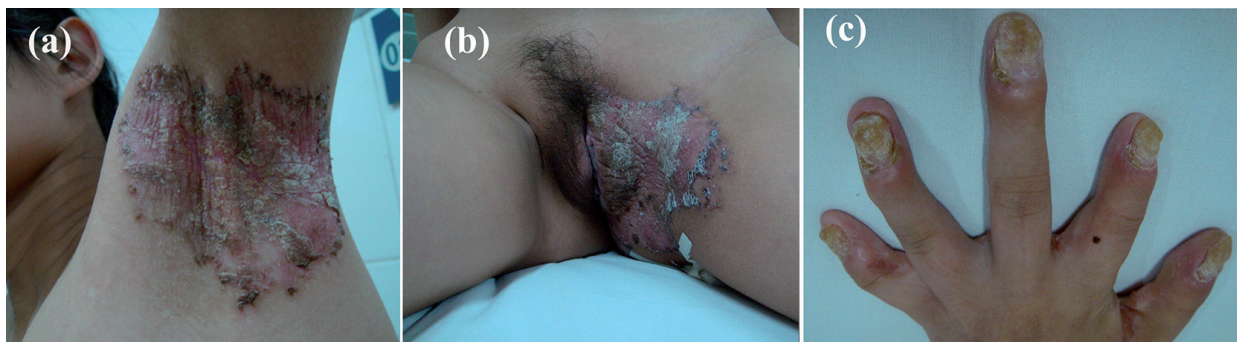

Fig. 1. Lesions of CHILD naevus before treatment. Involvement of (a) left axilla and (b) left labium majus. Periungual hyperkeratosis with fissuring and onychodystrophy of the fingers (c). Note hypophalangism of the left index finger and little finger.

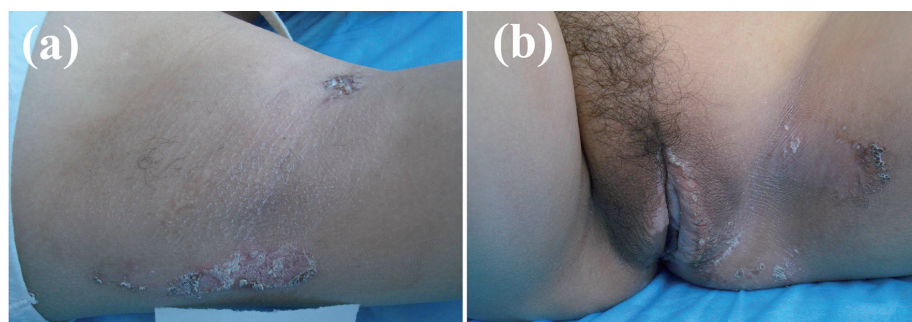


Fig. 2. Improvement of the skin lesions on day 10 after onset of topical therapy. Substantial clearance of (a) the left axillary lesion, and (b) the left labium majus and thigh. Note that the skin of the labium majus and mons pubis of the treated side is hairless and much lighter as compared to right side.

Lack of cholesterol in cell membranes and accumulation of toxic sterol precursors disturb the keratinisation process (11, 12). Inherited ichthyosiform dermatoses can be provoked by deficiency in intermediate pathway metabolites such as cholesterol, ceramides, and free fatty acids, or accumulation of toxic pathway metabolites in syndromic lipid metabolic disorders (5). Recently, topical application of a lovastatin-cholesterol lotion was shown to be an effective treatment for the CHILD naevus (5, 7).

Encouraged by the previously reported pathogenesis-based therapy (5–7), we attempted ketoconazole in this case. Ketoconazole, an antifungal agent, works by inhibiting CYP51, which catalyses demethylation of sterol precursors at the C14-position and produces meiosis-activating sterols (13). The inhibition of CYP51 may result in the reduction of metabolic products upstream of *NSDHL*, which thus decreases accumulation of toxic pathway metabolites of distal cholesterol metabolism. Another possible mechanism of action of ketoconazole is endogenous elevated levels of retinoic acid via inhibition of CYP26 (8). Indeed blocking the CYP26-mediated catabolism of endogenous all-trans retinoic acid has been shown to improve congenital ichthyoses (14). During our follow-up of the patient with CHILD naevus, intermittent topical treatment has convincingly shown that no systemic application is needed to exert the beneficial effect of ketoconazole on the skin lesions. Due to the rarity of this syndrome, it may not be possible to conduct a formal drug trial to confirm the therapeutic role of ketoconazole in CHILD syndrome.

#### ACKNOWLEDGEMENTS

This study was supported in part by National Natural Science Foundation of China (30900772).

*The authors declare no conflicts of interest.*

#### REFERENCES

- Happle R, Koch H, Lenz W. The CHILD syndrome: congenital hemidysplasia with ichthyosiform erythroderma and limb defects. *Eur J Pediatr* 1980; 134: 27–33.
- Happle R, Mittag H, Küster W. The CHILD nevus: a distinct skin disorder. *Dermatology* 1995; 191: 210–216.
- Koenig A, Happle R, Bornholdt D, Engel H, Grzeschik KH. Mutations in the *NSDHL* gene, encoding a 3 $\beta$ -hydroxysteroid dehydrogenase, cause CHILD syndrome. *Am J Med Genet* 2000; 90: 339–346.
- Happle R. Mosaicism in human skin: understanding the patterns and mechanisms. *Arch Dermatol* 1993; 129: 1460–1470.
- Paller AS, van Steensel MA, Rodriguez-Martín M, Sorrell J, Heath C, Crumrine D, et al. Pathogenesis-based therapy reverses cutaneous abnormalities in an inherited disorder of distal cholesterol metabolism. *J Invest Dermatol* 2011; 131: 2242–2248.
- Elias PM, Williams ML, Feingold KR. Abnormal barrier function in the pathogenesis of ichthyosis: therapeutic implications for lipid metabolic disorders. *Clin Dermatol* 2012; 30: 311–322.
- Szabo GP, Olah AV, Kozak L, Balogh E, Nagy A, Blahakova I, et al. A patient with Smith-Lemli-Opitz syndrome: novel mutation of the *DHCR7* gene and effects of therapy with simvastatin and cholesterol supplement. *Eur J Pediatr* 2010; 169: 121–123.
- Osanai M, Petkovich M. Expression of the retinoic acid-metabolizing enzyme CYP26A1 limits programmed cell death. *Mol Pharmacol* 2005; 67: 1808–1817.
- Bittar M, Happle R, Grzeschik KH, Leveleki L, Hertl M, Bornholdt D, et al. CHILD syndrome in 3 generations: the importance of mild or minimal skin lesions. *Arch Dermatol* 2006; 142: 348–351.
- Feingold KR. The regulation and role of epidermal lipid synthesis. *Adv Lipid Res* 1991; 24: 57–82.
- Rodríguez-Acebes S, de la Cueva P, Fernández-Hernando C, Ferruelo AJ, Lasunción MA, Rawson RB, et al. Desmosterol can replace cholesterol in sustaining cell proliferation and regulating the SREBP pathway in a sterol-Delta24-reductase-deficient cell line. *Biochem J* 2009; 420: 305–315.
- Sabatini K, Mattila JP, Kinnunen PK. Interfacial behavior of cholesterol, ergosterol, and lanosterol in mixtures with DPPC and DMPC. *Biophys J* 2008; 95: 2340–2355.
- Strushkevich N, Usanov SA, Park HW. Structural basis of human CYP51 inhibition by antifungal azoles. *J Mol Biol* 2010; 397: 1067–1078.
- Pavez Loriè E, Gånemo A, Borgers M, Wouters L, Blockhuys S, van de Plassche L, et al. Expression of retinoid-regulated genes in lamellar ichthyosis vs. healthy control epidermis: changes after oral treatment with liarozole. *Acta Derm Venereol* 2009; 89: 12–20.