

## News in the Treatment of Venous Leg Ulcers

**Karsten Fogh<sup>1</sup> and Carita Hansson<sup>2</sup>**

<sup>1</sup>Department of Dermatology, Aarhus University Hospital, DK-8000 Aarhus C, Denmark and <sup>2</sup>Department of Dermatology, Sahlgrenska University Hospital, SE-413 45 Göteborg, Sweden  
E-mail: carita.hansson@vgregion.se

### Introduction

The treatment of leg ulcers includes treating the cause of the ulcer, all other factors contributing to healing problems and treating issues concerning the ulcer itself. To say that a patient has a leg ulcer does not mean that the patient has a diagnosis. The definition of a leg ulcer is an ulcer on the leg or foot below the knee that has not healed in 6 weeks (some use 4 weeks), while a venous ulcer has venous insufficiency as its most important cause.

The venous leg ulcer is the most common leg ulcer type, estimated to constitute approximately 75% of all leg ulcers. The most important issues in treating or counteracting venous insufficiency are surgery and compression therapy. Venous insufficiency can be divided into deep and superficial venous insufficiency. No surgical method in clinical practice today is available to eliminate deep venous insufficiency. Superficial venous insufficiency causes about half of the venous ulcers and since it is possible to successfully operate superficial insufficiency if the deep system is

normal, it is most important to assess the venous system. Clinical examination alone is not sufficient. To accurately define a venous ulcer as the vascular surgeons do, the new *CEAP* classification system should be used (Eklof et al). The *CEAP* classification is based on clinical manifestations (*C*), etiologic factors (*E*), anatomic distribution of involvement (*A*), and underlying pathophysiologic findings (*P*) and an investigation with colour duplex-sonography is necessary.

### Pathogenesis of venous leg ulcers

Valvular defects in leg veins cause increase in venous blood pressure leading to extravasation of erythrocytes and other blood components. Clinical signs of venous insufficiency include hypostatic eczema, oedema formation, hyperpigmentation and ulceration. Lipodermatosclerosis is often seen and this is due to a chronic, fibrosing, inflammatory process of the dermis. The clinical signs are generally located on the distal half of the calf and do normally not exceed the malleolar region.

### Diagnosing venous insufficiency

It is of great importance to diagnose patients with chronic leg ulcers in order to initiate proper treatment that should focus on the etiology and the cause of the leg ulcer. Therefore, it is important to recognize the clinical signs of venous insufficiency and to initiate objective measures in order to quantify the degree of venous insufficiency. The diagnostic tools

available in order to diagnose properly are measurements of systolic arm, ankle and toe blood pressures in order to differentiate between arterial and venous disease. Ankle pressure can be measured by use of a traditional blood pressure cuff and by use of a hand held Doppler device detecting the Doppler signal of the *arteria dorsalis pedis* or *arteria tibialis posterior*. Toe pressure is measured by using the strain gauge technique. If other causes than venous and/or arterial such as inflammation or immunological causes (i.e. vasculitis) are suspected, a skin biopsy specimen may be needed. Since the interpretation of the histology reading is difficult it should be done carefully, and taken 5 mm outside the ulcer margin. If a punch biopsy is used or a larger biopsy, these samples should be taken using an excision biopsy (1 cm) comprising the margin of the leg ulcer as well as a small portion of the ulcer bed. Many chronic ulcers will show varying degrees of vasculitis if the specimen is taken from the ulcer bed or too close to the ulcer. However, haemosiderin deposits in the skin biopsy specimen are indicative of a venous insufficiency. A skin biopsy taken in order to rule out or establish a tumour diagnosis should include the margin as well as some mm outside and from the ulcer bed.

### New diagnostic tools

New diagnostic tools include the use of a colour Doppler to determine venous insufficiency. The colour Duplex method using a Doppler is based on sonography and the method is able

to visualize reflux in the superficial venous system and in the perforators. When scanning the leg, change in colour from blue to red (or vice-versa) is indicative of venous reflux (Fig. 1). The method is very sensitive, selective and it is non-invasive. It has several advantages over the traditional phlebography. In addition to the superficial venous insufficiency, sonography is able to visualize deep venous insufficiency as a potential cause of leg ulcers.

### Treatment of venous insufficiency

#### *Treat all other factors known to affect the ulcer healing*

Besides treating the venous insufficiency, all patients having concomitant diseases (i.e. diabetes) should be treated to have the best results. Arterial insufficiency, smoking and oedema of other causes (i.e. oedema from renal or cardiac failure) should be considered and attended to. Erysipelas (cellulitis) in the vicinity of the leg ulcer is known to deteriorate healing and should be treated with systemic antibiotics.

#### *Treating the underlying cause of venous insufficiency*

Patient self care includes instructing the patients to keep their legs in a high position when resting, avoid carrying heavy loads and avoid standing still for a long time.

Compression therapy is the main therapy for venous leg ulcers, known to counteract venous hypertension,

improve venous return, improve microcirculation and reduce oedema in the tissue.

We have new modalities of compression therapy including bandages and stockings that may be used alone or together with intermittent pneumatic compression. The use of padding improves the compression therapy by levelling the pressure applied.

#### *Compression Therapy:*

- Elastic or High-stretched bandages
- Inelastic or Low-stretched bandages
- Compression stockings
- Multilayer compressions (two- three or four layer bandages)
- Intermittent pneumatic compression devices

**Elastic bandages** have high working and high resting pressures. The pursued pressures from an elastic bandage are 40 mm Hg at the ankle, 30 mm Hg at the calf and 20 mm Hg below the knee.

The **inelastic bandages** have high working and low resting pressures, and are the first choice for patients with simultaneous arterial circulation impairment.

*Compression stockings* are normally used after ulcer healing for prophylactic purposes; they need an exact fit to exert best compressive effect. Compression stockings are produced in different classes (I-IV) depending on the degree of pressure delivered by the individual stocking. Stockings can be produced according to the

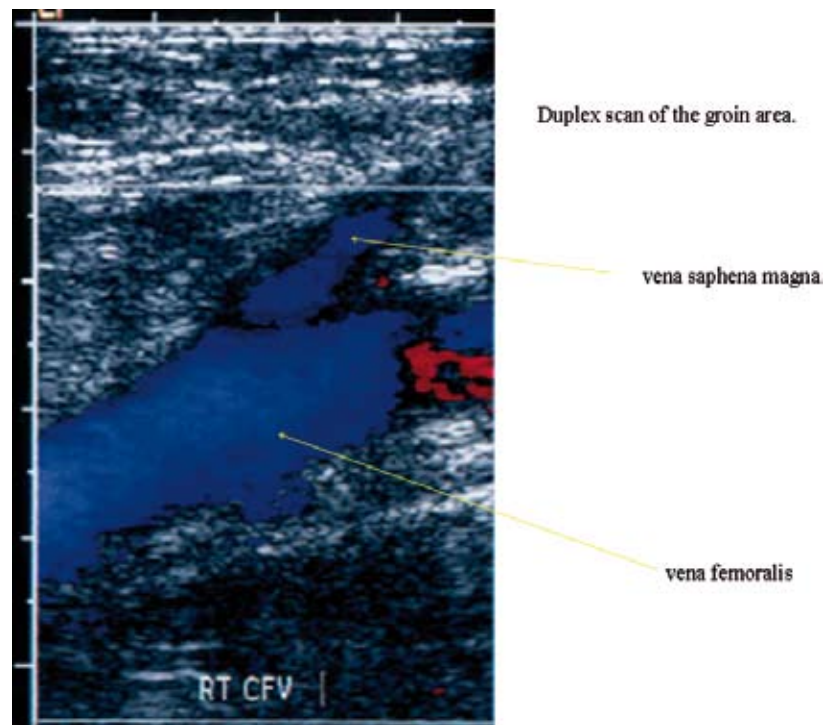


Fig. 1. Duplex scan of the groin area. Blue color shows bloodflow in vena femoralis and vena saphena magna. (Photo Karsten Fogh)

specific needs and wishes of the individual patient.

*Intermittent pneumatic compression devices* (IPC) are composed of a double-walled boot, which is filled and emptied, in sequences by an air compressor device. It is very useful for eliminating oedema. The brand Flowtron™ is used in Sweden and Denmark and made by Huntleigh (www.huntleigh.se).

IPC has contraindications:

- An untreated leg oedema caused by heart failure
- Current skin infection on the leg (i.e. erysipelas or cellulitis)
- Acute deep vein thrombosis
- Superficial arterial by-pass
- Pronounced ischemic vascular disease
- Prominent deformities in the skeleton making treatment impossible

### **Surgery**

The surgeon bases his decision if there is a possibility to perform venous surgery on the findings from the colour Duplex readings. Surgery can be performed on superficial incompetent veins and on incompetent perforators. Subfascial endoscopic perforator surgery (SEPS) is a new technique for treating perforating veins. Valvular reconstruction of insufficient valves of the deep veins is still experimental and not established as a method for surgical correction of deep venous insufficiency.

### **Local ulcer treatment also called wound bed preparation**

Normal wound healing runs through several phases including inflammation, proliferation and maturation. Chronic wounds generally do not “obey” these rules and therefore require the best possible environment

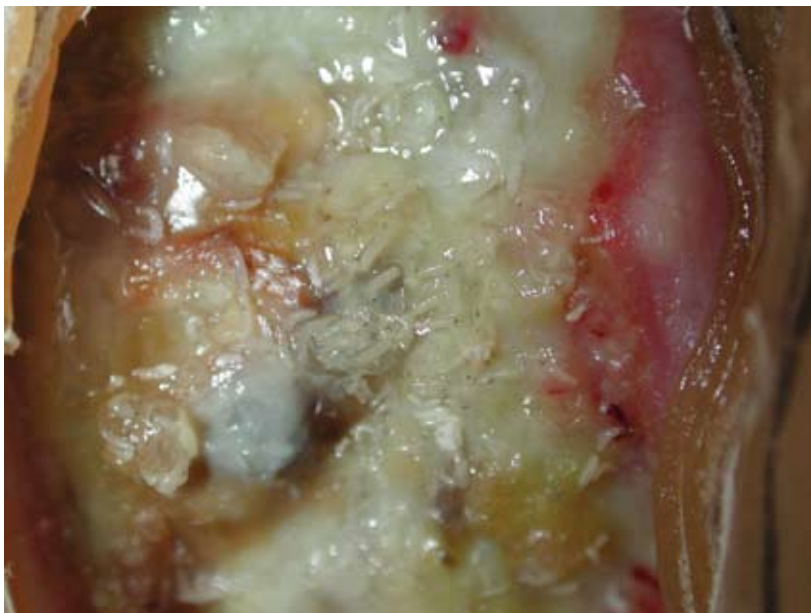
for stimulation of wound healing. The principle for healing chronic wounds is moist wound healing. Preserving wound exudates by using absorbing dressings for the high-exuding wounds or by adding a gel to the low-exuding wounds creates a moist environment. However, in addition to exudate management, local wound treatment also includes cleansing and debridement of the wound.

### **Debridement**

Debridement is to remove necrotic dead tissue and excess wound debris and slough. Venous leg ulcers seldom have necrotic tissue present. Several debridement methods are available including autodebridement where the ulcer’s own ability to clean the ulcer is used, creating a moist environment enhanced by gels or other gel making dressings (i.e. hydrocolloids, carboxymethylcellulose, alginates) or preserving a moist environment (i.e. foams).

Mechanical debridement starts by cleaning the ulcer with water or saline. The rinsing of the ulcer with tepid tap water is sufficient in areas with controlled drinking water. The rinsing may be performed with gauze or by using a shower. In some cases sharp debridement is needed and instruments like a curette or knife, tweezers and scissors are then used.

Debridement with maggots is also called biotherapy or larval therapy (Fig. 2). This method uses sterile larvae from the fly species *Lucilia Sericata*



**Fig. 2.** Larvae 1–2 mm in size from the fly *Lucilia Sericata* are put in the ulcer and removed after 1–3 days when they have grown to 1 cm and are used to debride the ulcer from necrotic tissue and are known to reduce the bacterial burden. (Photo: Carita Hansson)

and the larvae are put in the ulcer for 1-3 days. The maggots only digest necrotic tissue and bacteria. Maggots have no effect on living healthy tissue. Larval debridement not only makes the ulcer clean but often starts the production of granulation tissue. The larvae are sensitive and the treatment cannot be combined with compression therapy since the pressure kills the larvae. The larvae also need oxygen and a moist but not wet or dry environment. This debridement procedure is therefore more demanding and more time consuming to perform, and staff need more instructions to perform the larval therapy even if the outcome usually is the most satisfactory.

**Vacuum-assisted closure (VAC)** or topical negative pressure (TNP) is a method used in order to increase wound healing and has been shown to decrease bacteria in the ulcer

and oedema around the ulcer (Fig. 3). Furthermore, VAC treatment increases blood flow around the ulcer and stimulates growth of granulation tissue. A suction tube is connected to a vacuum pump and the tube is put in the foam applied to the ulcer. A semi-occlusive bandage covers the ulcer area and surrounding skin. Since it is expensive equipment, direct-leasing from the company (KCI) is the most commonly employed way to achieve this treatment ([www.woundvac.com](http://www.woundvac.com)) (Loree 2004).

#### *Skin transplantation – grafting*

In a clean ulcer without signs of infection grafting usually speeds up the healing process. Grafting may also reduce ulcer pain. In larger ulcers meshed, split-thickness transplantation is more practical than pinch or punchgrafts. Donor skin is normally harvested from the thigh by the use

of a keratome and then meshed. Skin grafting is often preceded by VAC therapy in order to create granulation tissue of the ulcer bed. In some cases (i.e. cases with severe lipodermatosclerosis) it is necessary to excise the ulcer and the surrounding scar tissue down to the fascia. The fascia is then used as the basis for skin grafting. Skin grafting usually requires hospitalization for 2-3 weeks to obtain full take of the skin graft and to ensure re-epithelialization.

#### *Pinch- or punch grafts*

From the anaesthetized skin, preferably from the thigh, 3-5 mm large pieces of epidermal and dermal skin are taken. In a pinch graft, the pinched skin is cut off, while, in a punch graft the skin is removed with a rounded biopsy knife and scissors. The skin pieces are placed in the ulcer with several millimetres in between and are covered with a non-adhesive paraffin gauze dressing, in order to keep them in place. Resting for a few days after the transplantation with the leg elevated to avoid the formation of oedema is recommended together with compression treatment.

#### *New dressings*

In infected ulcers or wounds with a heavy load of bacteria, especially *Pseudomonas aeruginosa*, dressings with antimicrobial properties may be of value. In clinically infected ulcers with cellulitis systemic antibiotics should be given and the antimicrobial dressing could be used as a supplement.

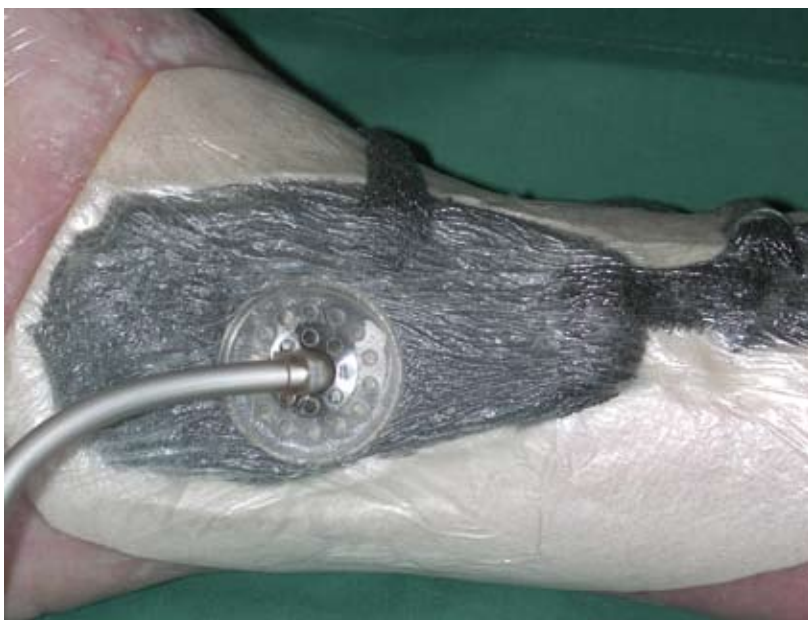

Fig. 3. Vacuum assisted closure (VAC) is used to remove oedema around the ulcer, debride the ulcer, and to increase the granulation tissue. (Photo: Carita Hansson)

Cadexomer iodine (Iodosorb™) is a slow-release iodine preparation with antimicrobial and debriding effects. Sorbact™ binds microorganisms by hydrophobic interaction. Aquacel™ consists of sodiumcarboxymethylcellulose and microorganisms are bound to the fibres. During the past years new silver dressings have emerged. Previously we only used Actisorb™ Plus 25, which combines both carbon against bad smell and silver. Another older silver dressing is silver sulfadiazine (Flamazine™) which mostly has been used for burns.

The silver dressings exercise their antimicrobial effect through the silver ion. There are several types (i.e. Acticoat™, Aquacel Ag™ and Contreet™) with different properties. There are, however, no clinical studies comparing these dressings in patients with venous leg ulcers.

### **New pharmacotherapy for venous leg ulcers**

Pentoxifylline (Trental™ tablets 400 mg) reduces white blood cell aggregation, blood viscosity, platelet

aggregation, as well as it increases fibrinolytic activity and has been shown to give added benefit when used in conjunction with compression therapy and possibly may be efficacious as monotherapy (Jull 2005).

Horse chestnut seed extract - Aesculus hippocastanum - (Venostat™, Venokan™ tablets) for chronic venous insufficiency related signs and symptoms have been evaluated in Cochrane Database and showed improvement in symptoms like leg volume and pain (Pittler 2005). There are, however, no studies that show effect on the healing of venous leg ulcers.

### **Prognostic signs**

Large baseline venous ulcer size and long duration of leg ulcer have been found to be indicators of poor prognostic signs. To see the percentage change in venous leg ulcer in the first weeks a prediction of healing by 6 months may be performed (Phillips 2000, Margolis 2004).

### **References**

- Eklof B, Rutherford RB, Bergan JJ, Carpentier PH, Gloviczki P, Kistner RL, et al.; American Venous Forum International Ad Hoc Committee for Revision of the CEAP Classification. J Vasc Surg. 2004; 40: 1248-1252. Revision of the CEAP classification for chronic venous disorders: consensus statement.
- Loree S, Domp Martin A, Penven K, Harel D, Leroy D. Is Vacuum Assisted Closure a valid technique for debriding chronic leg ulcers? J Wound Care. 2004; 13: 249-252
- Jull AB, Waters J, Arroll B. Pentoxifylline for treating venous leg ulcers (Cochrane Review) The Cochrane Library, Issue 4. Chichester, UK: John Wiley & Sons, Ltd, 2005.
- Margolis DJ, Allen-Taylor L, Hoffstad O, Berlin JA. The accuracy of venous leg ulcer prognostic models in a wound care system. Wound Repair Regen. 2004; 12: 163-168.
- Pittler MH, Ernst E. Horse chestnut seed extract for chronic venous insufficiency (Cochrane Review). The Cochrane Library, Issue 4. Chichester, UK: John Wiley & Sons, Ltd, 2005
- Phillips TJ, Machado F, Trout R, Porter J, Olin J, Falanga V. Prognostic indicators in venous ulcers. J Am Acad Dermatol. 2000; 43: 627-630.