

Purpura, Ulceration, and Necrosis as Manifestations of Cutaneous Vasculature Disorder with a Challenging Diagnosis

JULIA BERNATSKA-WOLFERT, MD¹ AND LUDMYLA DEREVYANKO, MD²

¹Board member of Veselka Foundation and ²Department of Dermatology and Venereology, National Medical Academy of Postgraduate Education, Kiev, Ukraine.

E-mail: jlberna2002@hotmail.com



We describe here an extremely challenging case for diagnosis and patient management. To save the patient's life in this particular case of a skin (and possibly internal organ) vasculature disorder of unknown aetiology required the combined expertise of an interdisciplinary and international team putting together both bedside and telemedicine approaches. We thank Drs O. Bortkevych, G. Kozynets, O. Yaremenko (Ukraine), T. Jacob, R. Edmund Voll (Germany), G. Nyman (Sweden), G. Koehn, J. Schmidt and S. Worobec (USA) for their valuable opinions and suggestions.

Cutaneous lesions with dynamic manifestation of livedo, possible nodules, purpura, ulcers, and necrosis should warn clinicians about underlying vasculature disorders, which require an urgent approach in patient management exploiting an interdisciplinary team. Based on aetiology and pathophysiological changes, these cutaneous vasculature disorders can be divided into two main groups.

The first group includes primary pathological changes in the vascular wall per se, known as vasculitides. The inflammatory reaction changes blood vessel thickness and affects the involved vessel's diameter and permeability. The second group includes a primary mechanical vascular obstruction, either by thrombi or emboli due to pathological changes in the coagulation system or embolic events (e.g. infectious, cholesterol, or fat emboli). As a result in both group disorders, blood flow in the skin becomes compromised and leads to tissue ischaemia. In some cases it is difficult to understand the primary reason for this ischaemic process, as certain patients may have a combination of vascular wall inflammation and mechanical vascular obstruction due to multiple underlying systemic disorders. To complicate the situation even further, vasculitis may trigger the creation of local thrombi, or primary thrombi/emboli may be a cause of an inflammatory reaction cascade affecting the vascular wall. However, diagnostic skin biopsy can be helpful in establishing a diagnosis when it is performed early enough after lesions appear, and at the right location and depth.

In the case described here, a final diagnosis was not established. Skin biopsy results, clinical presentation, diagnostic and laboratory test results were controversial and altogether did not fit the classical presentation of certain diagnosis. We considered several possibilities in a differential diagnostic process. Symptomatic and supportive treatment was provided.

In spite of seriousness of the situation, the patient survived several initial bouts of this peculiar condition. However, after more than 8 months of waxing and waning of the condition, the patient sadly died.

Case presentation

A 40-year-old woman was urgently delivered to the Internal Medicine Ward of the clinical hospital Feofaniya in February, 2011 with a primary diagnosis of necrotizing vasculitis. Her main complaint was of painful ecchymotic lesions with some degree of ulceration over her lower and upper extremities, and lower abdomen. Other symptoms included fever, polyneuropathy, encephalopathy with a vestibular component, and hepatomegaly. According to the patient's description, the skin lesions had begun approximately 3 weeks previously as two reddish pruritic maculae on her right leg after cold exposure. Her recent medical history revealed that she had had bouts of sinus infection and herpes simplex infection on her lips 2 months before the manifestation of her cutaneous lesions. At the same time she had developed pneumonia and unilateral lower back pain.

Dermatological examination was performed while the patient was at the Feofaniya hospital and the dermatological team worked together with other specialists to help the patient. Fig. 1 A–C show the extensive purpura lesions on this patient.

Her complete blood count revealed moderate anaemia (haemoglobin levels between 84 and 115 g/dl on several tests) with anisocytosis and poikilocytosis, leukocytosis (between 18,000 and 93,000/mm³ on several tests) with elevated neutrophils and lymphopaenia, and thrombocytosis (between 547,000 and 981,000/mm³). Blood cultures and urinary cultures were negative, and chest X-ray was normal. No abnormalities were

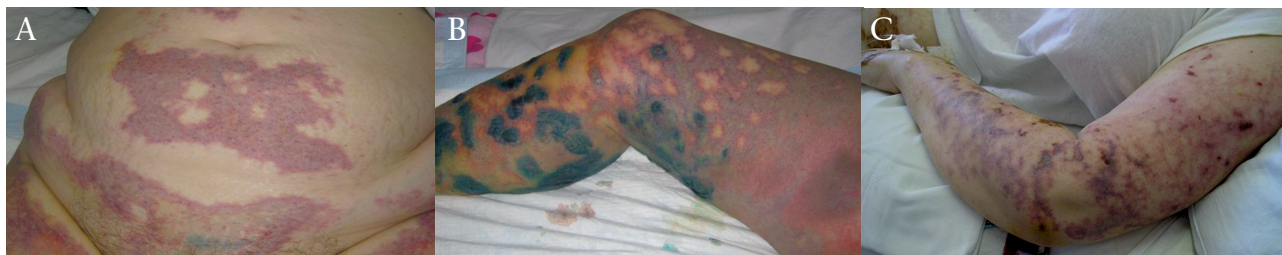

Fig 1. Extensive purpura lesions in the patients' (A) abdomen, (B) legs, and (3) arms.

seen on body computed tomography (CT)-scan, echocardiography, Doppler study of the extremities, or brain magnetic resonance imaging (MRI).

Initial treatment included multiple broad-spectrum antibiotics, systemic corticosteroids, aspirin, and heparins, both unfractionated and low-molecular weight heparin (LMWH). However, in just a few days her lesions progressed into an extensive area of necrosis that involved more than 40% of her body surface area (BSA). The patient faced jeopardy of septic complications and hypovolaemic shock. Fig. 2 A–B demonstrate the drastic necrosis.

The patient was moved to Kyiv Burn Hospital, where their team performed extensive critical care therapy, pain management, necrectomy, and skin grafting. The patient survived this extremely dangerous condition and was doing better 6 weeks after the initial hospitalization in February, 2011. However, the second bout of purpuric skin lesions, rapidly turning into necrosis, started in May. The patient was hospitalized at the Feofaniya hospital again. Until her death at the end of October 2011, she suffered from several bouts of these necrotizing skin lesions.

Discussion

This challenging case did not lead to a final reassuring diagnosis. Taking into consideration multiple physical and laboratory test results, the patient did not have obvious internal organs involvement for many months after these peculiar cutaneous necrotizing lesions started. With symptomatic and support-

ive treatment this woman was able to survive several bouts of this condition. However, since August 2011 she suffered from developed wound infection including *Pseudomonas aeruginosa* and *Staphylococcus aureus*. She sadly died in October and her family did not give permission for an autopsy. We would like to discuss the differential diagnoses and their criteria in order to bring colleagues' attention to our process and the complexity of this case.

Necrotizing vasculitis

The initial suspicion of necrotizing vasculitis (1) was based on the clinical presentation of ecchymotic (up to ulcers and necroses) skin lesions, sinusitis, and pneumonia. This constellation of symptoms could be specific for either Wegener's granulomatosis or Churg-Strauss syndrome. Another name for this group of vascular disorders is leukocytoclastic vasculitides, as common histological findings include intramural and perivascular infiltration by both normal-looking and fragmented ("clasted") neutrophils. There is also hyalinization and necrotic changes in the vascular wall of small- and medium-sized blood vessels. However, a skin biopsy in this particular case revealed bland skin vessel thrombosis and thrombi recanalization without significant changes in or around vascular walls. Neither multinucleated giant cell nor eosinophils were detected.

Unfortunately, skin biopsy procedures are not widely used in Ukraine, and with this patient the skin biopsy was performed just once. Obviously, such practice makes this

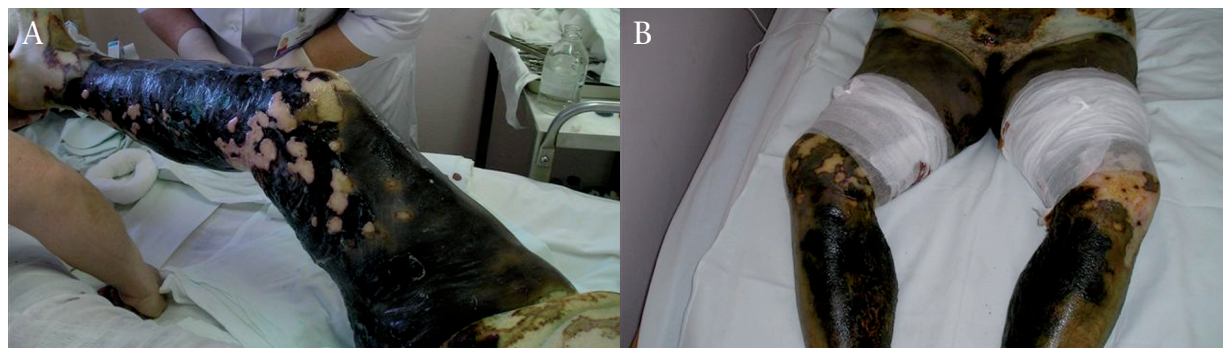


Fig. 2. A drastic necrosis involving more than 40% of the patient's body surface area.

and other cases even more challenging in their diagnostic approach.

Laboratory tests revealed negative anti-neutrophil cytoplasmic antibodies (ANCA), neither cytoplasmic (c-ANCA), nor peri-nuclear (p-ANCA). In general, the presence of c-ANCA is rather specific for Wegener's granulomatosis and p-ANCA can point to Churg-Strauss syndrome, but there is a possible ANCA markers overlap and these positive laboratory findings cannot be a sole diagnostic criterion. Both diseases have common symptoms of pulmonary, renal, and sinuses involvement, and the systemic work-up for this patient was made taking into consideration her recent history of pneumonia, unilateral lower back pain, and sinusitis.

Chest X-ray revealed neither nodules in the lungs or mediastinum, nor other suspicious changes; she had no signs of renal involvement as her creatinine and urea levels were within normal ranges, and urinalysis detected no haematuria; otorhinolaryngological examination discovered atrophic, not allergic, rhinitis without ulceration or granuloma formation. There was no gingival hyperplasia. All of these findings help to rule out Wegener's granulomatosis or another disease within small-vessel vasculitis group, microscopic polyangiitis. In addition, complete blood count showed no eosinophilia and the patient had no history of asthma. These findings exclude Churg-Strauss (allergic granulomatosis) syndrome. The diagnosis of this type of ANCA-positive vasculitides is crucial in prescribing cyclophosphamide treatment that significantly increases patients' survival. Another disease that should be taken into diagnostic consideration within the group of vasculitides is polyarteritis nodosa.

Polyarteritis nodosa is classified as two types: the systemic type with an involvement of the vasculature of many organs, and the localized cutaneous type. It is a type of vasculitis with a major involvement of medium-size arteries. Clinically, it can be very difficult to distinguish the systemic polyarteritis nodosa and microscopic polyangiitis, and some researchers even consider microscopic polyangiitis as a subtype of systemic polyarteritis nodosa.

Among diagnostic criteria for systemic polyarteritis nodosa, the patient's initial livedo racemosa with later ulceration and necrosis, severe pain in her legs, polyneuropathy, and moderate weight loss could be considered as positive findings. However, there were no signs of systemic vasculature involvement as she did not have hypertension/diastolic blood pressure above 90 mmHg, and her renal function tests were within normal limits. Diagnostic tests for hepatitis B and C viruses, and HIV were negative. The antinuclear antibody test (ANA) was also negative, as well as the ANCA test. An angiography in order to look for possible arterial aneurisms was not performed. As the name of the disease suggests, we should expect to see subcutaneous

nodules in both systemic and cutaneous types of polyarteritis nodosa, but they have never been observed.

Cryoglobulinaemia

Cryoglobulinaemia (2), simple or mixed types, was among our differentials. The patient reported that her condition started as two reddish pruritic maculae on her right leg after cold exposure. The cutaneous manifestation of cryoglobulinaemic vasculitis can be a sign of underlying malignancy, autoimmune disease, or hepatitis C. However, her blood smear was normal, hepatitis and HIV panels discovered no viral signs, and her ANA, rheumatoid factor (RF), and erythrocyte sedimentation rate (ESR) were within normal limits. Unfortunately, there was no possibility at this clinic to check her serum cryoglobulin and immunoglobulin (Ig) M levels. This clinical inadequacy means that important test results are missing; however, her IgG level was normal, and IgA level was decreased. From her history, the patient had never had Raynaud's phenomenon. This patient received plasmapheresis and donor plasma transfusion as part of her treatment, but these procedures did not improve her condition.

Antiphospholipid syndrome

Antiphospholipid syndrome (APS) (3) was considered in the differential diagnosis for this patient, as her medical history revealed spontaneous abortions in the first trimester. There was no history of thrombotic events. The patient skin biopsy revealed bland thrombi that might fit the APS condition. Our major concern was the possibility of catastrophic antiphospholipid syndrome (CAPS) with thrombosis and consequent infarction of multiple internal organs, but fortunately, there was no evidence of internal organ failure during several months since that condition started.

To estimate APS, the patient should be positively tested (moderate to high quantity) for at least one of several types of antiphospholipid antibodies (aPL) at least 12 weeks apart: anticardiolipin (aCL), IgG or IgM; anti-beta-2 glycoprotein I antibodies, IgG or IgM; or be positive for lupus anticoagulant (LA). Her LA, tested twice, was negative. Serological test for syphilis (VDRL) contains cardiolipin antigens and might give a false-positive result in patients with APS; however, VDRL was negative in this patient. APS is classified as associated with rheumatic or autoimmune disease (secondary APS), or as a disorder without obvious association with other diseases (primary APS). In this case, ANA and RF were negative.

Coagulation factors

Coagulation factors (e.g. protein C/S) disorder and associated purpura (4, 5). The patient's extensive ecchymotic lesions and the biopsy result of bland skin vessels thrombosis can

be suggestive for abnormality of coagulation factors. Purpura fulminans, or purpura gangrenosa, is the manifestation of widespread cutaneous vasculature thrombosis and skin hemorrhagic infarction. Purpura fulminans is a rare condition and is more specific for a paediatric population in connection with inherited protein C, S, or antithrombin III deficiency. However, in adults, these important factors in coagulation cascade regulation can be compromised by bacterial or viral infection, or by disseminated intravascular coagulation (DIC) syndrome. The patient's work-up for coagulopathies on several tests revealed normal or elevated thrombocyte count (above 250,000/mm³ on several tests). Her bleeding time, prothrombin time (PT), activated partial thromboplastin time (aPTT), and thrombin time (TT) were within normal limits. The patient had low haemoglobin (between 84 and 115 g/dl on several tests) and low erythrocyte count (between 2.8 and 3.1 million/mm³ on several tests) with anisocytosis and poikilocytosis, but there were no fragmented erythrocytes. All of these findings exclude DIC. Moreover, clinically she had no prolonged bleeding from venopuncture sites. The patient's fever and leukocytosis with elevated neutrophils and lymphopaenia were suggestive for infection or myeloproliferative pathology. However, her initial sepsis workups with chest X-ray, blood and urine cultures were negative and her blood smears were normal. Bone marrow puncture analysis was not informative because of "hyperthrombic" material. It would be prudent to measure levels of protein C/S, anti-thrombin III, and factor V Leiden, but these tests were not available at Feofaniya clinic. However, several weeks later the patient's antithrombin III and protein C levels were checked at the specialized laboratory. The level of antithrombin III was slightly elevated above the norm, and protein C level was within normal limits. In September, one of the blood smear tests revealed cells resembling blast cells. The patient also had been demonstrating anemia without observed blood losses since February. Her bone marrow biopsy was repeated, but no myeloproliferative disorder was diagnosed.

Calciphylaxis

The patient's clinical presentation of intensive skin necrosis put the rare condition calciphylaxis (6) into our diagnostic differential. However, the patient did not have end-stage renal disease (ESRD), which most often triggers this obscure condition, and her renal function tests were within normal limits. Taking into consideration her steroid therapy, calciphylaxis could be its unusual complication. Nevertheless, skin biopsy did not demonstrate calcium deposits within the cutaneous vasculature and hypodermis. Her various tests, including calcium and phosphate blood levels, and parathyroid hormone level, were non-revealing.

Another reason for skin necrosis could be heparin (or warfarin) use. This patient was on both unfractionated heparin and LMWH. Heparin necrosis can be a part of heparin-induced thrombocytopenia-HIT (7) syndrome, with decline of throm-

bocytes level more than 50% after the initiation of heparin therapy. However, the patient's level of thrombocytes was always above 250,000/mm³.

Cholesterol emboli

Cholesterol emboli (CE) or atheroembolism (8, 9) can be a culprit of extensive purpura and skin necrosis. CE should be suspected in middle-aged or older patients with underlying severe atherosclerosis. They usually occur after application of thrombolytics or anticoagulants that may create the disturbance of atherosclerotic plaques fibrin cover and plaques instability, or after invasive intra-arterial surgical or radiological procedures that might also cause migration of unstable plaques, or after traumatic events, but in rare cases they might be spontaneous. Cutaneous presentation of CE includes livedo reticularis of the lower extremities and/or "blue toe syndrome" with possible further ischaemic changes up to gangrene. Most of the patients with CE develop renal failure and present with eosinophilia. These symptoms are described as classic CE triad: livedo reticularis, eosinophilia, and acute renal failure. The patient had no sign of renal dysfunction or eosinophilia. Her skin biopsy did not reveal needle-shaped cholesterol clefts within emboli in occluded vessels.

In spite of extensive diagnostic work-up, we could not establish the final diagnosis. However, the patient's condition improved after supportive intensive therapy and skin grafting at the Kyiv Burn Center. This peculiar case of intensive cutaneous necrosis without obvious systemic involvement did not fit any classical diagnosis or disease.

References

These links provide free online access for medical professionals (after registration).

1. Callen JP. Leukocytoclastic vasculitis. Available from: <http://emedicine.medscape.com/article/333891-overview>.
2. Ainsworth C, Edgerton CC, Oglesby RJ. Cryoglobulinemia. Available from: <http://emedicine.medscape.com/article/329255-overview>.
3. Belilos E, Carsons S. Antiphospholipid syndrome. Available from: <http://emedicine.medscape.com/article/333221-overview>.
4. Kanwar VS, Sills RH. Consumption coagulopathy workup. Available from: <http://emedicine.medscape.com/article/955059-overview#a0104>.
5. Edich RF, Long WB, Gubler KD. Necrotizing fasciitis and purpura fulminans. Available from: <http://emedicine.medscape.com/article/1348047-overview>.
6. Nunley JR. Calciphylaxis. Available from: <http://emedicine.medscape.com/article/1095481-overview>.
7. Eke S, May SK. Heparin-induced thrombocytopenia. Available from: <http://emedicine.medscape.com/article/1357846-overview>.
8. McGevna LE, Hogan MT, Raugi GJ. Cutaneous manifestations of cholesterol embolism. Available from: <http://emedicine.medscape.com/article/1096593-overview>.
9. Kirkland L. Cholesterol embolism. Available from: <http://emedicine.medscape.com/article/460428-overview>.