

Mast Cells in Dermatology

Plenary Lecture by Gunnar Nilsson:

Mast Cells and Skin

Mast cells and their mediators are often associated with different diseases, most commonly allergic diseases, but also skin diseases like urticaria, angioedema, psoriasis atopic eczema or skin tumours. However, mast cells are one of our evolutionary oldest innate cells that have evolved to be equipped with an arsenal of properties that can be used to protect us (1). They have a favourable tissue distribution close to epithelial surface, blood vessels and nerves, mast cells are endowed with a great variety of receptors that the cells use to recognise and respond to both endogenous and exogenous danger signals, including pathogens (2). An interesting aspect of mast cell responses is the broad effect mast cell mediators have on tissue responses, including activation of sensory nerves, endothelial cells (causing vasodilation and extravasation), tissue remodelling, and the recruitment and activation of other cells of the immune system (3). In relation to this it is important to remember that although mast cells have the capacity to release both preformed mediators stored in the granules (e.g., histamine, heparin, proteases), secrete lipid mediators (e.g., leukotrienes and prostaglandins) and secrete de novo synthesised cytokines, chemokines, interferons and growth factors, this does not happen each time the mast cell is activated. The spectrum of released mediators is dictated by the phenotype of the mast cell and the trigger that induces mediator release. Some triggers like IgE-receptor activation leads to degranulation, lipid mediators as well as cytokine release. In contrast, CD30-activation only induces release of chemokines and some pro-inflammatory cytokines (4). Thus, the view that mast cell-activation is rather one-dimensional is not correct; instead one should look upon mast cell activation as a multi-dimensional event with lots of variation dependent on the situation. As a consequence, the function of mast cells in different types of skin inflammatory diseases is rather complex (Fig. 1) (3, 5). In many cases mast

cell actions are pro-inflammatory with the release of proteases and TNF- α , IL-8, interferon γ , etc; which are a driving force in inflammatory disorders like psoriasis and atopic eczema. In contrast, under other circumstances mast cells can exhibit an immuno-suppressive phenotype, with the release of IL-10 and TGF- β (Fig. 1). Ultraviolet radiation is one example of exposure that can induce an immuno-suppressive mast cell phenotype (6), which might play a role in epithelial skin cancers. To understand the multifaceted functions of mast cells in diverse skin inflammatory disorders is a big challenge, but nevertheless an important task to undertake. In the era of personalised medicine and the design of new drugs for skin inflammatory diseases, it is of great importance to consider the many functions of mast cells in order to achieve an effective treatment.

References

1. Metz M, Maurer M. Mast cells – key effector cells in immune responses. *Trends Immunol* 2007; 28: 234–241.
2. Abraham SN, St John AL. Mast cell-orchestrated immunity to pathogens. *Nat Rev Immunol* 2010; 10: 440–452.
3. Harvima IT, Nilsson G. 2011. Mast cells as regulators of skin inflammation and immunity. *Acta Derm Venereol* 91: 644–650.
4. Fischer M, Harvima IT, Carvalho RFS, Möller C, Naukkarinen A, Enblad G, Nilsson G. Mast cell CD30 ligand is up-regulated in cutaneous inflammation and mediates degranulation-independent chemokine secretion. *J Clin Invest* 2006; 116: 2748–2756.
5. Harvima IT, Nilsson G, Suttle MM, Naukkarinen A. 2008. Is there a role for mast cells in psoriasis? *Arch Dermatol Res* 300: 461–478.
6. Grimbaldston MA, Nakae S, Kalesnikoff J, Tsai M, Galli SJ. Mast cell-derived interleukin 10 limits skin pathology in contact dermatitis and chronic irradiation with ultraviolet B. *Nat Immunol* 2007; 8: 1095–1104.



GUNNAR NILSSON
 Clinical Immunology and Allergy,
 Department of Medicine, Karolinska
 Institutet and Karolinska University
 Hospital, Stockholm, Sweden
 E-mail: gunnar.p.nilsson@ki.se

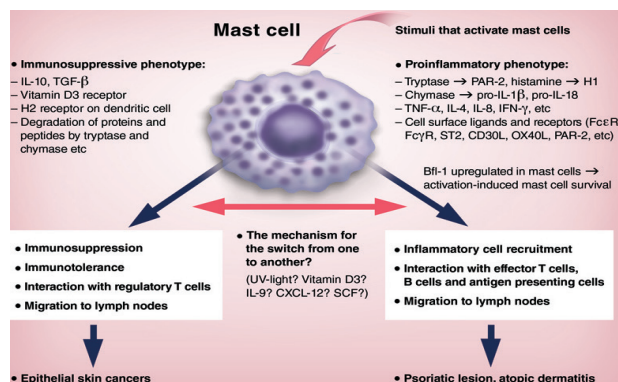


Fig. 1. Mast cells in skin inflammatory disorders. A hypothetical model where the induction of either a pro-inflammatory or immunosuppressive mast cell phenotype is depicted. Figure from (3).

Common and Uncommon Dermatoses on Dark Skin

Assessing skin diseases in dark-skinned patients is a clinical challenge, as there is variation in clinical appearance, for example lack of erythema, hyper- or hypopigmentation, and pigmentary changes can be more severe and prolonged. Some disorders appear to be unique to dark skin and both health care and cultural practices that influence the lesions differ. However, the pattern of skin diseases seen in darker-skinned patients that consult a dermatologist in developed countries resembles those of the white population as represented by acne, cutaneous infection and atopic eczema. Overall, conditions that are specific for dark skin are rather rare.

Hyperpigmentation is a common symptom but will not provide much valuable information to help diagnosing the skin condition. Almost all skin diseases in dark skin can give hyperpigmentation at some point, especially if they have a chronic or protracted course. A non-specific hyperchromia can darken the elementary lesions of the underlying dermatosis, which could mislead the physician when examining the patient. Hyperpigmentation is the main cause of consultation of dark-skinned patients but the list of causes of hyperpigmentation is countless, thus topography and additional signs should help the physician. Three conditions are of particular exception, namely acne, lichen planus and prurigo lesions in HIV patients.

Hypopigmentation on the other hand is an important sign for diagnosis and hypopigmentation also severely impairs the quality of life of the patients. Causes of permanent achromia include mainly vitiligo, post-traumatic achromia, idiopathic hypomelanosis, chronic lupus of the discoid type, and burns. Causes of mottled hypopigmentation include vitiligo, systemic scleroderma and lichenification. Lastly, frequent causes of hypopigmentation include eczema, seborrhoeic dermatitis, pityriasis versicolor, vitiligo minor, injection or local treatment of corticosteroids, achromic hamartoma, lichen striatus or verruca plana. Rare causes of hypopigmentation include mycosis fungoides, sarcoidosis and leprosy.

Lastly, skin bleaching is a widespread practice especially among sub-Saharan immigrants. Women mainly practice skin bleaching for various reasons: to obtain radiant skin, to get a better social status including jobs and marital prospects or because of social pressure such as westernised beauty ideals. Abuse of depigmentating agents such as hydroquinone, potent or ultra potent corticosteroids or other homemade concoctions leads to a high prevalence of disfiguring dyschromia. Cutaneous complications related to hydroquinone use are periorbital pigmentation, exogenous ochronosis, vitiligo mottled-like hypopigmentation, lupus-lichen lesions and even maybe skin cancer. The abuse of corticosteroids leads to cutaneous infections such as tinea, acne, stretch marks, skin atrophy and

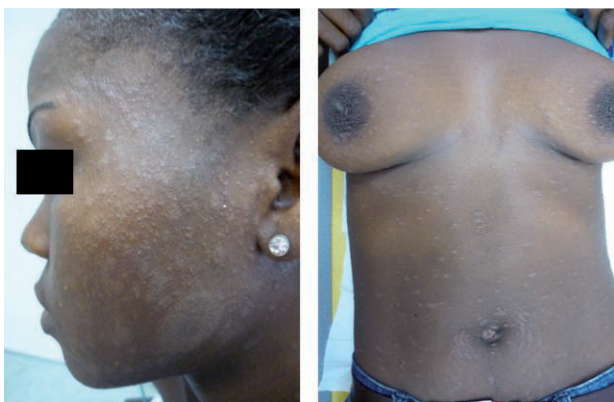

Fig. 1. Pityriasis rosea in a young girl. The rash appears grayish but the topography and the aspects are still typical of pityriasis rosea. Note the medalion in the left cheek that helped to make the diagnosis.

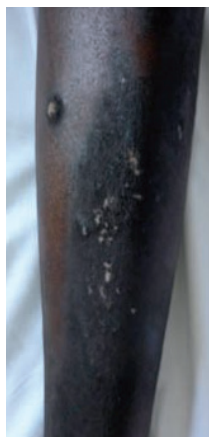

Fig. 2. Prurigo nodularis in an HIV patients. Typical annular pigmented itchy lesions with central depigmentation.

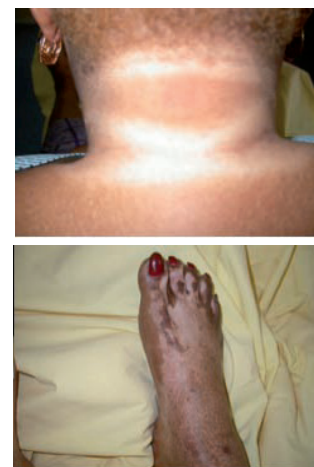

Fig. 3. Heterogenous depigmentation induced by skin bleaching agents.

systemic complications. As users tend to hide the use of such agents to the physician it is important to treat any underlying skin dermatoses, disrupt bleaching agents, avoid any judgemental approach and educate about the risks of such practice.



NICOLAS KLUGER
 Skin and Allergy Hospital, Helsinki
 University
 Central Hospital, Helsinki, Finland
 E-mail: nicolaskluger@yahoo.fr

Health Economics and Dermatology

In recent years there have been major advances in dermatology. We have new biological drugs for treatment of psoriasis and other inflammatory conditions. However, they are very expensive, but we have been able to reduce the number of beds due to dermatological research. Sweden is a very good country for health economic studies as the budgetary system is simple and includes all costs except sick-leave costs. Hence, rent, salaries for staff, electricity, drugs for in- and out-patients are included in the budget. Lindelöf et al. has demonstrated that melanomas are best and cheapest treated by a dermatologist without previous referral from a general practitioner (GP). However, still in many places people have to seek a GP first. When calculating cost, the whole process should be included, not only different procedures. Priorities in health care must be made to afford treatment of the most severe diseases. This