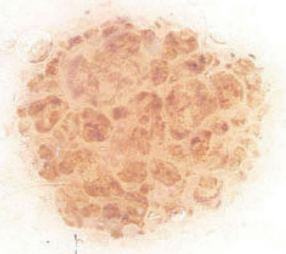
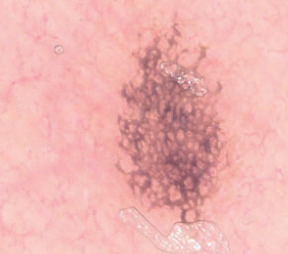
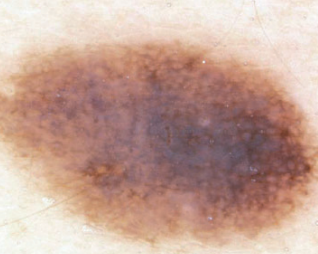


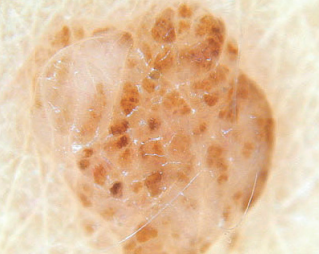


## How is Your Skills to Judge a Diagnosis From a Photo?

Test yourself regarding the diagnoses in the photos below (generously supported by Professor Giuseppe Argenziano, Naples, Italy). Below is only 6 photos and it is just possible to make a choice of the diagnosis. At the website <http://www.medicaljournals.se/forum> you can log in and find these 6 and 24 more photos – all with options for diagnosis but also options for whether it is “atypical pigment network”, “blue-white structure” and “asymmetry”, or not. ENJOY!

<p>1</p> 	<input type="checkbox"/> Melanoma <input type="checkbox"/> Benign melanocytic lesion <input type="checkbox"/> Lentigo simplex <input type="checkbox"/> Basal cell carcinoma <input type="checkbox"/> Seborrhoeic keratosis <input type="checkbox"/> Vascular lesion	<p>2</p> 	<input type="checkbox"/> Melanoma <input type="checkbox"/> Benign melanocytic lesion <input type="checkbox"/> Lentigo simplex <input type="checkbox"/> Basal cell carcinoma <input type="checkbox"/> Seborrhoeic keratosis <input type="checkbox"/> Vascular lesion
<p>3</p> 	<input type="checkbox"/> Melanoma <input type="checkbox"/> Benign melanocytic lesion <input type="checkbox"/> Lentigo simplex <input type="checkbox"/> Basal cell carcinoma <input type="checkbox"/> Seborrhoeic keratosis <input type="checkbox"/> Vascular lesion	<p>4</p> 	<input type="checkbox"/> Melanoma <input type="checkbox"/> Benign melanocytic lesion <input type="checkbox"/> Lentigo simplex <input type="checkbox"/> Basal cell carcinoma <input type="checkbox"/> Seborrhoeic keratosis <input type="checkbox"/> Vascular lesion
<p>5</p> 	<input type="checkbox"/> Melanoma <input type="checkbox"/> Benign melanocytic lesion <input type="checkbox"/> Lentigo simplex <input type="checkbox"/> Basal cell carcinoma <input type="checkbox"/> Seborrhoeic keratosis <input type="checkbox"/> Vascular lesion	<p>6</p> 	<input type="checkbox"/> Melanoma <input type="checkbox"/> Benign melanocytic lesion <input type="checkbox"/> Lentigo simplex <input type="checkbox"/> Basal cell carcinoma <input type="checkbox"/> Seborrhoeic keratosis <input type="checkbox"/> Vascular lesion

1: Benign melanocytic lesion (dermal naevus);  
 2: Lentigo;  
 3: Melanoma;  
 4: Benign melanocytic lesion (Naevus, junctional or compound);  
 5: Basal cell carcinoma;  
 6: Benign melanocytic lesion (dermal naevus).