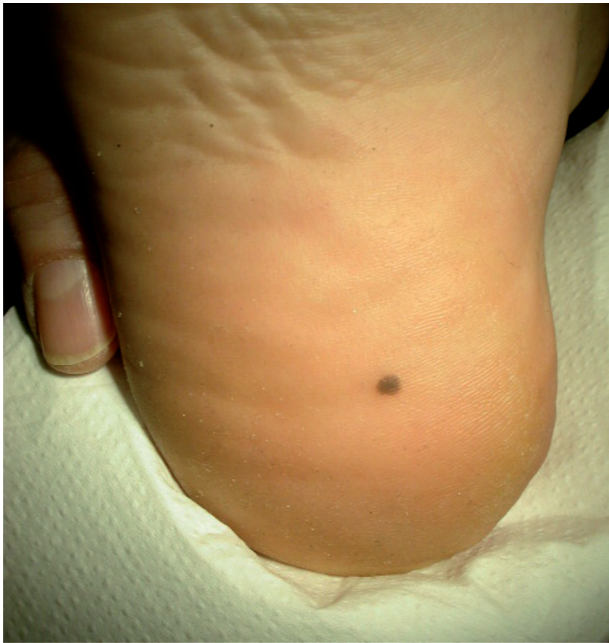

## How is Your Skill to Diagnose a Skin Lesion by Dermoscopy?

KAARE WEISMANN, PROFESSOR, DR.MED.

E-mail: [weisech@dadlnet.dk](mailto:weisech@dadlnet.dk)

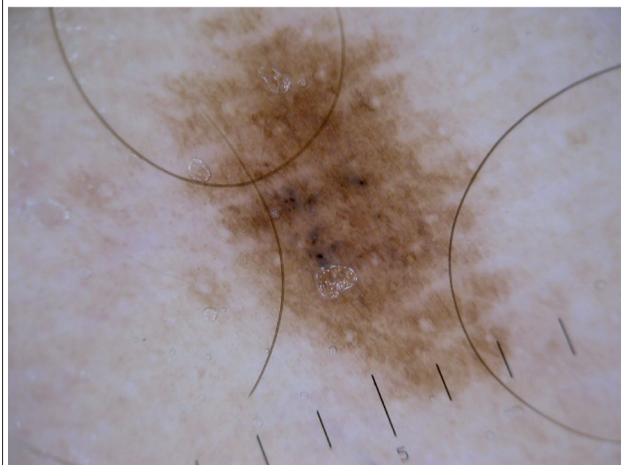
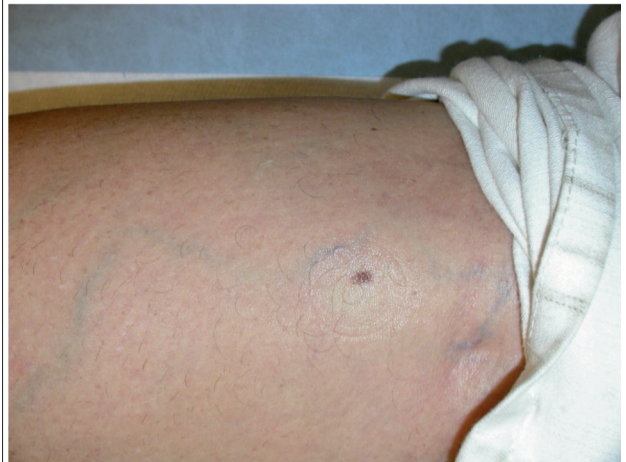
Case 5: A young woman with an acquired brownish lesion on her right heel



**What is your diagnosis?**

1. Melanocytic naevus
2. Malignant melanoma
3. Cutaneous bleeding

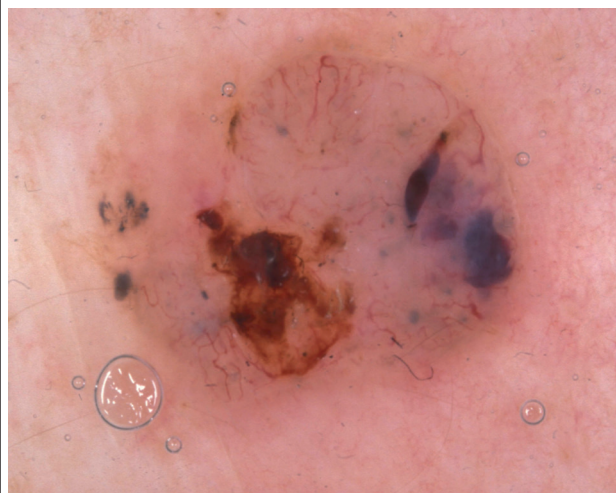
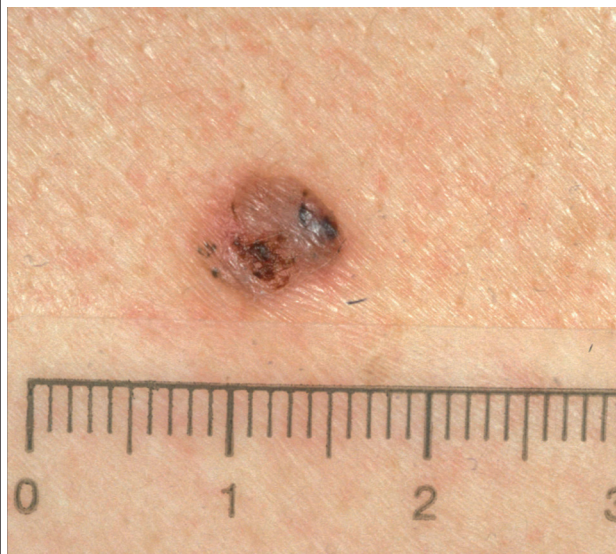Case 6: A woman with a naevus on her right thigh



**What is your diagnosis?**

1. Malignant melanoma
2. Seborrhoeic keratosis
3. Melanocytic naevus

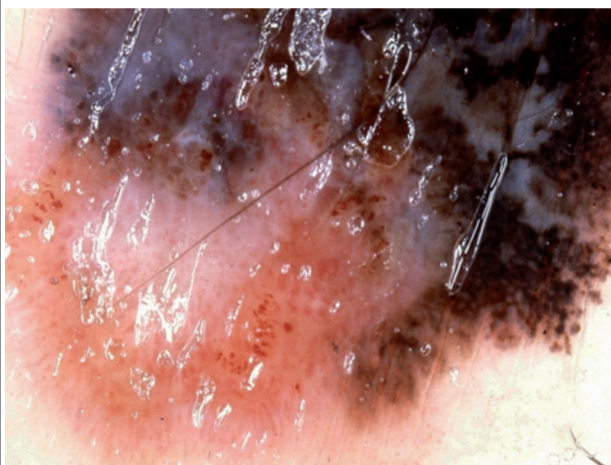
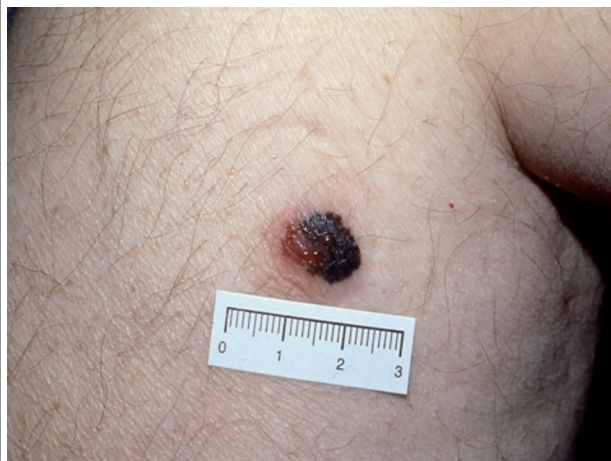Case 7: An elderly man with a lesion on his right shoulder



**What is your diagnosis?**

1. Malignant melanoma
2. Seborrheic keratosis
3. Basal cell carcinoma

Case 8: A man with a bleeding nodule on his thorax



**What is your diagnosis?**

1. Seborrheic keratosis
2. Basal cell carcinoma
3. Malignant melanoma

*Find the answers on bottom of page 30.*