

Rosacea: Time for a New Approach

CARSTEN SAUER MIKKELSEN¹, PETER BJERRING², MARGARETA LIRVALL³, MARGARETA SVENSSON⁴, HELENE RINGE HOLMGREN⁵, ALEXANDER SALAVA⁶ AND THEIS HULDT-NYSTRØM⁷

¹Private Practice in Dermato-Venereology, Brønderslev, ²Dermato-Venereology, Mølholm Private Hospital, Mølholm, Denmark, ³Dermato-Venereology and Pathology, Lund, ⁴Dermato-Venereology, Private Practice, Stockholm, Sweden, ⁵Dermato-Venereology, Private Practice, Frederikshavn, Denmark, ⁶Dermatology and Allergology, Helsinki University Hospital, Helsinki, Finland and, ⁷Dermato-Venereology, Private Practice, Namsos, Norway. Carsten Sauer Mikkelsen, Private Practice in Dermato-Venereology, Brønderslev, Denmark. E-mail: c.s.mikkelsen@hotmail

Rosacea, also known as “the curse of the Celts”, probably because of the predominance of Fitzpatrick skin type I+II in Celtic people, is a skin disorder with multiple signs and symptoms. In individuals, these symptoms may be multiple, or a single symptom may predominate (1), and the symptoms may vary over time. For clinicians the definition of rosacea is not very stringent and depends on both clinical morphological findings and specific reactions to stimuli.

Rosacea is a chronic skin condition with facial redness, small and superficial dilated blood vessels on the facial skin, papules, pustules, and swelling (2). It typically begins as redness on the central face, across the cheeks, nose or forehead, but can also less commonly affect the neck, chest, ears and scalp (3). The eyes are often involved, and thickening of the skin, with enlargement (phymas), especially of the nose, can occur (4, 5). Because rosacea is so visible, it can interfere substantially with a person's quality of life.

Rosacea is typically seen in the Scandinavian skin type, who have fair skin, blue eyes and blond hair. Epidemiological studies show that the prevalence is as high as 10% in the Swedish population (6), approximately 5% in the USA and 2–3% among the French and Germans (7, 8). A familial background is present in 15–40% of cases. In ancestors of rosacea patients the condition is found in approximately 45% of cases, compared with 13% of controls. Women are affected 2–3 times more frequently than men (9).

Approximately 80% of cases of rosacea are diagnosed after the age of 30 years. Women typically debut earlier (35 years of age) than men, with the highest prevalence in the age range 61–65 years. Males debut at approximately 50 years of age, with the highest prevalence in the age range 76–80 years. There are no epidemiological studies of rosacea in childhood. Clinically, rosacea is not often seen in children, although it may be underdiagnosed.

Rosacea is not a disease specific to people of northern Europe; it may have a wider distribution, consistent with the migra-

tion of people and mixture of genes between races. Rosacea in persons with Fitzpatrick skin type IV–V is less common, but is probably underdiagnosed, as shown in a study from India (10). Unfortunately, rosacea is often misdiagnosed (11).

Pre-rosacea (early-onset rosacea)

The pre-rosacea stage is characterized by frequent occurrences of facial flushing or blushing, which may come and go, without inflammation or facial swelling. For many people who identify the problem and take corrective measures, this is as far as their rosacea progresses. The facial flushing of pre-rosacea is often triggered by the same complex set of triggers that influence the later stages of rosacea. Effective treatment at this early stage can help control and manage the severity of this progressive condition (12).

Rosacea subtypes

The 4 classical subtypes of rosacea are: erythematotelangiectatic rosacea (ETR), papulopustular rosacea (PPR), phymatous rosacea, and ocular rosacea, as described below.

Erythematotelangiectatic rosacea (ETR)

- The most common subtype of rosacea.
- Flushing, persistent redness of the central face.
- Often occurs before or at the same time as the bumps and pimples of papulopustular rosacea.
- Telangiectasias with small visible blood vessels may be present.
- Patients tend to have sensitive skin with stings or burns at times.

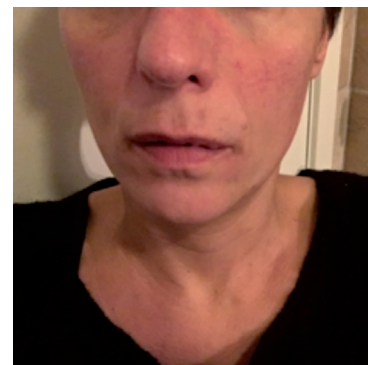


Fig. 1. Erythematotelangiectatic rosacea (ETR). (Photo: Carsten Sauer Mikkelsen).

Papulopustular rosacea (PPR)

- Papules/pustules come and go, combined with transient or persistent facial redness, primarily on the central face.
- Small visible blood vessels (telangiectasias).
- Raised, scaly red patches known as plaques.
- Burning and stinging.

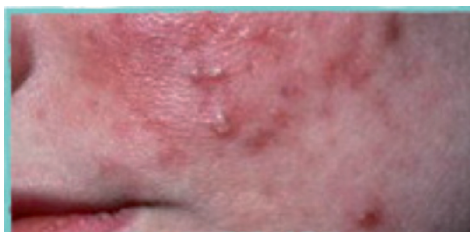

Fig. 2. Papulopustular rosacea (Photo: Galderma®).

Phymatous rosacea

- Nose (rhinophyma)
- Chin (gnatophyma)
- Forehead (metophyma)
- Ears (otophyma)
- Eyelids (blepharophyma)
- Upper lip region (philtrophyma)

Rhinophyma is the most frequent location and shows marked skin thickenings and irregular surface nodules, especially of the nose. Telangiectasia can also be present. Fibrosis is present and increased volume of sebaceous glands is observed. The 4 different histopathological types of rhinophyma (13) are:

- Fibrous
- Glandular
- Fibroangiomaticous
- Actinic

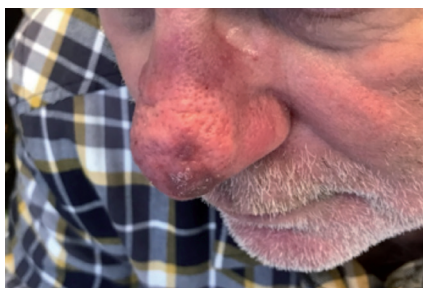

Fig. 3. Phymatous rosacea (rhinophyma) (Photo: Carsten Sauer Mikkelsen).

Ocular rosacea

- Minor irritation, foreign body sensation, dryness, and blurry vision due to severe ocular surface disruption and inflammatory keratitis.

- Patients frequently describe a gritty feeling, and they commonly experience blepharitis and conjunctivitis. Clinicians should ask about problems related to air conditioning and the sensation of “hairs” stuck in the eyes.
- Other ocular findings include lid margin and conjunctival telangiectasias, eyelid thickening, eyelid crusts and scales, chalazion and hordeolum, punctate epithelial erosions, corneal infiltrates, corneal ulcers, corneal scars, and corneal vascularization.
- More than 50% of patients with ocular rosacea show a reduction in Schirmer’s test (14).

The definition of ocular rosacea is even less stringent than that of cutaneous rosacea. The diagnosis depends on inflammatory findings due to disturbance of the function of the Meibomian glands and telangiectasias. There is no reliable diagnostic test for ocular rosacea. Since many ophthalmic and dermatological diseases can present with similar inflammatory reactions to that of ocular rosacea the diagnosis relies on careful investigation and follow-up, and the collaboration of ophthalmologists and dermatologists. The lack of stringent diagnostic criteria for ocular rosacea probably also reflects the varying prevalence of this condition, with 6–72% of rosacea patients affected (15, 16).

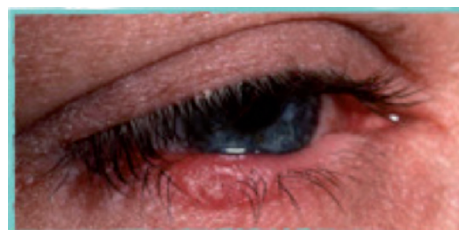

Fig. 4. Ocular rosacea (Photo: Galderma®).

Time for a new approach?

The classification and subtyping of rosacea has, until now, been based on a subset of symptoms and clinical findings. More than 50% of rosacea patients have a combination of different subtypes, which shows that subtyping is inadequate and has limitations both for research and selection of treatment.

The use of a phenotype approach will allow a more accurate and stringent classification of rosacea. New diagnostic tools emerge, and transcriptome analysis has revealed a possible distinct gene profile for each subtype of rosacea. A change in paradigm towards a phenotype classification, which can also easily be combined with newer diagnostic methods, such as transcriptome analysis, is an interesting possibility. The use of more objective criteria will allow those aspects that are most troubling to patients to be better targeted and allow the best treatment to be selected (17, 18).

Pathology

Cribier (19) recently performed a large clinicopathological study and, the data from this study, together with other published data, was used to identify the main histological features of rosacea. Histological markers were shown to be useful in the diagnosis of rosacea.

Extensive telangiectasias are seen in the superficial and middle dermis, with enlarged lumens and unusual shapes (tortuous or geometric contours) and a larger number and size of the telangiectatic vessels. There is a relatively low number of endothelial cells, with a perivascular infiltrate that surrounds the dilated vessels. The infiltrate is composed of mononuclear cells (lymphocytes, histiocytes, and plasma cells). Oedema, visible as a lucent band in superficial papillary and reticular dermis, occurs. An increased number of dermal mast cells is seen.

Potential pathways of pathogenesis (20)

- Innate immunity
- Adaptive immunity
- Neurocutaneous mechanisms
- Vasculopathy

Innate and adaptive immunity (inflammation). Both the innate and adaptive immune system are involved in the development of rosacea at a very early stage (21). Initially, T cells and macrophages infiltrate the skin, releasing factors leading to prolonged vasodilation, as seen as erythema. These cells are also responsible for the recruitment of neutrophils and other cells, resulting in the formation of pustules. The critical cells involved in the inflammatory response in rosacea are Th1 and Th17 cells, mast cells, macrophages, antibody-presenting B-cells, and neutrophils. Increased serine protease activity and cathelicidin promotes skin inflammation in rosacea. This knowledge of inflammation is, in our opinion, important in order to prescribe a correct stepwise treatment-algorithm with initial treatment with anti-inflammatory drugs (22).

Neurocutaneous mechanism. Increased skin sensitivity to noxious heat stimuli is observed in rosacea-affected skin, more prominently in patients with PPR than in those with ETR. A lower heat pain threshold is found in affected vs non-affected areas (based on heating the skin with a probe from 32°C to 50°C); enhanced perception of noxious heat stimulus; subjective burning perception is increased (based on Visual Analogue Scale) in patients with rosacea vs control subjects; elevated skin blood flow occurs in PPR-affected skin vs non-affected skin (based on Laser Doppler imaging). This component is not significant for ETR-affected skin (23).

Vasculopathy. Facial hypersensitivity is based on vascular changes due to: stasis, increased blood flow, inflammation, lower pain threshold (as described above), higher skin temperature and hypersensitivity (non-allergic) (24).

Neurogenic rosacea is a distinct clinical subtype requiring a modified approach to treatment with drugs such as gabapentin, pregabalin and duloxetine (25).

Demodex and rosacea

Two types of *Demodex* mites are present in rosacea: *Demodex folliculorum* and *Demodex brevis*. *Demodex brevis* is located deepest. The mites are 0.1–0.4 mm long and have a life-cycle of 14–18 days. *Demodex* are found in the hair follicles, sebaceous glands and eyelid glands. Corneal manifestations of ocular *Demodex* infestation, causing severe corneal changes with vascularization, infiltration and scarring, has also been found (26). *Demodex* specifically causes papulopustular rosacea. In immunocompromised patients *Demodex* may be located elsewhere. A higher prevalence of *Demodex folliculorum* and a higher mean mite density was found in rosacea patients, with the greatest density in the involved areas (27). These findings are confirmed by reflectance confocal microscopy (28) and biopsies. The cut-off value of the *Demodex* density associated with rosacea is 15 mites/cm².

Demodex has been shown to induce neutrophilic and granulomatous inflammation. It causes upregulation of toll-like receptor 2 (TLR2) – proKLK5-proIL-37; alarmin activity; macrophage recruitment; activation of interleukin 8 (IL-8) (neutrophil recruitment), cyclooxygenase-2 (COX-2) (pain); and tumour necrosis factor alpha (TNF-α) (inflammation) (27).

Bacillus oleronius is a Gram-negative bacteria isolated from *Demodex*. The mite-related bacterial antigen is, as expected, present more frequently in patients with rosacea, and the bacterial proteins induce neutrophil activation (29, 30). A correlation has been shown between ocular *Demodex* infestation and serum immunoreactivity to *Bacillus oleronius* proteins (31). The microbiota of *Demodex* mites from rosacea is different from that of controls (32). Some bacterial species are found only in *Demodex* from patients with rosacea (Proteobacteria, Synergistetes, Firmicutes, Cyanobacteria, Bacteroidetes, Actinobacteria) but their role in the pathogenesis of this condition remains unknown.

Psychosocial impact on patients with rosacea

In surveys performed by the National Rosacea Society, more than 90% of patients with rosacea reported that their condition had reduced their self-confidence and self-esteem, 41%

reported that it had caused them to avoid public contact or cancel social engagements. Among rosacea patients with severe symptoms 88% reported that the disorder had adversely affected their professional interactions, and 51% reported that they had missed work because of their condition. Rosacea can affect quality of life, and several controlled studies of patients with rosacea show that using the Dermatology Life Quality Index (DLQI) and Rosacea Quality of Life Index (RosaQoL) the condition has a small-to-moderate negative effect on health-related quality of life (33, 34).

There is evidence that treatment of rosacea with metronidazole, ivermectin, isotretinoin, low-dose doxycycline and laser improves quality of life (35–39).

Co-morbidity and rosacea

No recommendations have yet been made in national, Nordic or European Guidelines on screening for these possible correlations (Table I).

In patients with concomitant rosacea and gastrointestinal disorders, we suggest that the new data is taken into consideration and follow-up is performed for inflammatory bowel diseases.

The following 3 HLA alleles (major histocompatibility complex (MHC) class II) are significantly associated with rosacea:

- HLA-DRB1
- HLA-DQB1
- HLA0DQA1 (20)

These 3 alleles are also associated with type I diabetes, retinopathy (vascular proliferation), and coeliac disease.

Table I. *Co-morbidity and rosacea*

Possible co-morbidities of rosacea
Depression (40)
Migraine (41, 42)
Brain tumour (glioma) (43)
Parkinson's disease (44)
Dementia (45)
Autoimmunity (46)
Gastro-intestinal disorders (47)
Cardiovascular diseases (48)
Hypertension (49)
Diabetes mellitus type 1 (48)
Metabolic diseases (49)
Coeliac disease (48)
Multiple sclerosis (48)
Rheumatoid arthritis (46)
Schizophrenia (46)

Prophylaxis/trigger avoidance (50)

- *Ultraviolet (UV) light* (see below).
- *Certain foods and beverages*, such as hot drinks (e.g. soup, hot chocolate), citrus fruits, and caffeinated beverages (tea or coffee).
- *Spicy seasonings* (e.g. white or black pepper, paprika, red pepper and cayenne).
- *Alcohol*, especially red wine.
- *Stress*: emotional upset is one of the most common triggers associated with rosacea flare-ups. Such patients should seek ways to manage stress.
- *Strenuous exercise*: high-intensity workouts overheat the body and trigger flushing. Avoiding vigorous exercise or dividing it into shorter sessions may help. It is recommended to find ways to keep cool, such as exercising outdoors during cooler weather, and indoors in an air-conditioned space during hot weather.
- *Extreme temperatures*: extremely hot or cold weather conditions, very dry or humid, wind, and indoor heat exposure can act as triggers. Patients should stay cool in hot weather, cover up the skin and moisturize when it is cold outdoors, and avoid hot baths, saunas or other environmental factors that raise their body temperature
- *Medication*: certain medications can cause flushing and flare-ups. Drugs causing vasodilation (e.g. angiotensin-converting enzyme inhibitors (*ACE inhibitors*) and some cholesterol-lowering drugs (e.g. niacin)) may play a role. Approximately 90% of people treated for colorectal, bronchial or breast cancer with chemotherapy with epidermal growth factor (EGF)-receptor antagonist (erlotinib, cetuximab, gefitinib, afatinib) develop skin side-effects, including papulopustular rosacea-like exanthema (51).

Treatments for rosacea

The Cochrane database produces high-quality, relevant systematic reviews that enable professionals and patients to make evidence-based health decisions. The Grading of Recommendations, Assessment, Development and Evaluation (GRADE) scale enables judgements to be made about the quality of evidence and strength of recommendations (50).

In the current paper we have used the GRADE scale as much as possible regarding the following aspects of rosacea and treatment:

- Redness
- Anti-parasitic
- Anti-inflammatory
- Ocular rosacea
- Phyma

Treatment for redness

Differential approach to redness

Redness is frequent and has been universally confirmed as the most bothersome feature of rosacea (52). It is important to classify and treat the underlying erythema correctly to ensure the best possible control of redness.

Current definition-based symptoms and signs (5, 53–55)

1. Primary features associated with facial redness:

- *Transient flushing*: of variable intensity and frequency
- *Inflammatory lesions*: lesional or perilesional redness
- *Persistent (non-transient) macular background erythema*: independent of lesions. Inflammation from papules and pustules or dry, inflamed skin may obscure the level of non-transient erythema.
- *Teleangiectasia(s)*

2. Secondary features associated with facial redness:

- Burning, stinging, oedema. In rosacea the central facial erythema is seen on the: inner cheeks, nose, chin, mid-forehead, and is confluent or diffuse.
- Background erythema is caused by dilated deep located vessels.
- Telangiectasia is caused by dilated superficial vessels.

3. Neurovascular dysregulation can modulate vasodilation in rosacea:

- Adrenergic receptors are G-protein coupled receptors.
- Alpha 1-adrenergic receptor: larger arteries (diameter >200 µm).
- Alpha 2-adrenergic receptor: smaller arteries (diameter <200 µm). Brimonidine is a highly selective 2-adrenergic receptor agonist and causes vasoconstriction of facial blood vessels, which are abnormal in rosacea. It is a symptomatic treatment and erythema returns as the effect of the drug wears off after approximately 12 h. There is high-quality GRADE evidence for all outcomes, supporting that brimonidine is twice as effective as vehicle for erythema. In rosacea it is the first and only proven efficacious treatment for persistent erythema (51). Brimonidine adverse events are seen in approximately 11% of cases. Most common are worsening of erythema, flushing and worsening of rosacea (56).

Treatment of telangiectasia (57–62):

Telangiectatic rosacea is amenable to laser and intense pulsed light (IPL) management. Nine randomized controlled trials (RCT) have shown that pulsed dye laser and/or light-based therapies appear to be effective, but limited data are provided and only small sample sizes are enrolled. IPL is probably best for centropacial erythema.

Very early laser treatment on inflamed skin may lead to stinging and burning. If the inflammation is under control with a systemic drug in combination with a topical treatment, subsequent laser or IPL therapy, these side-effects occur more rarely. After visible telangiectasia are treated with laser or IPL only the background erythema due to inflammation remains.

Treatment suggestions for erythema

- Marked background erythema and minimal telangiectasia: brimonidine
- Marked background and marked telangiectasia: brimonidine and laser/IPL
- Minimal background erythema and severe telangiectasia: laser/IPL only

Other treatment options for redness

Antihistamines. Mast cells are key mediators of cathelicidin-initiated skin inflammation in rosacea (22). LL-37 is also mast cell-associated, especially in patients with rosacea (22). Despite poor GRADE evidence, we regard antihistamine treatment as useful in the treatment of flushing.

β-blockers. Traditional β-blockers (propranolol, nadolol) have been shown to be effective against erythema in rosacea patients in small case series. A small case series of normotensive rosacea patients treated with carvedilol up to 25 mg/day was shown to be effective in the treatment of facial erythema, cheek temperature, as well as patient assessment of symptom severity (63). Despite effective suppression of flushing, limitations in the use of this drug are due to potential adverse effects, such as hypotension and bradycardia.

Botulinum toxin. A Chinese group (64) showed that botulinum toxin could decrease the intensity and duration of erythema and rosacea flushing.

Anti-parasitic treatment

There is clinical and theoretical evidence for a dual mode of action of ivermectin by anti-parasitic (65–67) and anti-inflammatory activity (68–70). The anti-parasitic effect occurs through reducing the numbers of *Demodex*. However, 3–4 weeks after treatment with ivermectin the *Demodex* will spontaneously return. Topical ivermectin should be continued as a maintenance treatment 2 times/week after clearance. Neither doxycycline nor topical metronidazole 7.5–10 mg/g have a significant anti-parasitic effect. The degree of *Demodex* infestation does not decrease in parallel with improvement under tetracycline treatment.

Anti-inflammatory effects occur through reducing the cellular and humoral immune response by neutrophil phagocytosis,

oxidant production by phagocytes, chemotaxis and pro-inflammatory cytokines (TNF- α , IL-1, IL-10).

Anti-inflammatory treatment

Topicals for papulopustular rosacea

High-quality evidence supports that ivermectin is effective and safe for papulopustular rosacea in 2 trials with 1,371 participants (39). There is high-quality evidence that azelaic acid is effective and safe for papulopustular rosacea in 5 trials. There is moderate-quality evidence that metronidazole is effective and safe for papulopustular rosacea in 9 trials.

Systemic treatment for papulopustular rosacea

High-quality evidence supports that ivermectin was more effective than metronidazole in papulopustular rosacea in 962 participants (71). Modified-release doxycycline 40 mg might be as effective as doxycycline 100 mg (quality of GRADE evidence: low), with a quarter of the side effects.

Azithromycin might be as effective as doxycycline 100 mg (quality of GRADE-evidence: very low). Isotretinoin 0.3 mg/kg vs. doxycycline 100 mg (after 2 weeks, tapered to 50 mg/day). High-quality GRADE- evidence for all outcomes supporting that isotretinoin was more effective than doxycycline in papulopustular rosacea in one trial with 262 participants (72).

Ocular rosacea treatment

Mild (mild blepharitis with lid margin telangiectasia)

Topical: Lid hygiene. Topical antibiotic. Artificial tears recommended.

Moderate (blepharoconjunctivitis/blepharokeratoconjunctivitis)

Topical: Lid hygiene + topical cyclosporine

Systemic: Doxycycline 40 mg \times 1 (or lymecycline 300 mg \times 2 or tetracycline 500 mg \times 2 tapering off to lowest effective dose on effect). Artificial tears recommended.

Severe (sclerokeratitis)

Topical: Lid hygiene + topical corticosteroids or topical cyclosporine.

Systemic: Doxycycline 40 mg \times 1 (or use lymecycline 300 mg \times 2 or tetracycline 500 mg \times 2 tapering off to lowest effective dose on effect. Artificial tears recommended.

In several small studies topical cyclosporine 0.05% has shown a better effect than systemic doxycycline on ocular rosacea symptom scores, Schirmer's test and tear production (73, 74). In several studies topical cyclosporine has shown fewer side-effects than oral doxycycline. Low-dose doxycycline has

a slower mode of action than the full dose in ocular rosacea (75). Eyelid hygiene (removal of crusts, warm compresses) is important in treatment of chronic blepharitis and meibomian gland dysfunction (76).

In patients with dry eyes due to inflammatory diseases an increased dietary intake of omega-3 fatty acids with lower dietary ratio of omega-6 to omega-3 fatty acids, as well as use of supplements containing linoleic and gamma-linoleic acid, decreases the risk of complications associated with dry eye symptoms (77, 78). Whether this data can be referred to ocular rosacea is not known.

More RCTs are needed for recommendation on treatment of ocular rosacea, since the GRADE evidence is low.

Phyma treatment (79)

Treatment options from Canadian guidelines:

- C1. Topical retinoids
- C2. Oral tetracycline or doxycycline
- C3. Ablative laser surgery, using CO₂ or Er:YAG modalities, or surgery, including electrosurgery and cryosurgery
- C4. Oral isotretinoin

C1. Topical retinoids

(Weak recommendation: very low confidence in effect estimate)

Topical retinoids may help minimizing progression of rosacea-associated phyma. Confidence in the effect is estimated as very low because efficacy has not been evaluated by RCTs. However, given the lack of non-invasive treatment options for phymatous features of rosacea, topical retinoids represent a safe option for those with mild-to-moderate involvement that is less costly than procedural treatments.

C2. Oral tetracycline or doxycycline

(Weak recommendation: very low confidence in effect estimate)

Oral tetracycline and doxycycline may be useful for mild phymatous rosacea, particularly if there is an inflammatory component. However, there have been no RCTs for this indication.

C3. Ablative laser surgery, using CO₂ or Er:YAG modalities, or surgery, including electrosurgery and cryosurgery

(Weak recommendation: very low confidence in effect estimate and variability in patient values and preferences)

Ablative laser resurfacing, using CO₂ or Er:YAG modalities, and surgery, including electrosurgery, may significantly improve phymatous features of rosacea. The effect is esti-

mated as very low because the efficacy of these procedural treatments for phymatous features has not been evaluated by RCTs; however, their use was supported by strong recommendations based on clinical experience.

The efficacy of these interventions depends on the training and expertise of the treating physician. Treatment may be costly if not covered by provincial health plans, and access may be limited. Swelling and redness may persist for several weeks or longer. These risks are balanced against the potential for excellent outcomes. This option, if available, should be offered to all patients, acknowledging that the patients' preferences, values and treatment cost will influence their decision.

C4. Oral isotretinoin

(Weak recommendation: very low confidence in effect estimate, but variability in patient values and preferences regarding potential adverse events)

Oral isotretinoin may be effective at reducing early phymatous features of rosacea. For phymatous features, we rated our confidence in the effect estimated as very low because the outcome has not been validated; however, we felt that it may have some benefit in patients with early phymatous changes.

Treatment for bothersome symptoms

- Acetylsalicylic acid (ASA) 500 mg 1–3 times a day
- Non-steroidal anti-inflammatory drugs (NSAIDs) for tingling and burning. Ibuprofen 400–600 mg 1–3 times a day
- Topical corticosteroid. Only short courses (5–7 days) of mild topical corticosteroids (group I) in emollient or lotion form
- Cooling devices, such as cold-packs and ventilators
- Only low GRADE evidence based information on the above treatments

Photoprotection

UV light is a trigger for rosacea through stimulation of the innate immune system. Factors that decrease ozone levels in the atmosphere will increase UV exposure levels and thereby increase the incidence of rosacea. Researchers from Boston University found that exposure to UV radiation led to the production of vascular endothelial growth factor (VEGF), which is linked to the development of visible telangiectasia. The activity of VEGF might be induced by TNF- α .

Melanin in the skin of Fitzpatrick skin types IV+IV makes it difficult for UV radiation to reach the lower layers of the skin. As a result, in darker-skinned individuals, VEGF would

tend to be induced only in the upper skin layers, and hence not affect the blood vessels. We suggest at least sun-protection factor (SPF)30+ and minimizing the highest UV index sun exposure from 11.00 h to 14.00 h. Rosacea patients may be susceptible to irritation caused by sunscreen ingredients. Appropriate protective ingredients (dimethicone, cyclomethicone) in the vehicle can often minimize irritation. Physical, inorganic sun-blocks (titanium oxide, zinc oxide) are usually well tolerated. Newer products utilizing micro-fine particles are under evaluation (55).

Cosmetics

In a survey conducted by the US National Rosacea Society including 1,066 patients, many cited the following ingredients as triggers for irritation: alcohol (66%), witch hazel (30%), fragrance (30%), menthol (21%), peppermint (14%) and eucalyptus oil (13%). Most respondents said they avoided astringents, exfoliating agents and other types of products that may be too harsh for sensitive skin. Waterproof and opaque make-up is usually preferred. Make-up containing ingredients that provide sun protection and decrease inflammation is recommended. Make-up with lower allergenic potential should be used. Mineral make-up is well tolerated. Formulations containing silica and talc may be used with the aim of giving a matte finish to the complexion.

Rosacea patients should consider reducing the number of products they use on their skin by choosing fewer products with multiple functions.

Application of a moisturizer immediately before topical treatments has been shown to reduce stinging, burning, tingling, and itching associated with rosacea symptoms. Whether this procedure dilutes the active ingredients in topical medications is unknown.

Patient education and empowerment

Rosacea patients need education to understand the complexity of their skin disease and to ensure that they follow treatment correctly. Patient empowerment is a process to help gain control, which includes taking the initiative, solving problems and making decisions (80). With this new information about the pathogenesis of rosacea and treatment options we will see a shift from the biomedical model to a more patient-oriented consultation and counselling.

Dermatologists and their staff should follow a holistic approach to ensure that their patients are empowered with sufficient knowledge, understanding, skills and confidence to use the new information on rosacea and to take an active

	Treatment options	Inflammatory papules/pustules			Persistent erythema*	Phyma	
		Mild	Moderate	Severe*		Clinically inflamed	Clinically non-inflamed
Topical agents	Azelaic acid	•	•	(•)			
	Brimonidine				•		
	Ivermectin	•	•	•			
	Metronidazole	•	•	(•)			
Oral agents	Doxycycline		•	•		•	
	Isotretinoin		(•)	•		•	
	All relevant systemic antibiotics		(•)	(•)			
Procedures	Intense pulsed light				•		
	Laser						(•)
	Physical modalities						•
Comments	If teleangiectasia prevail after treatment of erythema → laser/IPL treatment						
Combine treatment with eventual skin care and sun protection							

Get control of inflammation (anti-inflammatory topicals)

Remove of visual blood vessels (laser/IPL)

Minimize background erythema (brimonidine)

Fig. 5. Suggested new treatment algorithm inspired by Canadian Guidelines (81). (•): not evidence-based, *: transient erythema might be considered pre-rosacea, +: combine local and oral agents.

role in their own wellbeing. Health literacy is a significant concern in the treatment of rosacea as well as in many other skin conditions.

Conflicts of interest. All the writers received grants from Galderma. Galderma has not been involved in the design of this study or influenced the presentation.

References

1. Tan J, Berg M. Rosacea: current state of epidemiology. *J Am Acad Dermatol* 2013; 69 (6 Suppl 1): S27–35.
2. Tüzün Y, Wolf R, Kutlubay Z, Karakus O, Engin B. “Rosacea and rhinophyma”. *Clin Dermatol* 2014; 32: 35–46.
3. All about rosacea. National Rosacea Society. Retrieved 2008-11-10.. Available from <https://www.rosacea.org/patients/allaboutrosacea.php>.
4. Van Zuuren EJ, Fedorowicz Z, Carter B, et al. Interventions for rosacea. *Cochrane Database Syst Rev* 2015; 4: CD003262.
5. Wilkin J, Dahl M, Detmar M, Drake L, Feinstein A, Odom R, Powell F. Standard classification of rosacea: report of the National Rosacea Society Expert Committee on the classification and staging of rosacea. *J Am Acad Dermatol* 2002; 46: 584–587.
6. Berg M, Liden S. Epidemiological study of rosacea. *Acta Derm Venereol* 1989; 69: 419–423.
7. Abram K, Silm H, Maaros HI, Oona M. Risk factors associated with rosacea. *J Eur Acad Dermatol Venereol* 2010; 24: 565–571.
8. Augustin M, Herberger K, Hintzen S, Heigel H, Franzke N, Schäfer I. Prevalence of skin lesions and need for treatment in a cohort of 90880 workers. *Br J Dermatol* 2011; 165: 865–873.

9. Wayne Blount B, Peletier AL. Studies have shown that women are affected about two to three times more frequently than men. *Am Fam Physician* 2002; 66: 435–441.
10. Wollina U, Verma SB. Rosacea and rhinophyma: not curse of the Celts but Indo Eurasians. *J Cosmet Dermatol* 2009; 8: 234–235.
11. Baldwin HE. Diagnosis and treatment of rosacea: state of the art. *J Drugs Dermatol* 2012; 11; 725–730.
12. Jansen T. Clinical presentations and classification of rosacea. *Ann Dermatol Venereol* 2011; 138 (Suppl 3): S192–S200.
13. Jansen T, Plewig G. Clinical and histological variants of rhinophyma, including nonsurgical treatment modalities. *Facial Plast Surg* 1998; 14: 241–253.
14. Gudmundsen KJ, O'Donnell BF, Powell FC. Schirmer testing for dry eyes in patients with rosacea. *J Am Acad Dermatol* 1992; 26: 211–214.
15. Michel J, Cabibel F. Frequency, severity, and treatment of ocular rosacea during cutaneous rosacea. *Ann Dermatol Venereol* 2003; 130: 20–24.
16. Baker O, Demiray Z, Cakir S. Ocular signs, symptoms and tear function tests of papulopustular rosacea patients receiving azithromycin. *J Eur Acad Dermatol Venereol* 2009; 23: 544–549.
17. Weinkle AP, Doktor V, Emer J. Update on the management of rosacea. *Clin Cosmet Invest Dermatol* 2015; 8: 159–177.
18. Tan J, Blume-Peytavi U, Ortonne JP, Wilhelm K, Marticou L, Baltas E, et al. An observational cross-sectional survey of rosacea: clinical associations and progression between subtypes. *Br J Dermatol* 2013; 169; 555–562.
19. Cribier B. Rosacea under the microscope: characteristic histological findings. *J EADV* 2013; 27: 1336–1343.
20. Chang AL, Raber I, Xu J, Li R, Spitale R, Chen J, et al. Assessment of the genetic basis of rosacea by genome-wide association study. *J Invest Dermatol* 2015; 135: 1548–1555.

21. Yamasaki K, Di Nardo A, Bardan A, Murakami M, Ohtake T, Coda A, et al. Increased serine protease activity and cathelicidin promotes skin inflammation in rosacea. *Nat Med* 2007; 13: 975–980.
22. Muto Y, Wang Z, Vanderberghe M, Tuo A, Gallo RL, Di Nardo A. Mast cells are key mediators of catheli-cidin-initiated skin inflammation in rosacea. *J Invest Dermatol* 2014; 134: 2728–2736.
23. Guzman Sanchez DA, Ishiujji Y, Patel T, Fountain J, Chan YH, Yosipovitch G. Enhanced skin blood flow and sensitivity to noxious heat stimuli in papulopustular rosacea. *J Am Acad Dermatol* 2007; 57: 800–805.
24. Lohne-Rahm S, Nordlind K, Edström DW, Ros AM, Berg M. Laser treatment of rosacea: a pathoetiologi-cal study. *Arch Dermatol* 2004; 140: 1345–1349.
25. Scharschmidt TC, Yost JM, Truong SV, Steinhoff M, Wang KC, Berger TG. Neurogenic rosacea: a distinct clinical subtype requiring a modified approach to treatment. *Arch Dermatol* 2011; 147: 123–126.
26. Kheirkhah A, Casas V, Li W, Raju VK, Tseng SC. Corneal manifestations of ocular demodex infestation. *Am J Ophthalmol* 2007; 143: 743–749.
27. Casas C, Paul C, Lahfa M. Quantification of Demodex folliculorum by PCR in rosacea and its relationship to skin innate immune activation. *Exp Dermatol* 2012; 21: 906–910.
28. Sattler EC, Hoffmann VS, Ruzicka T, Braunmühl TV, Berking C. Reflectance confocal microscopy for monitoring the density of Demodex mites in rosacea before and after treatment. *Br J Dermatol* 2015; 173: 69–75.
29. Lacey N, Delaney S, Kavanagh K, Powell FC. Mite-related bacterial antigens stimulate inflammatory cells in rosacea. *Br J Dermatol* 2007; 157: 474–481.
30. O'Reilly N, Bergin D, Reeves EP, McElvaney NG, Kavanagh K. Demodex-associated bacterial proteins induce neutrophil activation. *Br J Dermatol* 2012; 16684: 753–760.
31. Li J, O'Reilly N, Sheha H, Katz R, Raju VK, Kavanagh K, Tseng SC. Correlation between ocular Demodex infestation and serum immunoreactivity to Bacillus proteins in patients with facial rosacea. *Ophthalmology* 2010; 117: 870–877.
32. Murillo N, Aubert J, Raoult D. Microbiota of Demodex mites from rosacea patients and controls. *Microb Pathog* 2014; 71–72: 37–40.
33. Van der Linden, Health related Quality of life in patients with cutaneous rosacea; a systematic review. *Acta Derm Venereol* 2015; 95: 395–400.
34. Moustafa B, Lewallen RS, Feldman SR. The psychological impact of rosacea and the influence of current management options. *JAAD* 2014; 71: 973–980.
35. Aksoy B, Altaykan-Hapa A, Egemen D, Karagöz F, Atakan N. The impact of rosacea on quality of life: effects of demographic and clinical characteristics and various treatment modalities. *Br J Dermatol* 2010; 163: 719–725.
36. Trumbore MW, Goldstein JA, Gurge RM. Treatment of papulopustular rosacea with sodium sulfacetamide 10%/sulfur 5% emollient foam. *J Drugs Dermatol* 2009; 8: 299–304.
37. Fleischer A, Suephy C. The face and mind evaluation study: an examination of the efficacy of rosacea treatment using physician ratings and patients' self-reported quality of life. *J Drugs Dermatol* 2005; 4: 585–590.
38. Baldwin HE. A community-based study of the effectiveness of doxycycline 40 mg (30-mg immediate-release and 10-mg delayed-release beads) on quality of life and satisfaction with treatment in participants with rosacea. *Cutis* 2010; 86: 26–36.
39. Stein L, Kircik L, Fowler J, Tan J, Draelos Z, Fleischer A, et al. Efficacy and safety of ivermectin 1% cream in treatment of papulopustular rosacea: results of two randomized, double-blind, vehicle-controlled pivotal studies. *J Drugs Dermatol* 2014; 13: 316–323.
40. Egeberg A, Hansen PR, Gislason GH, Thyssen JP. Patients with rosacea have increased risk of depression and anxiety disorders: a Danish Nationwide Cohort Study. *Dermatology* 2016; 232: 208–213.
41. Egeberg A, Ashina M, Gaist D, Gislason GH, Thyssen JP, et al. Prevalence and risk of migraine in patients with rosacea: a population-based cohort study. *J Am Acad Dermatol* 2016; 76: 454–458.
42. Spoendlin J, Voegel JJ, Jick SS, Meier CR. Migraine, triptans, and the risk of developing rosacea. A population-based study within the United Kingdom. *J Am Acad Dermatol* 2013; 69: 399–406.
43. Egeberg A, Fowler JF Jr, Gislason GH, Thyssen JP. Nationwide assessment of cause-specific mortality in patients with rosacea: a cohort study in Denmark. *Am J Clin Dermatol* 2016; 17: 673–679.
44. Egeberg A, Thyssen JP. Association between rosacea and Parkinson disease-reply. *JAMA Neurol* 2016; 1; 73: 1159–1160.
45. Egeberg A, Hansen PR, Gislason GH, Thyssen JP. Patients with rosacea have increased risk of dementia. *Ann Neurol* 2016; 79: 921–928.
46. Egeberg A, Hansen PR, Gislason GH, Thyssen JP. Clustering of autoimmune diseases in patients with rosacea. *J Am Acad Dermatol* 2016; 74: 667–672.
47. Egeberg A, Weinstock LB, Thyssen EP, Gislason GH, Thyssen JP. Rosacea and gastrointestinal disorders: a population-based cohort study. *Br J Dermatol* 2016; 176: 100–106.
48. Egeberg A, Hansen PR, Gislason GH, Thyssen JP. Assessment of the risk of cardiovascular disease in patients with rosacea. *J Am Acad Dermatol* 2016; 75: 336–339.
49. Rainer BM, Fischer AH, Luz Felipe da Silva D, Kang S, Chien AL. Rosacea is associated with chronic systemic diseases in a skin severity-dependent manner: result of a case-control study. *J Am Acad Dermatol* 2015; 73: 604–608.
50. Van Zuuren EJ, Fedorowicz Z. Interventions for rosacea: abridged updated Cochrane systematic review including GRADE assessments. *Br J Dermatol* 2015; 173: 651–662.
51. Wu PA, Balagula Y, Lacouture ME, Anadkat MJ. Prophylaxis and treatment of dermatologic adverse events from epidermal growth factor receptor inhibitors. *Curr Opin Oncol* 2011; 23: 343–351.
52. Tan J, Leoni M. Erythema of rosacea: validation of patient's self-assessment grading. *J Drugs Dermatol* 2015; 14: 841–844.
53. Powell FC. Clinical practice. Rosacea. *N Engl J Med* 2005; 352: 793–803.
54. Wilkin J. Rosacea. Pathophysiology and treatment. *Arch Dermatol* 1994; 130: 359–362.
55. Elewski BE, Draelos Z, Dréno B, Jansen T, Layton A, Picardo M. Rosacea – global diversity and optimized outcome: proposed international consensus from the Rosacea International Expert Group. *J Eur Acad Dermatol Venereol* 2011; 25: 188–200.
56. MIRVASO® in use study: managing rosacea through assessment and control of its erythema (The MIRACLE Study). Available from: <https://clinicaltrials.gov/ct2/show/NCT02249065>.
57. Nymann P, Hedelund L, Haedersdal M. Long-pulsed dye laser vs. intense pulsed light for the treatment of facial teleangiectasias: a randomized controlled trial. *J Eur Acad Dermatol Venereol* 2010; 24: 143–149.
58. Papegeorgiou P, Clayton W, Norwood S, Chopra S, Rustin M. Treatment of rosacea with intense pulsed light: significant improvement and long-lasting results. *Br J Dermatol* 2008; 159: 628–632.
59. Alam M, Voravutinon N, Warycha M, Whiting D, Nodzinski M, Yoo S, et al. Comparative effectiveness of non purpuragenic 595-nm pulsed dye laser and microsecond 1064 nm neodymium: yttrium-aluminium-garnet laser for treatment of diffuse facial erythema: a double-blind randomized controlled trial. *J Am Acad*

- Dermatol 2013; 69: 438–443.
60. Kim JH, Oh YS, Ji JH, Bak H, Ahn SK. Rosacea (erythematoteleangiectatic type) effectively improved by topical xylometazoline. *Br J Dermatol* 2011; 38: 510–513.
 61. Neuhaus IM, Zane LT, Tope WD. Comparative efficacy of nonpurpuragenic pulsed dye laser and intense pulsed light for erythematoteleangiectatic rosacea. *Dermatol Surg* 2009; 35: 920–928.
 62. Fowler J Jr, Jackson M, Moore A, Jarratt M, Jones T, Meadows K. Efficacy and safety of once-daily topical brimonidine tartrate gel 0.5% for the treatment of moderate to severe facial erythema of rosacea: results of two randomized, double blinded and vehicle-controlled pivotal studies. *J Drugs Dermatol* 2013; 12: 650–656.
 63. Hsu CC, Lee. Pronounced facial flushing and persistent erythema of rosacea effectively treated by carvedilol, a nonselective β -adrenergic blocker. *J Am Acad Dermatol* 2012; 67: 491–493.
 64. Park KY, Hyun MY, Jeong SY, Kim BJ, Kim MN, Hong CK. Botulinum toxin for the treatment of refractory erythema and flushing of rosacea. *Dermatology* 2015; 230: 299–301.
 65. Crump A, Omura S. Ivermectin, ‘wonder drug’ from Japan: the human use perspective. *Proc Jpn Acad Ser B Phys Biol Sci* 2011; 87: 13–28.
 66. Gueerrero-Gonzalez GA, Herz-Ruelas ME, Gomes-Flores M, Ocampo-Candiani J. Crusted demodicosis in an immunocompetent pediatric patient. *Case Rep Dermatol Med* 2014; 2014: 458046.
 67. Brown M, Hernandez-Martin A, Clement A, Colmenero I, Torrelo A. Severe demodexfolliculorum-associated oculocutaneous rosacea in a girl successfully treated with ivermectin. *JAMA Dermatol* 2014; 150: 61–63.
 68. Stankiewicz M, Cabaj W, Jonas WE, Moore LG, Millar K, Ng Chie W. Influence of ivermectin on cellular and humoral immune responses of lambs. *Vet Immunol Immunopathol* 1995; 44: 347–358.
 69. Labro MT. Anti-inflammatory activity of macrolides: a new therapeutic potential? *J Antimicrob Chemother* 1998; 41 Suppl B: 37–46.
 70. Ci X, Li H, Yu Q, Zhang X, Yu L, Chen N, et al. Avermectin exerts anti-inflammatory effect by downregulating the nuclear transcription factor kappa-B and mitogen-activated protein kinase activation pathway. *Fundament Clinical Pharmacol* 2009; 23: 449–455.
 71. Taieb A, Ortonne JP, Ruzicka T, Roszkiewicz J, Berth-Jones J, Peirone MH, et al. Superiority of ivermectin 1% cream over metronidazole 0.75% cream in treating inflammatory lesions of rosacea: a randomized, investigator blinded trial. *Br J Dermatol* 2015; 172: 1103–1110.
 72. Gollnick H, Blume-Peytavi U, Szabó EL, Meyer KG, Hauptmann P, Popp G, et al. Systemic isotretinoin in the treatment of rosacea - doxycycline - and placebo-controlled, randomized clinical study. *J Dtsch Dermatol Ges* 2010; 8: 505–515.
 73. Aysegul A, Demirseren DD, Takmaz T. Treatment of ocular rosacea: comparative study of topical cyclosporine and oral doxycycline. *Int J Ophthalmol* 2015; 8: 544–549.
 74. Schechter B, Katz RS, Friedman LS. Efficacy of topical cyclosporine for the treatment of ocular rosacea. *Adv Ther* 2009; 26: 651–659.
 75. Pfeiffer I, Zierhut M, Schaller M. Treatment of ocular rosacea with 40 mg doxycycline in a slow release form. *J Dtsch Dermatol Ges* 2011; 9: 904–907.
 76. Pflugfelder SC, Geerling G, Kinoshita S, Lemp MA, McCulley J, Nelson D, et al. Management and therapy of dry eye disease: report of the management and therapy subcommittee of the international Dry Eye Workshop (2007). *Ocular Surface* 2007; 5: 163–178.
 77. Miljanovi B, Trivedi KA, Dana MR, Gilbard JP, Buring JE, Schumberg DA. Relation between dietary n-3 and n-6 fatty acids and clinically diagnosed dry eye syndrome in women. *Amer J Clin Nutr* 2005; 82: 887–893.
 78. Barabino M, Rolando P, Camicione P, Ravera G, Zanardi S, Giuffrida S, Calabria G. Systemic linoleic and γ -linolenic acid therapy in dry eye syndrome with an inflammatory component. *Cornea* 2003; 22: 97–101.
 79. Asai Y, Tan J, Baibergenova A, Barankin B, Cochrane CL, Humphrey S, et al. Canadian clinical practice guidelines for rosacea. *J Cutan Med Surg* 2016; 20: 432–445.
 80. Kickbush L. Patient empowerment – who empowers whom. *Erratum in Lancet* 2012 Aug 18; 380 (9842): 650.
 81. Asai Y, Tan J, Baibergenova A, Barankin B, Cochrane CL, Humphrey S, et al. Canadian clinical practice guidelines for rosacea. *J Cutan Med Surg* 2016; 20: 432–445.