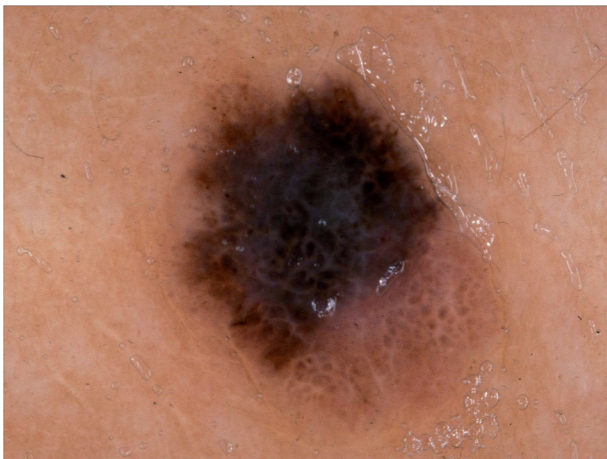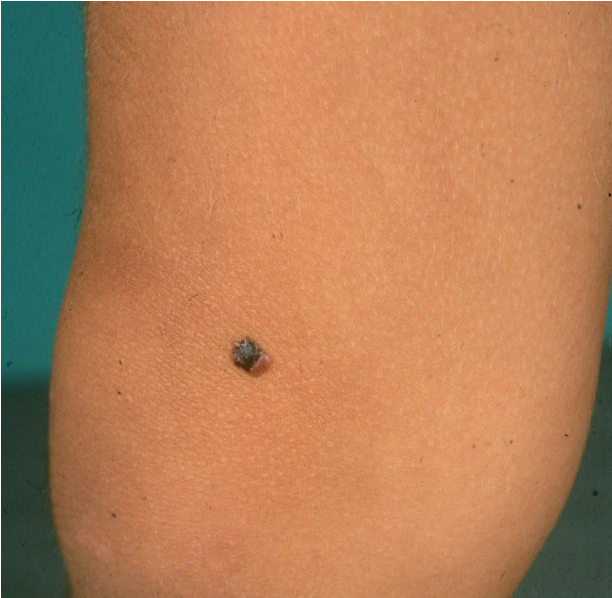


## How is Your Skill to Diagnose a Skin Lesion by Dermoscopy?

KAARE WEISMANN, PROFESSOR, DR.MED.  
E-mail: [weisech@dadlnet.dk](mailto:weisech@dadlnet.dk)

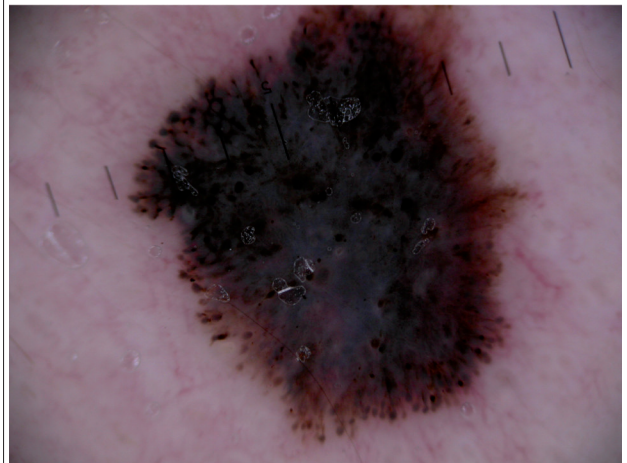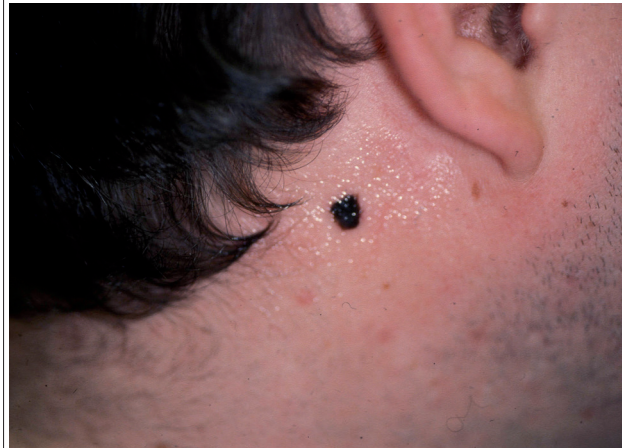Case 9: A 20-year-old woman with a two-coloured element on her right knee



What is your diagnosis?

1. Lentigo maligna
2. Junction naevus
3. Pigmented spindle cell naevus

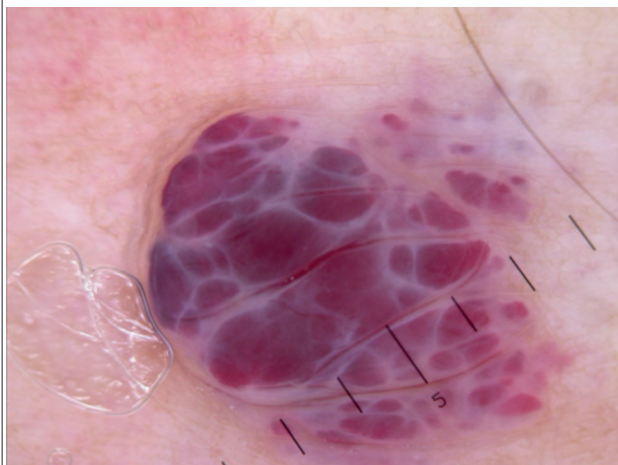
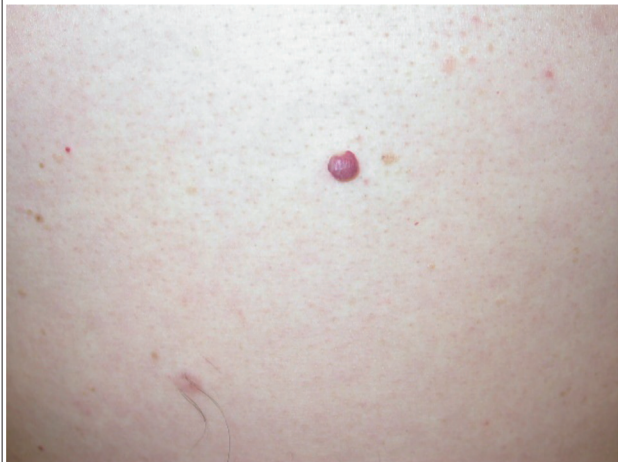Case 10: A 27-year-old man with a black lesion on his neck



What is your diagnosis?

1. Junction naevus
2. Malignant melanoma
3. Pigmented spindle cell naevus

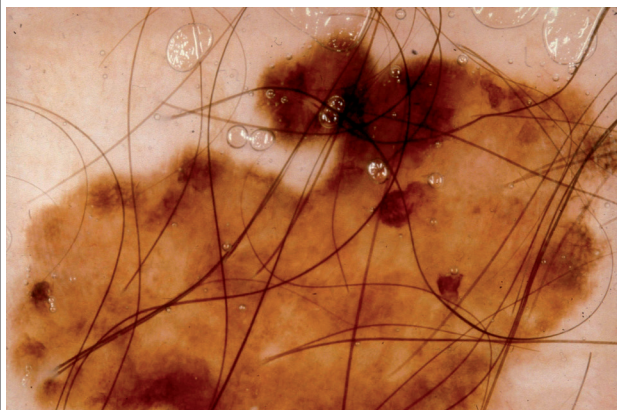
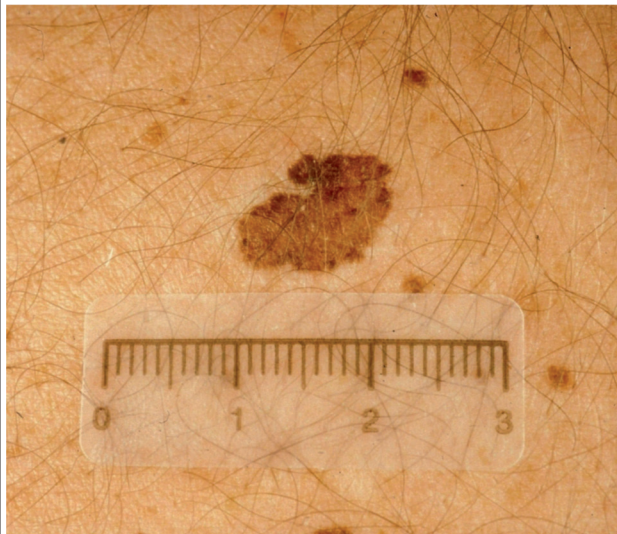
Case 11: A young woman with a tumor on her right thigh



**What is your diagnosis?**

- 1. Amelanotic melanoma
- 2. Eruptive haemangioma
- 3. Angiokeratoma

Case 12: A 67-year-old man with a brown lesion on his back



**What is your diagnosis?**

- 1. Seborrhoeic keratosis
- 2. Malignant melanoma
- 3. Basal cell carcinoma

*Find the answers on bottom of page 29.*