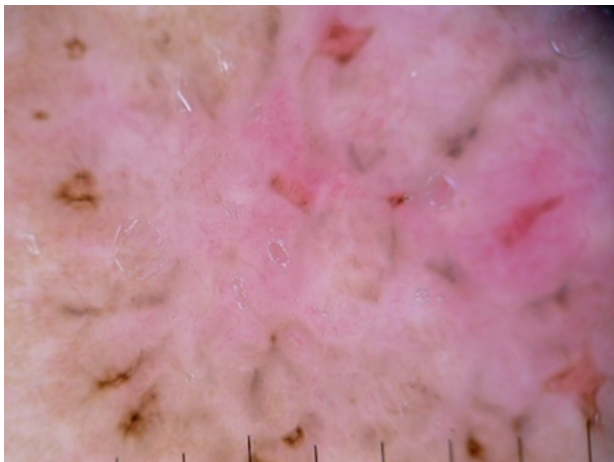
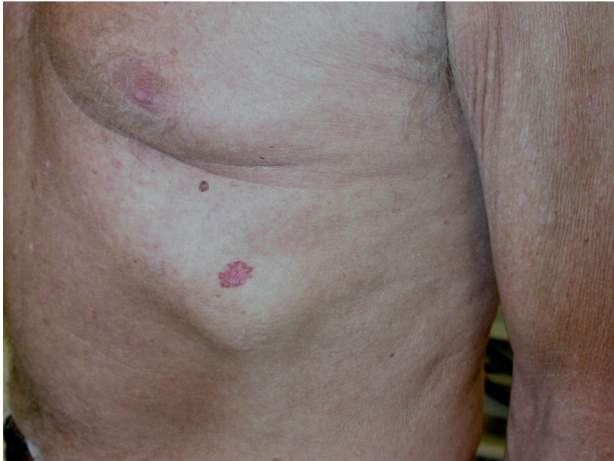

How is Your Skill to Diagnose a Skin Lesion by Dermoscopy?

KAARE WEISMANN, PROFESSOR, DR.MED.

E-mail: weisech@dadlnet.dk

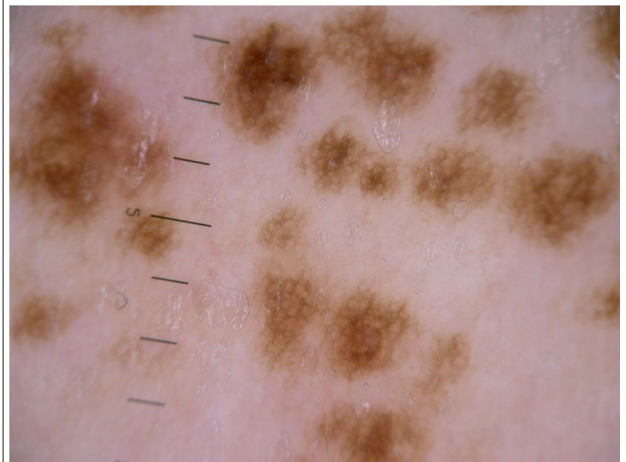
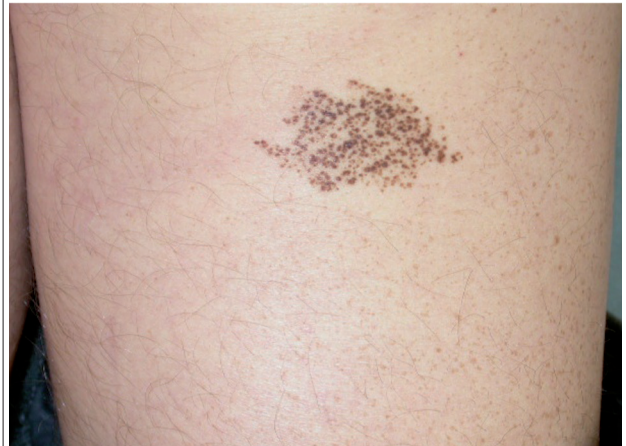Case 13: A 70-year-old man with a lesion on his chest



What is your diagnosis?

1. Actinic keratosis
2. Seborrheic keratosis
3. Basal cell carcinoma

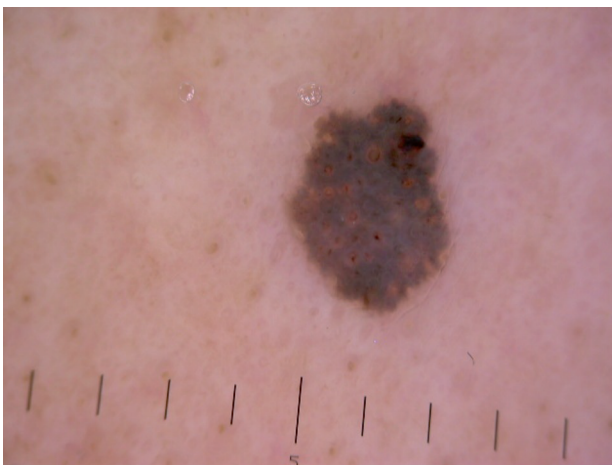
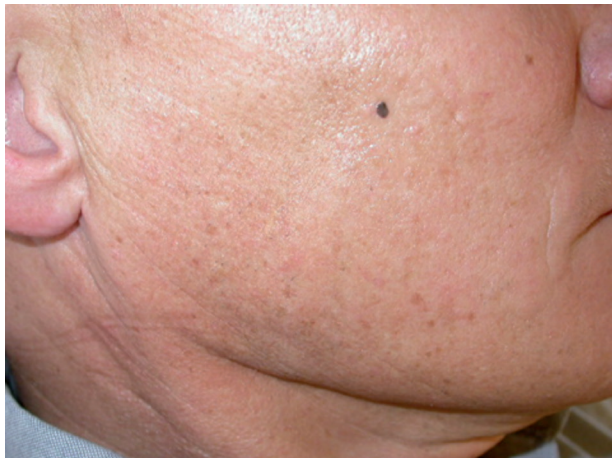Case 14: A 16-year-old boy with dotted pigmentation on his left thigh



What is your diagnosis?

1. Naevus spilus (speckled and lentiginous naevus)
2. Accidental tattoo
3. Ink spot lentigo

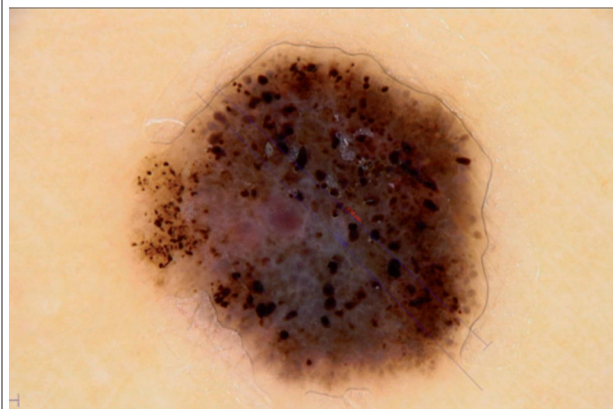
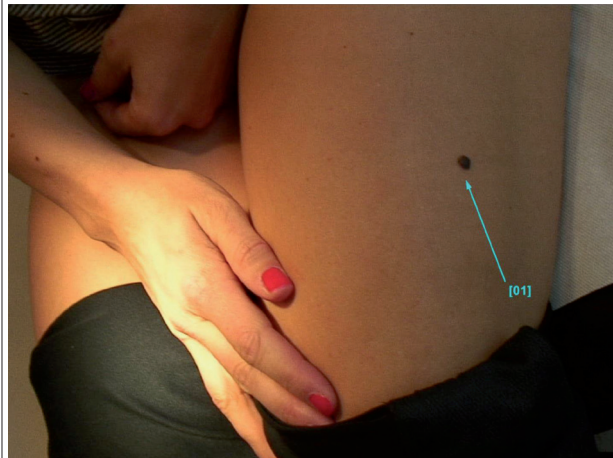
Case 15: A 52-year-old man with a lesion on his right cheek



What is your diagnosis?

1. Lentigo maligna
2. Pigmented actinic keratosis
3. Seborrheic keratosis

Case 16: A 35-year-old woman with a black lesion on her left thigh



What is your diagnosis?

1. Ink spot lentigo
2. Malignant melanoma
3. Compound naevus

Find the answers on bottom of page 62.