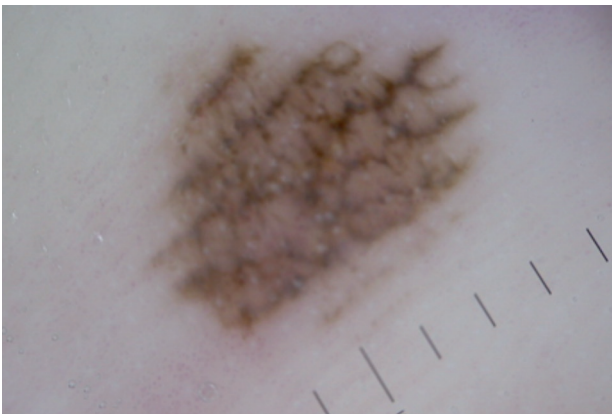
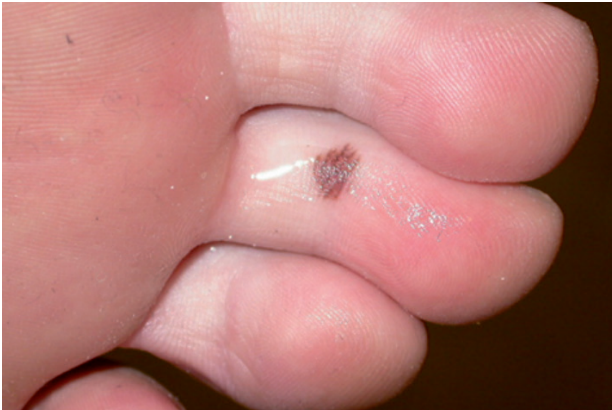

How is Your Skill to Diagnose a Skin Lesion by Dermoscopy?

KAARE WEISMANN, PROFESSOR, DR.MED.
E-mail: weisech@dadlnet.dk

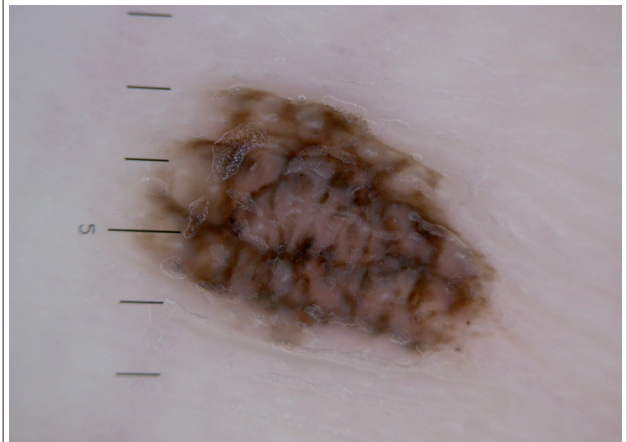
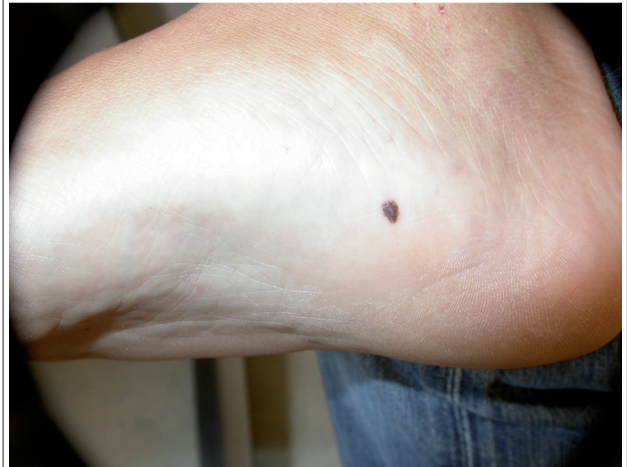Case 21: A 20-year-old woman with a brownish lesion on her right third toe



What is your diagnosis?

1. Junctional naevus
2. Acrolentiginous melanoma
3. Haemorrhagic lesion

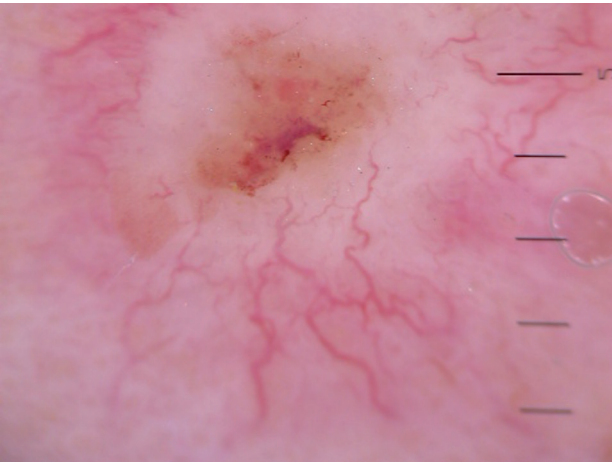
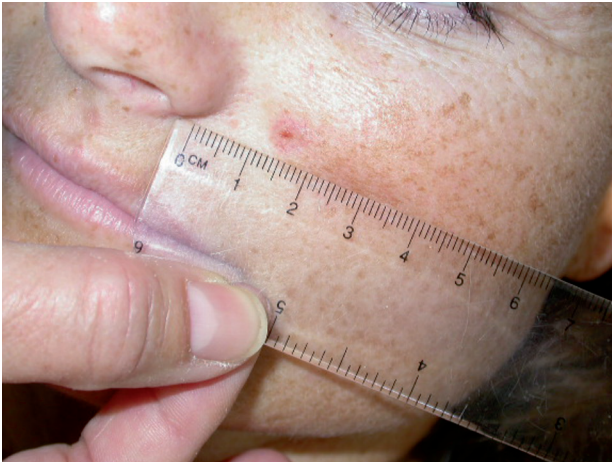Case 22: A 25-year-old man with a dark-brown lesion on his right foot



What is your diagnosis?

1. Malignant melanoma
2. Pigmented spindle cell naevus
3. Junctional naevus

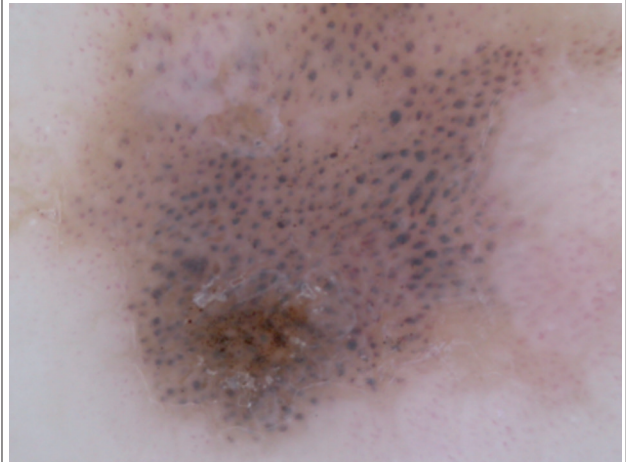
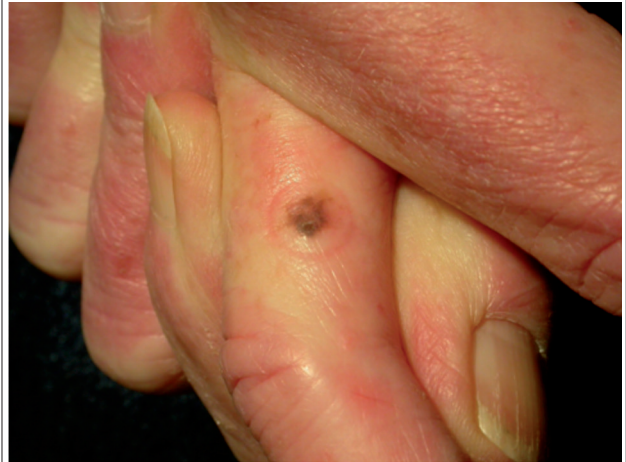Case 23: A 29-year-old woman with a red lesion on her left cheek



What is your diagnosis?

1. Eruptive haemangioma
2. Basal cell carcinoma
3. Benign lichenoid keratosis

Case 24: A 62-year-old woman with a brown lesion on her second right finger



What is your diagnosis?

1. Mb. Bowen
2. Basal cell carcinoma
3. Melanocytic naevus

Find the answers on bottom of page 36.