

Erythema Multiforme-like Eruption in a Teenager Suspected with COVID-19 Infection

KRISTIAN BAKKE ARVESEN¹, LUIT PENNINGA², DORTE FRIS PALMQVIST³, KATHRIN WERNER DAHL⁴, PETER BJERRING⁵, AND CARSTEN SAUER MIKKELSEN⁶

¹Specialist in Dermato-venereology, Research lab. Department of Dermato-venereology, Aalborg University Hospital, Denmark, ²Specialist in Surgery, Ilulissat Hospital, Avannaq Region, Ilulissat, Greenland, ³Specialist in Anesthesiology, Department of Anesthesia and Intensive Care, Bispebjerg and Frederiksberg Hospital, University of Copenhagen, Denmark, ⁴Specialist in Pediatrics, Department of Paediatrics and Adolescent Medicine, Nordsjælland Hospital, University of Copenhagen, Denmark, ⁵Specialist in Dermato-venereology, Department of Dermato-venereology, Aalborg University Hospital, Denmark, and ⁶Specialist in Dermato-venereology, Private Practice in Dermato-venereology, Brønderslev, Denmark, and Research Lab., Department of Dermato-venereology, Aalborg University Hospital, Denmark



BACKGROUND

The pandemic outbreak of the novel corona virus disease COVID-19 started in Wuhan, Hubei province in China in December 2019. With now globally, as of 17 June 2020, 440,290 registered deaths and over 8 million confirmed cases reported to WHO, it is clear that COVID-19 has an enormous impact on many levels (1). There is still investigation going on to understand the spectrum of symptoms, epidemiology and transmission mechanisms. In the present case we report a dermatological manifestation of COVID-19 in an adolescent.

CASE PRESENTATION

On March 30th 2020, a 15-year-old boy with known well-treated asthma developed dry cough, no fever. His mother showed symptoms of COVID-19 on the 23rd of February, and the nasal swab was positive on the day after her symptoms started. The mother was isolated from the family as from the symptoms

started until the 3rd of April. Almost at the same time as the dry cough the boy developed skin lesions. The skin lesions were mildly pruritic symmetric erythematous papules developing to vesicles located on the hands. On the 13th of April the pulmonary symptoms worsened and he was admitted to the paediatric department. The tentative diagnosis was asthma exacerbation. The chest X-ray was normal, and the throat swab and tracheal aspirate for COVID-19 was negative. The tracheal secretion culture was negative for bacteria causing atypical pneumonia (mycoplasma, legionella, chlamydia) but positive for *Moraxella catarrhalis*, and he was treated with amoxicillin/clavulanic acid in tablet form for a 10 day period. The blood test showed only mildly neutrophilia 7.8 mmol/l, and a normal C-reactive-protein (CRP). A lung function test revealed a drop in FEV-1 to 45% of what was expected (FEV-1 76% of what was expected in November 2019). Because of the severe pulmonary symptoms, he was treated with 50 mg prednisolone daily for one week. After a week of hospitalization, he was discharged with increased doses of asthma medication.

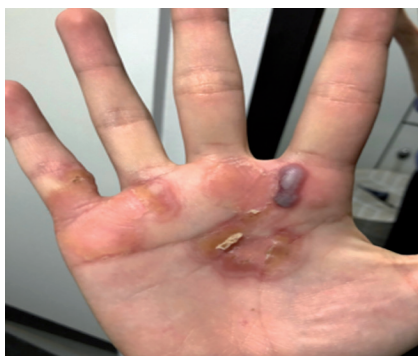

Fig. 1. Right hand, 6th of April.

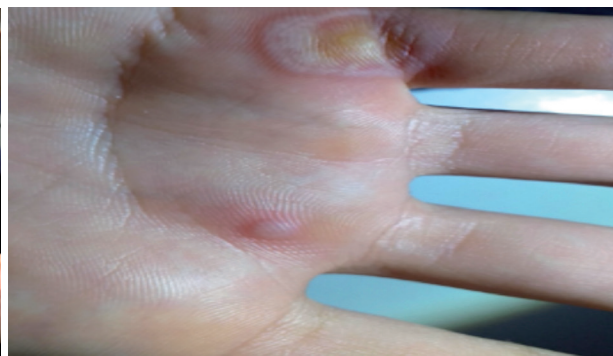

Fig. 2. Left hand, 6th of April.

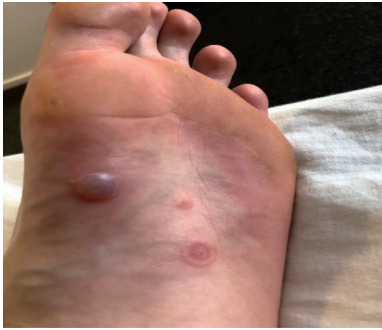

Fig. 3. Left foot, 5th of June.

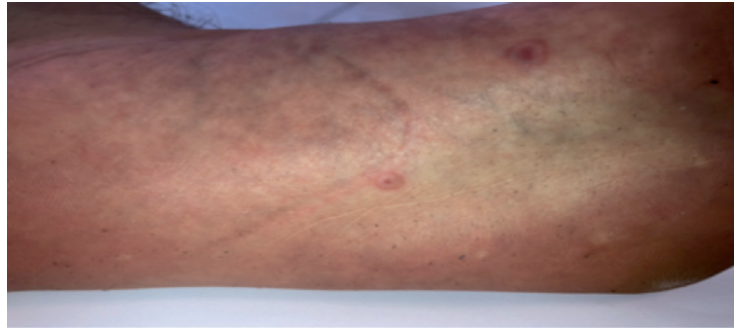


Fig. 4. Left arm, 5th of June.

On the 6th of May 2020 the papules on the hands increased in size and some of them formed blisters. They healed up without scarring, with constantly new elements appearing, though only on the hands. Because of the worsening of the cutaneous symptoms, he was again examined at the paediatric department. The blisters were punctuated and the fluid tested (Polymerase Chain Reaction) for COVID-19. The test came out negative, as did the IgG antibody test for COVID-19. Blood tests were without abnormalities in both red and white blood count, CRP, liver and kidney tests. He was discharged without any treatment.

On the 2nd of June the cutaneous symptoms again worsened, now with target lesions on hands, forearm, feet and legs. Again, swab from the throat and a COVID-19 IgG antibody test were negative. After examination on the dermatologic department the suspicion of bullous erythema multiforme (EM)-like lesions was raised, and he was successfully treated with a group 3 corticosteroid creme.

DISCUSSION

In this case we present a patient with suspected COVID-19 with cutaneous manifestations clinically consistent with EM. Viral infections are the most common causes of EM with Epstein Barr-virus, herpes simplex, varicella and cytomegalovirus as the most frequently found viruses (2). Drugs are the second most common causes of EM (2).

This patient had no recent history or any clinical sign of any of these disorders or exposures. He was strongly suspected of COVID-19 based on the exposure and the confirmed case of the mother and the absence of other causes of the severe pulmonary symptoms.

In a recent consensus study the cutaneous manifestations of COVID-19 were classified in 5 clinical patterns (3). The patterns were described as pseudo-chilblains, other vesicular lesions, urticarial lesions, maculopapular eruptions and live-do or necrosis. The most common manifestation was other maculopapular eruptions (47%) including EM.

In conclusion, as dermatologists we need to be aware of possible new and multimorphological cutaneous presentations of COVID-19. Cutaneous manifestations can be the initial symptom of COVID-19.

REFERENCES

1. WHO Coronavirus Disease (COVID-19) dashboard available at: <https://covid19.who.int/>.
2. Zoghaib S, Kechichian E, Souaid K, Soutou B, Helou J, Tomb R. Triggers, clinical manifestations, and management of pediatric erythema multiforme: A systematic Rview. *J Am Acad Dermatol* 2019; 81: 813–822.
3. Galván Casas C, Català A, Carretero Hernández G, Rodríguez-Jiménez P, Fernández-Nieto D, Rodríguez-Villa Lario A, et al. Classification of the cutaneous manifestations of COVID-19: a rapid prospective nationwide consensus study in Spain with 375 cases. *Br J Dermatol* 2020; 183: 71–77.