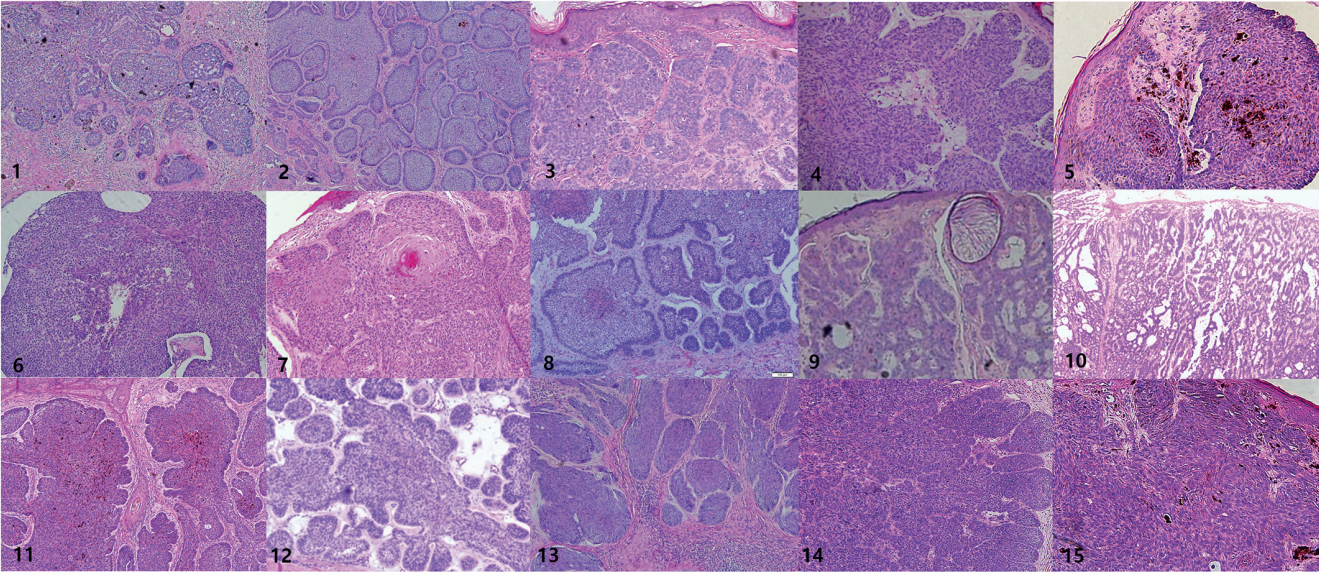


Low-risk BCC



High-risk BCC

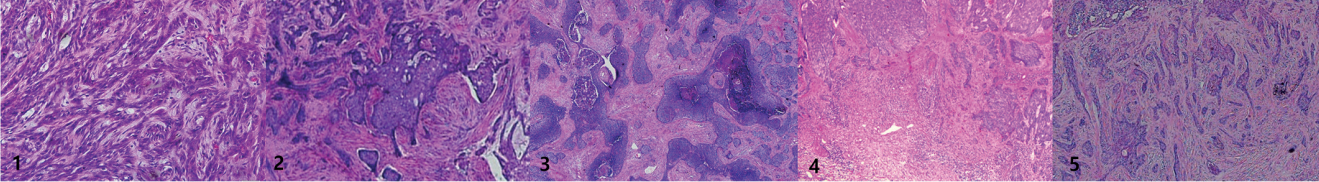


Fig. S1. Histology of 20 basal cell carcinoma (BCC) samples (haematoxylin and eosin (H&E), 100x).