

Dermal Melanocytosis Associated with GM1-Gangliosidosis Type 1

Leila David Bloch, Fernando Yoshiaki Matsumoto, Walter Belda Jr, Roberto Giugliani, Luis Fernando Menezes, Chong A. Kim and Maria Cecilia da Matta Rivitti Machado

Department of Dermatology, Faculty of Medicine, University of Sao Paulo, Avenida Doutor Enéas Carvalho de Aguiar, 255, Sao Paulo, SP, Brazil, 05403-900. E-mail: leiladbloch@hotmail.com

Accepted September 12, 2005.

Sir,

Lysosomal storage disorders (LSD) are characterized by the accumulation of partially degraded insoluble metabolites within lysosomes. GM1-gangliosidosis type 1 is a particularly severe LSD with marked central nervous system involvement.

Dermal melanocytosis encompasses a clinical spectrum of cutaneous diseases such as Mongolian spots, naevus of Ota, naevus of Ito and acquired symmetrical dermal melanocytosis of the face (1).

The association of dermal melanocytosis with LSD is uncommon and still poorly understood (2). We report here a case of dermal melanocytosis associated with GM1-gangliosidosis type 1.

CASE REPORT

A 7-month-old mestizo girl from Brazil was referred for evaluation of extensive and unusual slate-blue macules resembling Mongolian spots. All areas of the skin, with exception of the face, scalp, palms and soles, were involved. Lesions were macular, grey to blue-black, non-hairy, usually sharply demarcated and varied in shape and size from a few millimetres to several centimetres in diameter. Larger lesions were distributed over the anterior and posterior trunk and dorsal sides of the hands and feet (Fig. 1). The lesions were present at birth and their number did not increase with time.

She was the first child of healthy non-consanguineous parents, with no past history of complications during the perinatal or delivery period. Moreover, no family history of any congenital anomalies or genetic disorders was reported. In addition to the skin lesions, the infant had coarse facial features with palpebral oedema, strabismus, low nasal bridge, broad nose, long philtrum, gingival hypertrophy, short neck, hepatomegaly and hirsutism. At 1 year of age she presented generalized muscle hypotonia, pyramidal signs, lethargy and progressive developmental delay, with mental retardation.

A 3-mm punch biopsy was obtained from one of the hyperpigmented cutaneous macules, revealing dermal melanocytosis and vacuolated eccrine gland cells. Electron microscopy revealed ubiquitously distributed membrane-bound clear vacuoles in fibroblasts and eccrine gland epithelial cells (Fig. 2). Bone X-ray imaging showed vertebral deformities, with hypoplasia and anterior beaking at the thoracolumbar region and slightly widened ribs. Metacarpal bones had a thinning of the cortical wall. Cranial computed tomography (CT) scan showed enlargement of the ventricular system. Ophthalmological examination revealed macular cherry-red spots and corneal clouding.

Definite diagnosis of GM1-gangliosidosis was made on typical urinary oligosaccharides chromatographic profile and low level of β -galactosidase activity in leukocytes and cultured skin fibroblasts. Normal urinary excretion and chromatography of glycosaminoglycan and level of α iduronidase could rule out mucopolysaccharidosis (MPS) type I.

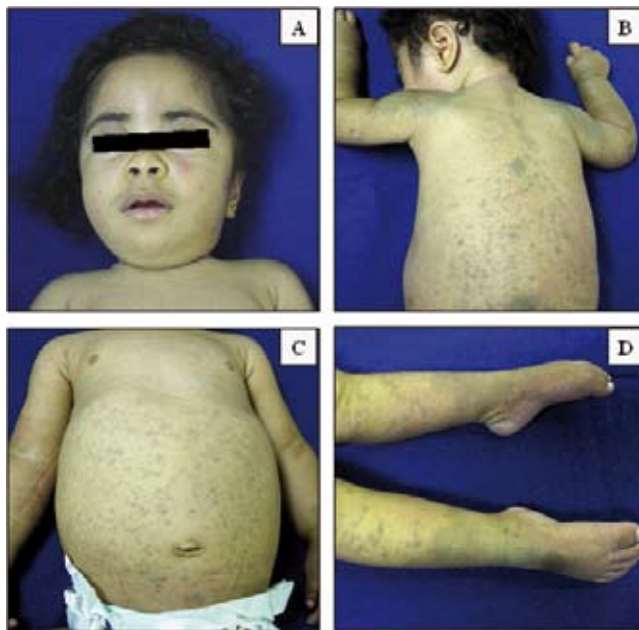

Fig. 1. (A) Typical dysmorphic features, including coarse facies and flattened nasal bridge. (B) Extensive, blue cutaneous patches of the posterior trunk. (C) Similar skin changes present over the anterior trunk. (D) Legs and feet showing marked variation in size and shape of macules.

The patient is now 1 year and 8 months of age and has been hospitalized several times due to pulmonary infections. She also presents generalized hypotonia with severely delayed acquisition of motor milestones.

DISCUSSION

GM1-gangliosidosis (OMIM 230500) is a rare autosomal recessive lysosomal storage disorder caused by a deficiency of β -galactosidase (3). Although its incidence is not known, the infantile form (type 1) can affect 1 in 3700 live births in the Maltese Islands population (4). Type 1 GM1-gangliosidosis is usually diagnosed in early infancy, when developmental arrest or delay becomes evident. Definite functional deterioration of the nervous system follows within several months. Generalized muscle hypotonia, present at the initial stages, evolves into spasticity with frequent convulsive seizures. The patient becomes vegetative and death ensues within a few years. Macular cherry-red spots, corneal clouding and optic atrophy can also be observed. Hepatosplenomegaly is often reported and, in typical cases, dysmorphism and generalized skeletal

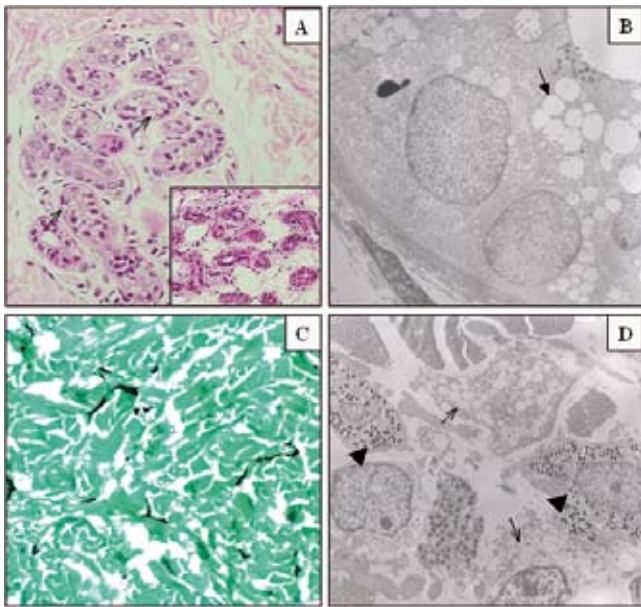


Fig. 2. Skin biopsy. (A) Eccrine sweat gland with vacuolated epithelial cells (arrows). Inset showing normal sweat gland of another patient (original magnification $\times 200$; haematoxylin-eosin stain). (B) Electron microscopy of eccrine gland epithelial cell with numerous membrane-bound clear vacuoles (arrow; $\times 3000$). (C) Dermal melanocytosis characterized by dendritic melanocytes stained in black ($\times 400$; Fontana-Masson stain). (D) Electron microscopy showing clear vacuoles in dermal fibroblasts (arrows). Melanocytes with scattered cytoplasmic melanosomes can also be seen (arrowheads; $\times 3000$).

dysplasia are evident and progressive. Later onset cases have been grouped as late infantile/juvenile form (type 2) or adult/chronic form (type 3), characterized by a protracted clinical course (3).

Mutations in *GLB-1*, the β -galactosidase gene, are responsible for GM1-gangliosidosis and Morquio disease type B, a generalized dysostosis without central nervous system involvement. In GM1 gangliosidosis, β -galactosidase defects result in progressive accumulation of ganglioside GM1 in the brain (5). In Morquio B disease and GM1-gangliosidosis patients, high amounts of oligosaccharides derived from keratan sulphate or glycoproteins are detected in the visceral organs and urine (6).

Gangliosides are sialic acid-containing glycosphingolipids expressed in the plasma membrane of cells and mediate a variety of modulatory interactions (7). They may exert effects on proliferation and differentiation modulating tyrosine kinase growth factor receptors, such as epidermal growth factor receptor and fibroblast growth factor receptor (8, 9). Recent evidence suggests that the unfolded protein response can be induced by accumulation of the sialoglycolipid GM1 and this causes neuronal apoptosis (10).

A literature analysis revealed 39 cases of dermal melanocytosis in association with lysosomal storage diseases, 24 of which were MPS type I or Hurler syndrome. The first case of association between GM1-gang-

liosidosis and dermal melanocytosis was described by Weissbluth et al. (1) in 1981 and, so far, 11 cases have been published. The Mongolian spots in these patients are often larger and can also be found in the extremities and anterior trunk (11). One hypothesis is that GM1 increase in neural crest cells during development might be involved in its pathogenesis (6). In this context, cell culture experiments demonstrating that addition of cholera toxin induces the differentiation of melanoblasts into mature, pigmented melanocytes are particularly interesting (12). The fact that this effect is known to be mediated by GM1 gangliosides (7) provides a link between GM1 increase and melanocyte differentiation. Though nerve growth factor (NGF) has been implicated (11), the true effect of GM1 on NGF signalling is not known (13, 14).

Although cure is still not possible for GM1-gangliosidosis, early diagnosis and intervention allows proper genetic counselling and anticipatory guidance regarding the typical course of the disease (2).

ACKNOWLEDGEMENTS

We thank Drs Sérgio Rosemberg, Thales de Britto, Valéria Aoki, Miriam N. Sotto, Neusa Y. S. Valente and the Department of Pathology, School of Medicine, University of Sao Paulo for technical support. We also thank Roger Chammas for valuable suggestions.

REFERENCES

- Weissbluth M, Esterly NB, Caro WA. Report of an infant with GM1 gangliosidosis type I and extensive and unusual mongolian spots. *Br J Dermatol* 1981; 104: 195–200.
- Lonergan CL, Payne AR, Wilson WG, Patterson JW, English JC, III. What syndrome is this? Hunter syndrome. *Pediatr Dermatol* 2004; 21: 679–681.
- Suzuki Y, Oshima A, Namba E. β -Galactosidase deficiency (β -galactosidosis). GM1 gangliosidosis and Morquio B disease. In: Scriver CR, Beaudet AL, Sly WS, Valle D, Childs B, Kinzler KW, et al., eds. *The metabolic and molecular bases of inherited disease*. New York: McGraw-Hill, 2001: 3775–3809.
- Lenicker HM, Vassallo AP, Young EP, Attard Montalto SP. Infantile generalized GM1 gangliosidosis: high incidence in the Maltese Islands. *J Inher Metab Dis* 1997; 20: 723–724.
- Mendez HM, Pinto LI, Paskulin GA, Ricachnevsky N. Is there a relationship between inborn errors of metabolism and extensive mongolian spots? *Am J Med Genet* 1993; 47: 456–457.
- Georgiou T, Drousiotou A, Campos Y, Caciotti A, Sztrihai L, Gururaj A, et al. Four novel mutations in patients from the Middle East with the infantile form of GM1-gangliosidosis. *Hum Mutat* 2004; 24: 352.
- Yanagisawa M, Liour SS, Yu RK. Involvement of gangliosides in proliferation of immortalized neural progenitor cells. *J Neurochem* 2004; 91: 804–812.
- Higashi H, Chen NH. Ganglioside/protein kinase signals triggering cytoskeletal actin reorganization. *Glycoconj J* 2004; 20: 49–58.
- Li R, Manela J, Kong Y, Ladisch S. Cellular gangliosides promote growth factor-induced proliferation of fibroblasts. *J*

- Biol Chem 2000; 275: 34213–34223.
10. Tessitore A, del P Martin M, Sano R, Ma Y, Mann L, Ingrassia A, et al. GM1-ganglioside-mediated activation of the unfolded protein response causes neuronal death in a neurodegenerative gangliosidosis. *Mol Cell* 2004; 15: 753–766.
 11. Hanson M, Lupski JR, Hicks J, Metry D. Association of dermal melanocytosis with lysosomal storage disease: clinical features and hypotheses regarding pathogenesis. *Arch Dermatol* 2003; 139: 916–920.
 12. Ledeen RW, Wu G. Ganglioside function in calcium homeo–stasis and signaling. *Neurochem Res* 2002; 27: 637–647.
 13. Nishio M, Fukumoto S, Furukawa K, Ichimura A, Miyazaki H, Kusunoki S, et al. Overexpressed GM1 suppresses nerve growth factor (NGF) signals by modulating the intracellular localization of NGF receptors and membrane fluidity in PC12 cells. *J Biol Chem* 2004; 279: 33368–33378.
 14. Mutoh T, Tokuda A, Miyadai T, Hamaguchi M, Fujiki N. Ganglioside GM1 binds to the Trk protein and regulates receptor function. *Proc Natl Acad Sci USA* 1995; 92: 5087–5091.