

Flow Cytometry-based Detection of B-cell Lymphoproliferative Disorders in Patients with Mycosis Fungoides

Shamir GELLER^{1#}, Sigi KAY^{2#}, Eran ELLENBOGEN¹, Tomer GOLDSMITH¹, Shoshi BAR-ON², Emily WARSHAUER¹, Varda DEUTSCH², Eli SPRECHER^{1,3}, Chava PERRY² and Ilan GOLDBERG¹

¹Department of Dermatology and ²Department of Hematology, Tel Aviv Sourasky Medical Center, and ³Department of Human Molecular Genetics & Biochemistry, Sackler Faculty of Medicine, Tel Aviv University, 6 Weizmann St., Tel Aviv, Israel. E-mail: shamirg@smile.net.il
#These authors contributed equally.

Accepted May 11, 2020; Epub ahead of print May 18, 2020

Patients with cutaneous T-cell lymphoma (CTCL) have an increased risk for developing second malignancies (1–3). In both population-based and clinic-based data, a significantly increased risk of developing a second primary lymphoma (Hodgkin disease or non-Hodgkin lymphoma (NHL)) was observed in patients with mycosis fungoides (MF) or Sézary syndrome (SS) (4). The contemporaneous occurrence of MF and B-cell malignancy supports the concept that an association exists between the 2 diseases, and it has been suggested that having either disease may predispose a patient to the other (5, 6). Chronic lymphocytic leukaemia (CLL) is a low-grade lymphoproliferative malignancy with clonal expansion of B cells that is included in the NHL family. A large population-based study recently investigated the incidence of CTCL in patients with NHL and CLL and found a greater risk of CTCL in men with CLL and in both men and women with NHL than in the general population (7). We report here 4 cases of B-cell lymphoproliferative disorders that were detected by flow cytometry analysis during the staging of discordant MF.

CASE REPORTS

We describe 2 cases of monoclonal B-cell lymphoproliferative disorder and 2 cases of CLL, which were detected on peripheral blood flow cytometry performed as part of routine staging of newly diagnosed MF. The 4 cases were diagnosed during a period of 10 years and comprised 3% of all blood flow studies performed during this period in patients with MF at the cutaneous lymphoma clinic, Tel Aviv Sourasky medical centre.

Case 1. A 61-year-old man was referred for evaluation of a non-pruritic rash that initially involved the abdomen and later progressed to the back and limbs. A skin biopsy showed histopathological findings consistent with patch-stage MF. Peripheral blood smear showed a minority of atypical lymphocytes with no Sézary cells. The patient's blood was sent for flow cytometry analysis that revealed normal T-cell population with an aberrant monoclonal lymphoid B-cell population comprising 8% of all peripheral blood white blood cells (WBC). This population stained positive for CD19, kappa chain, and FMC7, and was negative for CD5, CD10, CD23, and lambda chain (Fig. 1A, B). A PCR-based molecular assays revealed polyclonality of the peripheral blood T-cell population and monoclonal population of B cells. Bone marrow aspiration and biopsy excluded involvement of the marrow. Positron emission tomography-computed tomography (PET-CT) with 18F-fluorodeoxyglucose (FDG) showed no pathological uptake. In conclusion, this patient had early-stage MF (stage IB) coexisting with a monoclonal B-cell lymphoproliferative disorder.

Case 2. An 86-year-old woman developed a widespread erythema on her trunk, buttocks and lower extremities compatible

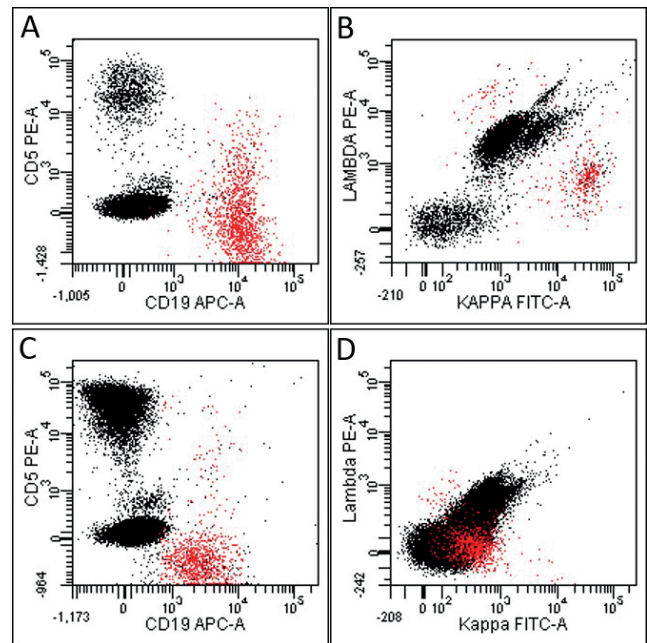


Fig. 1. Flow cytometric scatter plots of peripheral blood showing B-cell lymphoproliferative disorder in 2 patients with mycosis fungoides. In case 1, the aberrant CD19⁺ CD5⁻ population (marked in red) comprised 8% of the peripheral blood white blood cells (WBC) (A) and displayed kappa monoclonality (B). In case 2, the aberrant CD19⁺ CD5⁻ population (marked in red) comprised 2.5% of the WBC (C) with kappa monoclonality (D).

with erythroderma. Skin biopsy showed histopathological features suggestive of MF. Complete blood count revealed minimal lymphocytosis and no cytopaenia. No Sézary cells were found on peripheral blood smear. Flow cytometry on peripheral blood revealed normal T-cell population with no increase in CD4/8 ratio, CD4⁺/CD7⁻ or CD4⁺/CD26⁻ populations. A monoclonal B lymphocyte population that expressed CD19 and CD20, negative for CD5, CD23, and CD10, which constituted 2.5% of peripheral blood cells, was identified (Fig. 1C, D). PCR-based assays of the peripheral blood for IgH and TCR gene-rearrangements showed monoclonality of B cells and polyclonality for T cells. Bone marrow biopsy excluded marrow involvement by MF or B-cell lymphoproliferative disorder. PET-CT revealed a pathologic uptake in bilateral axillary and inguinal nodes, 1-cm in diameter and a subsequent ultrasonography showed enlarged axillary lymph nodes with a thickened cortex. Biopsy of a lymph node was performed revealing findings compatible with reactive changes. The patient was diagnosed with erythrodermic MF (stage IIIA) coexisting with a monoclonal B-cell lymphoproliferative disorder.

Case 3. A 59-year-old woman presented with a pruritic rash distributed over the lateral aspects of her back and axilla with findings compatible with early-stage MF histopathologically.

Blood smear showed 2% atypical lymphocytes and no Sézary cells. Peripheral blood was analysed by flow cytometry, showing normal T-cell population and an aberrant monoclonal B-cell population that comprised 43% of all WBC and stained positive for CD19, CD20, CD5, CD23 and surface λ light chain (Fig. S1A, B¹). PET-CT showed low intensity FDG uptake in lower cervical nodes, as well as in axillary and supraclavicular nodes. Biopsy of a cervical lymph node showed involvement by small lymphocytic lymphoma (SLL) with cells staining positive for CD20, CD79a, CD23, CD5, Bcl2, and Ki67 (15%) and negative for CD3, cyclin D1, CD10 and Bcl6. The diagnosis was compatible with MF (stage IA) coexisting with CLL.

Case 4. A 62-year-old man was referred to us due to a rash on his flanks lasting 2 years. The patient had past exposure to radioactive fallout at Chernobyl. A skin biopsy showed features compatible with folliculotropic MF. Blood counts were normal and no Sézary cells were evident in the peripheral blood. Ultrasonography revealed a 2.2-cm left inguinal node and 1.9-cm node in the left cervical region, with no intra-abdominal lymphadenopathy or hepatosplenomegaly. PET-CT did not show any pathological FDG uptake and the lymph node enlargement seemed to resolve. Furthermore, repeated imaging tests did not show large lymph nodes. Flow cytometry revealed that 22% of the WBC expressed CD20, CD19, CD5, CD23 and surface λ light chain (Fig. S1C, D¹). Bone marrow biopsy was compatible with bone marrow infiltration by small B-lymphocytes with immunophenotype features SLL/CLL and repeated peripheral WBC showed leukocytosis of 18,000/ μ l with total lymphocyte count of 11,000/ μ l. A diagnosis of folliculotropic MF (stage IB) and SLL/CLL was made.

DISCUSSION

An association between CTCL and B-cell lymphomas has been described previously, as well as simultaneous diagnosis of both MF/SS and a B-cell lymphoma (6, 8). The presence of a population of B cells with characteristics of CLL in the peripheral blood of patients with cutaneous T-cell disorders have been described and it was speculated that the presence of a monoclonal B-cell population in these patients is either due to a reactive process possibly conferring some protective effect, or a response to an unknown stimulus produced by the T cells (9). Other hypotheses have been presented to explain this association, such as that both abnormal population come from a common stem cell progenitor or genetic events, occur secondary to the same carcinogen or virus, occur due to the alteration in the immune system due to one malignancy, or occur by coincidence (7, 10). In a previous study, it was noted that patients with CLL and concurrent CTCL appeared to have worse survival than patients with a prior CLL (median survival, 12 versus 47 months). It has been suggested that behaviour of CTCL in these patients might be more aggressive due to the immunosuppression associated with CLL and therefore management of CTCL may need to be adjusted in the setting of CLL (8). Our patient with erythrodermic MF and a monoclonal B-cell lymphoproliferative disorder (Case 2) had an aggressive course of disease and the patient died within 3 years of

her diagnosis. The other 3 patients in our case-series who had MF and a discordant diagnosis of monoclonal B-cell lymphoproliferative disorder or CLL have an indolent disease with prolonged complete remission in one case and stable disease in the other two patients.

Flow cytometry has become the preferred method to measure blood involvement in MF/SS, replacing manual Sézary counts in many institutions. With the steadily growing use of flow cytometry for the evaluation of blood involvement in patient with MF/SS regardless of disease stage, an increase in the diagnosis of discordant lymphoproliferative disorders is seen, as demonstrated in our reported case-series herein. The detection of more cases with similar simultaneous diagnoses of MF/SS and B-cell lymphoma may allow to better understand the aetiological and prognostic aspects of discordant lymphomas in CTCL, which might influence the management of these patients.

In conclusion, performing blood flow cytometry analysis using a combined panel of T- and B-cell markers should be considered in patients with MF/SS regardless of disease stage for the detection of discordant lymphoproliferative disorder, specifically in cases that present with blood abnormalities or lymph node enlargement.

REFERENCES

1. Brownell I, Etzel CJ, Yang DJ, Taylor SH, Duvic M. Increased malignancy risk in the cutaneous T-cell lymphoma patient population. *Clin Lymphoma Myeloma* 2008; 8: 100-105.
2. Goyal A, O'Leary D, Goyal K, Rubin N, Bohjanen K, Hordinsky M, et al. Increased risk of second primary hematologic and solid malignancies in patients with mycosis fungoides: a surveillance, epidemiology, and end results analysis. *J Am Acad Dermatol* 2019 Jul 30. pii: S0190-9622(19)32466-1.
3. Amber KT, Bloom R, Nouri K. Second primary malignancies in CTCL patients from 1992 to 2011: a SEER-based, population-based study evaluating time from CTCL diagnosis, age, sex, stage, and CD30+ subtype. *Am J Clin Dermatol* 2016; 17: 71-77.
4. Huang KP, Weinstock MA, Clarke CA, McMillan A, Hoppe RT, Kim YH. Second lymphomas and other malignant neoplasms in patients with mycosis fungoides and Sézary syndrome: evidence from population-based and clinical cohorts. *Arch Dermatol* 2007; 143: 45-50.
5. Barzilai A, Trau H, David M, Feinmesser M, Bergman R, Shpiro D, et al. Mycosis fungoides associated with B-cell malignancies. *Br J Dermatol* 2006; 155: 379-386.
6. Herro E, Dicaudo DJ, Davis MDP, Weaver AL, Swanson DL. Review of contemporaneous mycosis fungoides and B-cell malignancy at Mayo Clinic. *J Am Acad Dermatol* 2009; 61: 271-275.
7. Chang TW, Weaver AL, Shanafelt TD, Habermann TM, Wriston CC, Cerhan JR, Call TG, et al. Risk of cutaneous T-cell lymphoma in patients with chronic lymphocytic leukemia and other subtypes of non-Hodgkin lymphoma. *Int J Dermatol* 2017; 56: 1125-1129.
8. Chang MB, Weaver AL, Brewer JD. Cutaneous T-cell lymphoma in patients with chronic lymphocytic leukemia: clinical characteristics, temporal relationships, and survival data in a series of 14 patients at Mayo Clinic. *Int J Dermatol* 2014; 53: 966-970.
9. Daenen S, van Voorst Vader PC, Blom N, Pietens J, Hollema H, Smit JW. Clonal chronic lymphocytic leukaemia-like B lymphocytes in the blood of patients with cutaneous T-cell disorders. *Br J Haematol* 1993; 85: 307-312.
10. Volk AL, Vannucci SA, Cook W, Thompson KA, Listinsky CM. Composite mycosis fungoides and B-cell chronic lymphocytic leukemia. *Ann Diagn Pathol* 2002; 6: 172-182.

¹<https://www.medicaljournals.se/acta/content/abstract/10.2340/00015555-3517>

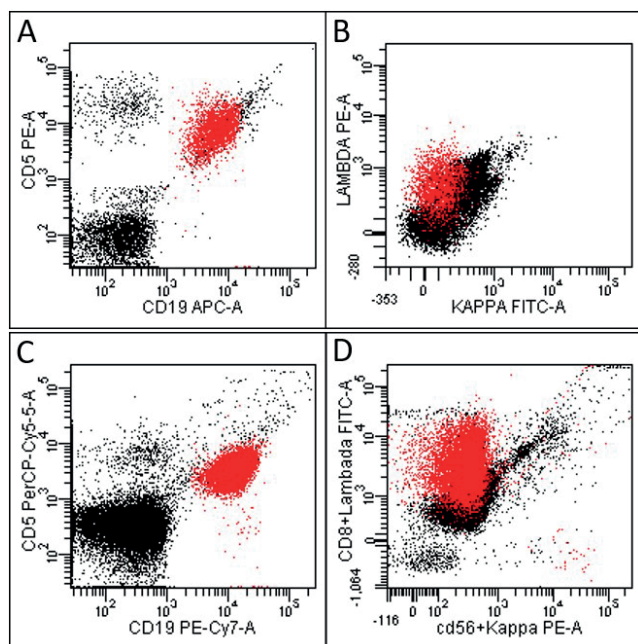


Fig. S1. Flow cytometric scatter plots of peripheral blood showing chronic lymphocytic leukemia (CLL) in 2 patients with mycosis fungoides. In case 3, the aberrant CD19⁺ CD5⁺ population (marked in red) comprised 43% of the peripheral blood WBC (A) and displayed lambda monoclonality (B). In case 4, the aberrant CD19⁺ CD5⁺ population (marked in red) comprised 22% of the WBC (C) and displayed lambda monoclonality (D).