

INCONTINENTIA PIGMENTI IN A NEWBORN BOY

GUNNAR PALLISGAARD

Bloch in 1926 (4) and Sulzberger in 1928 (17) called attention to a congenital pigmental anomaly which they termed incontinentia pigmenti. More than 200 cases of the disease have since been reported in the literature. In 1947 and 1953, Asboe-Hansen (1, 2) described the initial phase of this condition as a "bullous, keratogenous and pigmentary dermatitis with eosinophilia in newborn girls". The disease is hereditary, but its mode of transmission is not fully clarified. The responsible gene is presumably linked to the X-chromosome, since the majority of cases have been encountered in females (6, 11, 12, 13). The disease is presumably due to a lesion of the neural crest, which may give rise to various congenital anomalies. It is thus often associated with malformations of the bones, teeth, sensory organs and the central nervous system. Such malformations are occasionally seen in other members of the family without any signs of skin disorders (3). In 1966, Curth (5) collected 216 cases of the disease from the literature, of which only 12 had occurred in males. Since then, 14 additional cases, all occurring in females, have been published (7, 8, 9, 10, 14, 15, 16, 18). A case of incontinentia pigmenti seen in a 5-month-old boy is presented below.

Case Report

The boy was the youngest of three children. The first child was a boy born be-

fore the mother married; the second was a girl by the same father as the patient. Congenital malformations and skin affections were absent in the two siblings. The mother suffered from a congenital hearing defect which had resulted in complete deafness. The father was also completely deaf, referable to purulent meningitis at the age of about 12 months. It was stated that the maternal grandmother had suffered from epilepsy, and a maternal uncle and aunt from nocturnal enuresis. The mother was a dizygotic twin. The twin sister was in good health.

The pregnancy and delivery had been normal. At birth, the skin of the patient had been perfectly normal, but a few minutes later the midwife and doctor observed the development of up to pea-sized vesicles on the back of both feet. During the next half hour, more vesicles developed, and the patient was therefore sent to a dermatologist, who observed crackling and fissure formation in the pale, apparently macerated skin of the feet. The fissures were 3-4 mm wide with a few vesicles; some of these had burst and had formed crusts of dried secretion. The fissures ran in zigzag manner longitudinally on the back of the feet. The patient was sent back home with an indifferent ointment and was seen twice by the dermatologist before the age of 5 months. At the age of 2 months, the skin affection had spread proximally on all extremities, now consisting of verrucous

This study was supported by a grant from Aage Bang's Foundation.

Department of Medicine C, Odense County and City Hospital, Odense, Denmark.

Head: P. Horstmann

Dermatologist: Dr. R. Wehnert

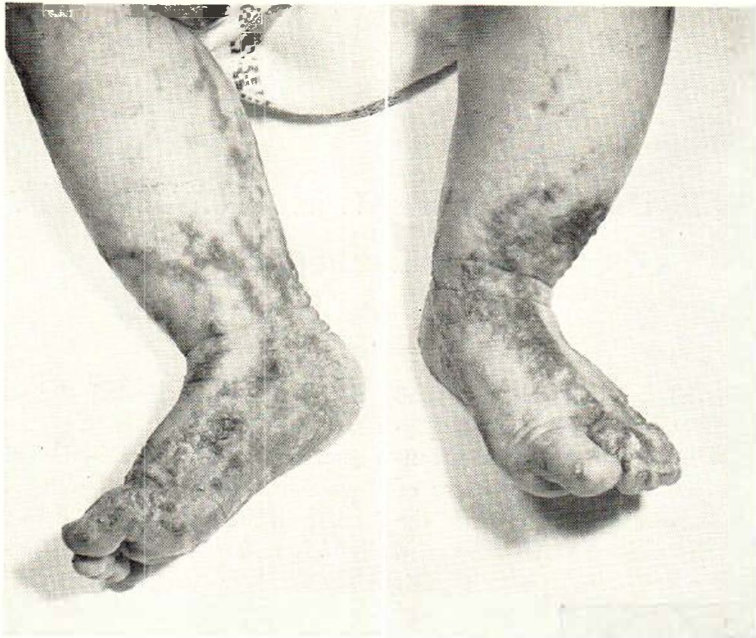

Fig. 1. Pigmented hyperkeratoses at the age of 5 months.

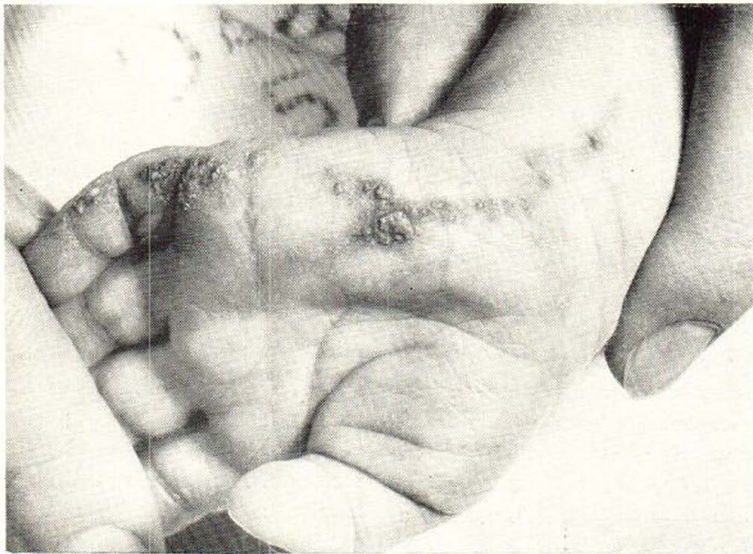

Fig. 2. Pigmented hyperkeratoses at the age of 5 months.

hyperkeratoses running in irregular streaks longitudinally on the extremities. The distribution of the affection was symmetrical, and a few vesicles were still present. At the age of 5 months, the patient was admitted to our department for further investigation.

On admission, no vesicles were present, but the verrucous streaks of keratoses had spread further (figs. 1 and 2). During a follow-up admission at the age of 12 months, some of the keratoses had subsided, but others had developed proximal

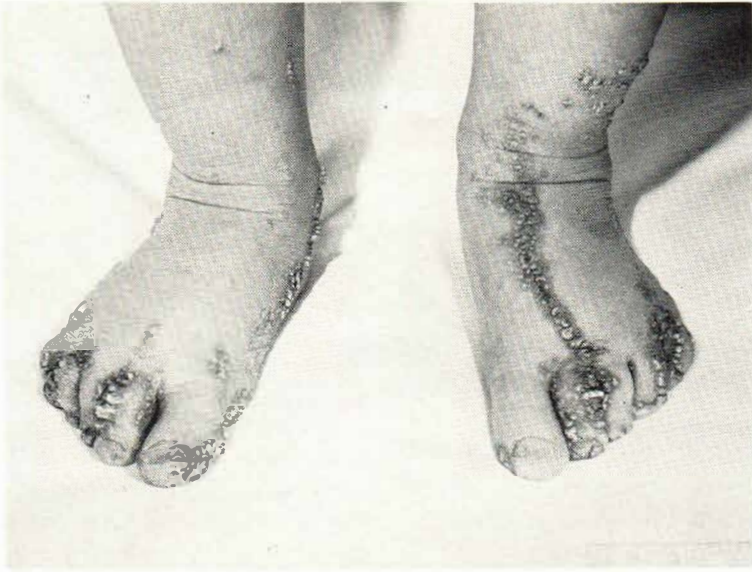

Fig. 3. Pigmented hyperkeratoses at the age of 2 years.

to those originally present. In the right popliteal and gluteal regions, weakly pigmented spots and streaks without infiltration were noticed, and in the skin of the posterior crural regions there were spots and streaks of reddish brown pigment at the level of the skin proximally, but with verrucous infiltrations peripherally. On renewed follow-up examination at the age of 2 years, the distribution of the lesions was practically unchanged, but the verrucous hyperkeratoses had become more prominent and had assumed a more pronounced greyish black pigmentation (fig. 3).

Clinical and laboratory investigations.—Physical examination did not reveal any malformations. At 5 months, 19,800 leucocytes with 7% eosinophilic cells, 12,600 leucocytes with 5% eosinophils were found. At 12 months, 9600 leucocytes with 2% eosinophils were observed. At 2 years, 8400 leucocytes with 19% eosinophils were counted. The Wassermann reaction was negative. Radiography of the chest, hands, feet, lower extremities and skull showed normal conditions. ECG was normal. Neurological examination, including

EEG, and ophthalmological examination showed normal conditions. Otological examination revealed normal hearing organs and normal hearing.

Histological examination of a biopsy specimen of hyperkeratotic skin removed from the external femoral region showed distinct thickening of the corneum with parakeratosis and pronounced hydropic degeneration. In close contact with the basal layer there were groups of lymphocytes and melanophores, and minute particles of free melanotic pigment were seen in the connective tissue (figs. 4 and 5). The changes observed corresponded to those of the second stage of *incontinentia pigmenti*.¹ A biopsy specimen removed at the age of 12 months showed similar changes.

Chromosome analysis revealed no Barr-positive cells. The number of chromosomes was that normally present in boys, and no chromosomal anomalies were disclosed.²

Discussion

The course of the disease was similar to that described by Asboe-Hansen (2, 3).

¹ Histology by Dr. B. Heilesen, Copenhagen.

² Chromosome analysis: Jan Mohr and Schultz-Larsen, Copenhagen.

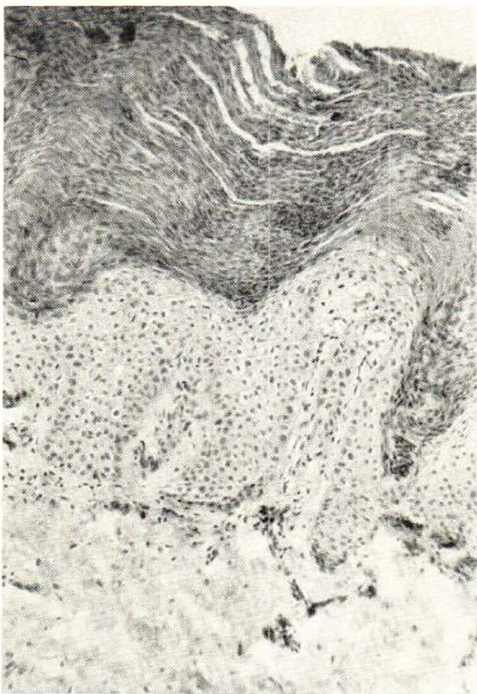


Fig. 4. General low-power view of the biopsy specimen.

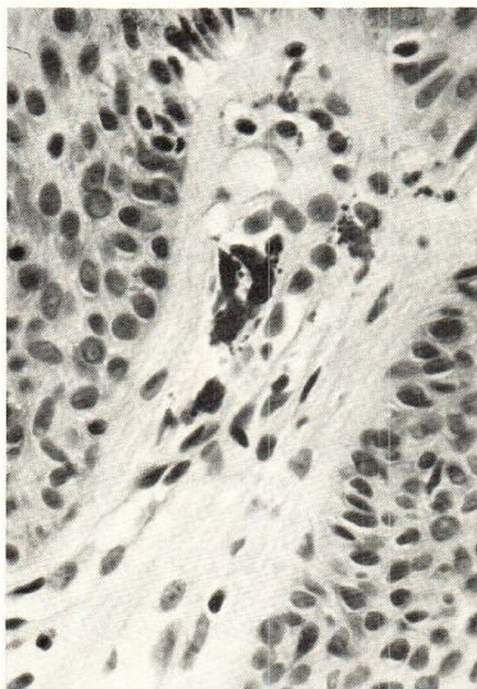


Fig. 5. Melanophores and free pigment.

Unfortunately, the blood was not studied for eosinophilic cells until the patient was 5 months old, and at that time only slight eosinophilia was present; but at the age of 2 years the patient had 19% eosinophils. No malformations were disclosed in the patient, but the mother had a congenital hearing defect which had resulted in total hearing loss. This finding is not surprising, since it is known that the developmental anomaly in members of the family may manifest itself in localities other than the skin (3, 5). Curth (5, 6) also performed chromosome analysis in a boy with incontinentia pigmenti. As in the present case, the chromosome complement was found to be normal. The disease has been described in boys only in rare cases, but the fact that it may occur in males makes it desirable that as many cases of incontinentia pigmenti as possible are published in order to provide more extensive material for genetic studies.

SUMMARY

A case of incontinentia pigmenti in a 5-month-old boy is reported. The mother suffered from total hearing loss referable to a congenital hearing defect. The chromosome complement of the patient was normal. By now, 231 cases of the disease have been published, including 13 occurring in boys.

REFERENCES

1. Asboe-Hansen, G.: Dühring's herpetiform dermatitis in children. Two cases in newborn infants. (Dermatitis herpetiformis Dühring hos børn. To tilfælde hos nyfødte.) *Ugeskr. læg.* 109: 222, 1947.
2. Asboe-Hansen, G.: Bullous keratogenous and pigmentary dermatitis with blood eosinophilia in newborn girls. Report of four cases. *Arch. Derm. Syph. (Chic.)* 67: 152, 1953.
3. Asboe-Hansen, G.: Bullous keratogenous and pigmentary dermatitis with blood eosinophilia in girls ("incontinentia pigmenti"). *Acta derm.-venereol. Sven. Hellsenström 65 years (Stockh.)* 3, 1966.

4. Bloch, B.: Eigentümliche bisher nicht beschriebene Pigmentaffektion (Incontinentia pigmenti). *Schweiz. med. Wschr.* 7: 404, 1926.
5. Curth, H. O.: *Handbuch der Haut- und Geschlechtskrankheiten VII, Genetik der mit Pigmentstörungen einhergehenden Dermatosen (17): Incontinentia pigmenti*, p. 813. Springer-Verlag, Berlin-Heidelberg-New York, 1966.
6. Curth, H. O. and Warburton, D.: The genetics of incontinentia pigmenti. *Arch. Dermat.* 92: 229, 1965.
7. Gilje, O.: Congenital and hereditary skin disorders seen in Korea (incontinentia pigmenti). *Proc. Fenno-Scand. Ass. Derm.* 18, 1965.
8. Hartman, D. L.: Incontinentia pigmenti associated with subungual tumors. *Arch. Dermat.* 94: 632, 1966.
9. Junaid, A. J.: A case of incontinentia pigmenti. *Dermatologica* 133: 393, 1966.
10. Jørgensen, B. L.: Incontinentia pigmenti in new-born girls. *Proc. Fenno-Scand. Ass. Derm.* 32, 1965.
11. Lenz, W.: Zur Genetik der Incontinentia pigmenti. *Ann. paediat.* 196: 149, 1961.
12. McKusick, V. A.: Medical genetics 1961. *J. chron. Dis.* 15: 533, 1962.
13. Pfeiffer, R. A.: Zur Frage der Vererbung der Incontinentia pigmenti Bloch-Siemens. *Z. menschl. Vererb.- u. Konstit.-Lehre* 35: 496, 1960.
14. Reed, W. B., Carter, C. and Cohen, T. M.: Incontinentia pigmenti. *Dermatologica* 134: 243, 1967.
15. Rehtijärvi, K., Dammert, K., Vilkki, J., Niemi, K.-M. and Kuokkanen, K.: Dermatological meetings 1965, Reports of cases of particular interest, University of Oulu. *Acta dermat.-venereol.* 47: 131, 1967.
16. Storck, H., Schwarz, K., Cavegn, I. et al.: Aus der Dermatologischen Universitätsklinik Zürich. *Dermatologica* 133: 131, 1966.
17. Sulzberger, M. B.: Über eine bisher nicht beschriebene congenitale Pigmentanomalie (Incontinentia pigmenti). *Arch. Derm. Syph. (Berl.)* 154: 19, 1928.
18. Wolf-Jürgensen, P.: Eosinophils and histamine in Asboe-Hansen's disease (incontinentia pigmenti), Studies with the skin window technique. *Acta dermat.-venereol.* 46: 500, 1966.

Received: June 6, 1968.

Author's address:

Gunnar Pallisgaard
 Kløvervænget 24 A
 5000 Odense, Denmark.