

## DEMONSTRATION OF FIBRIN IN SKIN DISEASES

### I. *Lichen ruber planus* and *Lupus erythematosus*

O. P. Salo, Th. Tallberg and K. K. Mustakallio

*From the Department of Dermatology, University Central Hospital, and the Department of Serology and Bacteriology, University of Helsinki, Helsinki, Finland*

**Abstract.** Biopsies from the skin lesions of 35 patients with lichen ruber planus and 20 patients with lupus erythematosus were studied for the presence of fibrin. The immunofluorescence examination was performed using FITC-labelled anti-fibrinogen globulin which was prepared by immunization of rabbits with immunologically purified fibrinogen. Fibrin accumulations along the dermo-epidermal junction were found in 25 and 9 of the patients with lichen ruber planus and lupus erythematosus, respectively.

Deposition of fibrin has been observed in the lesions of a variety of inflammatory dermatoses (12, 14). The accumulation of fibrin in the tips of dermal papillae has been established as a characteristic feature of dermatitis herpetiformis (4, 5, 8, 9, 13). In early lesions of dermatitis herpetiformis, fibrin can often be seen even before neutrophils and eosinophils (the main cellular elements forming the microabscesses) have been extravasated (8, 13). Experimental inflammation in animals and in humans has documented the importance of extravascular fibrinogen, fibrin, and fibrin degradation products for the granulocytic phase of inflammation (2). Immunofluorescent and electronmicroscopical studies have shown that eosinophils release profibrinolysin (10), while neutrophils phagocytize and digest fibrin (11).

The epidermis contains inhibitors of fibrinolysis which are released by epidermal injury (15, 16). Liquefaction degeneration is a result of one type of epidermal injury, which according to Montgomery (7) is, at least in lichen ruber planus and in lupus erythematosus, secondary to the inflammatory process in the uppermost dermis. In this paper we report the demonstration of fibrin in the skin lesions of these two diseases.

### MATERIAL AND METHODS

The patient series comprised 35 patients with lichen ruber planus and 20 patients with lupus erythematosus.

Of the 35 patients with lichen ruber planus, 20 were men and 15 women. The age of the male patients varied from 11 to 67 years with a mean of 45.5 years and that of the female patients varied from 7 to 64 years with a mean of 38.6 years. The duration of the disease before the examination varied in general from 1 to 12 months, but in 3 male patients the disease had lasted for 3 years, and in 1 for 5 years. At the time of the examination, all patients had a clinically typical active disease showing, histologically, hyperkeratosis, prominent granular layer, saw-toothed appearing acanthosis, liquefaction degeneration of the basal layer, and a band-like inflammatory infiltration in the upper dermis.

Of the 20 patients with lupus erythematosus 16 (13 females and 3 males) had clinically and histologically typical discoid lesions. Liquefaction degeneration of basal cells was present in every case. Three female patients had systemic lupus erythematosus with skin lesions which were histologically typical. One female patient had lupus erythematosus profundus with typical deep inflammatory infiltrate without definite epidermal changes. All 20 patients showed granular deposits of immunoglobulins at the dermo-epidermal junction of the skin lesions and the 3 patients with SLE also in the clinically uninvolved skin.

Preparation of the antifibrinogen conjugate is presented in Fig. 1. The monospecific anti-fibrinogen serum obtained in the first system was used to prepare an anti-fibrinogen immunosorbent according to Avrameas & Ternynck (1). This immunosorbent was then used for the immunological purification of the biochemically pure fibrinogen for the immunization of other rabbits in the second system. The second immunization resulted in an anti-fibrinogen antiserum which reacted very weakly with normal human serum, and 4 mg/ml of lyophilized normal human serum (NHS) was sufficient to absorb all the antibodies reacting with normal human serum components. The immunofluorescence titre of the monospecific anti-fibrinogen conjugate varied in different batches between 1:8 and 1:32. The F/P ratio of the conjugate varied in different batches between 2.0 and 4.0. The im-

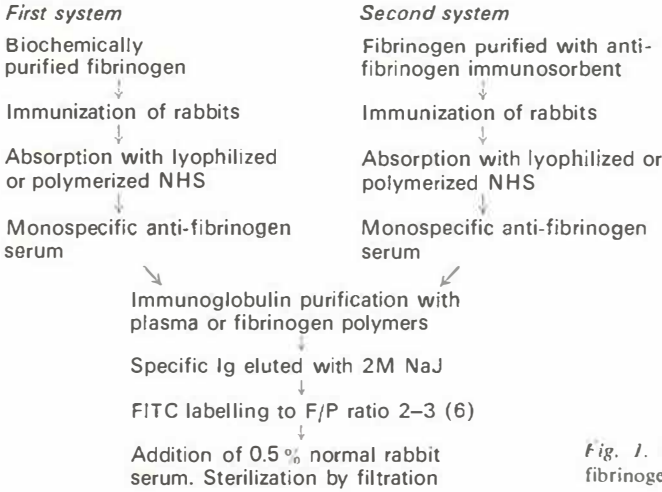


Fig. 1. Preparation of FITC-labelled monospecific anti-fibrinogen immunoglobulins.

munofluorescence staining could be blocked in the tissues by previous incubation with unconjugated antifibrinogen antiglobulin and could be absorbed with fibrinogen or plasma polymers.

The biopsies from the skin lesions were immediately frozen and sectioned in a cryostat at 4  $\mu$ . The sections were washed for 30 min in phosphate-buffered saline (PBS) and after washing, were covered with the anti-fibrinogen conjugate and incubated at room temperature in a moist chamber for 30 min. Thereafter, the sections were again washed in PBS for 30 min to remove all unreacted conjugate, mounted in glycerin, and examined. Microscopy was performed with a Leitz Orthoplan fluorescence microscope using incident illumination, Xenon light source, AL 495 exciter and OG 510 barrier filters.

**RESULTS**

In lichen ruber planus, fibrin deposits in the dermo-epidermal junction could be demonstrated in 25 of the 35 cases. The fibrin accumulation

was sharply demarcated against the epidermal side but extended as strands of different length to the uppermost layer of the dermis (Fig. 2). Accumulation of fibrin in the walls of the papillary capillaries was demonstrable only when there was also fibrin accumulation in the dermo-epidermal junction.

In seven of the 16 cases of discoid lupus erythematosus fibrin was present in the dermo-epidermal junction. The distribution of fibrin in the tissue was similar to that seen in lichen ruber planus (Fig. 3). In only one case were the walls of the papillary capillaries also stained.

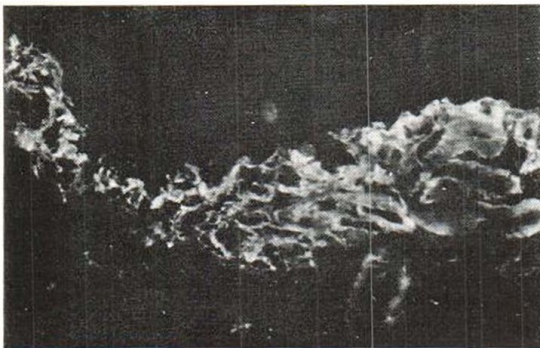


Fig. 2. Accumulation of fibrin in the lesion of lichen ruber planus. Capillary walls are also stained.

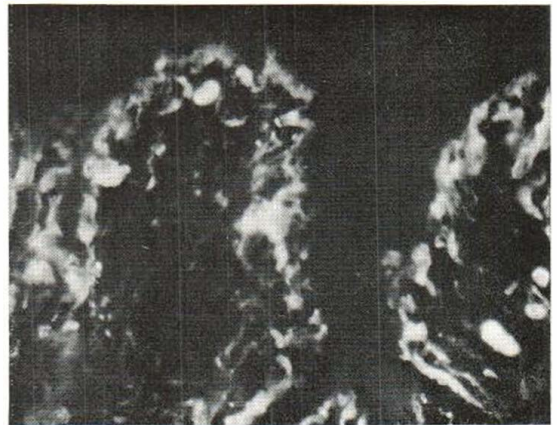


Fig. 3. Accumulation of fibrin in the dermo-epidermal junction in discoid lupus erythematosus. The area of fibrin accumulation is sharply demarcated towards epidermis and fibrin strands of different length extend to the upper dermis.

Of the 3 patients with systemic lupus erythematosus, 2 exhibited a strong accumulation of fibrin in the dermo-epidermal junction. The pattern of the fibrin distribution in these cases was similar to that seen in the discoid type of the disease. In both these cases, normal histology revealed a clear-cut liquefaction degeneration of the basal layer which was not seen in the third case with no fibrin deposition in the dermo-epidermal junction. This patient was a girl of thirteen who for 2 months had had butterfly eruption on her cheeks and nose. In one case, fibrin was also present in the walls of papillary capillaries.

No fibrin could be demonstrated in the skin lesions of the patient with lupus erythematosus profundus.

### DISCUSSION

The present result concerning the occurrence of fibrin in the dermo-epidermal junction of the lesions of lichen ruber planus corroborates the earlier findings of Barthelmes & Haustein (3). This accumulation of fibrin in the dermo-epidermal junction also occurs in about half of the patients with systemic or discoid lupus erythematosus. In both these diseases, liquefaction degeneration of the basal layer is a characteristic feature. According to Montgomery (7), the cellular infiltrate in the early lesions of lichen ruber planus is composed of polymorphonuclear leukocytes, but in the fully developed lesions it is chiefly lymphocytic. The liquefaction degeneration results mainly from invasion of the epidermis by inflammatory cells. In lupus erythematosus the liquefaction degeneration is more dependent on lymphedema together with some vacuolation of cells in the basal layer. Further, he emphasizes that "The earliest pathologic changes in lupus erythematosus consist of dilatation of blood and lymph vessels in the upper part of the cutis with edema of the walls of the vessels and extravasation of leukocytes and later lymphocytes and monocytes."

It is possible that, in the earliest stage of the lesion, fibrinolytic activity is normal. The chemotactic activity of fibrin and its degradation product takes part in the formation of the inflammatory infiltrate which in turn contributes to the liquefaction degeneration. Turner et al. (15, 16) have shown that epidermis contains in-

hibitors of fibrinolysis which can be released by epidermal injury. If the liquefaction degeneration caused by dermal changes is considered sufficient epidermal injury to be able to release the inhibitors, it is logical that fibrin accumulates in the dermo-epidermal junction in lichen ruber planus and lupus erythematosus.

Ryan et al. (12) divide the inflammatory process into two types. Type I is characterized by lack of impairment of fibrinolysis and of fibrin deposition, Type II by deposition of fibrin in the tissue and impaired tissue fibrinolysis. On the basis of the presence of fibrin deposits in the skin lesions of lichen ruber planus and lupus erythematosus, it is possible that the Type II mechanism operates at least in some stage of these diseases. Ryan's remark (12) that there may be impaired fibrinolytic activity in the lesions of lichen ruber planus speaks in favour of this assumption.

### ACKNOWLEDGEMENT

Aided by a grant from the Medical Research Council in Finland.

### REFERENCES

1. Avrameas, S. & Ternynck, T. J.: Biologically active water-insoluble protein polymers I. Their use for isolation of antigens and antibodies. *J Biol Chem* 242: 1651, 1967.
2. Barnhart, M. I.: Role of blood coagulation in acute inflammation *Biochem Pharmacol* 17: Suppl. p. 205, 1968.
3. Barthelmes, H. & Haustein, U. F.: Nachweis von Fibrinablagerungen beim Lichen ruber planus mit Hilfe der Immunfluoreszenzhistologie. *Derm Monatschr* 156: 85, 1970.
4. Cormane, R. H. & Giannetti, A.: IgD in various dermatoses; immunofluorescence studies. *Brit J Derm* 84: 523, 1971.
5. Jakubowicz, K., Dabrowski, J. & Maciejewski, W.: Deposition of fibrin-like material in early lesions of dermatitis herpetiformis. *Ann Clin Res* 3: 34, 1971.
6. Linder, E. & Tallberg, Th.: Preparation of anti-IgG conjugates for immunofluorescence using immunoadsorbents for purification. *Ann Med Exp Fenn* 48: 212, 1970.
7. Montgomery, H.: *Dermatopathology*. Harper & Row, New York, 1967.
8. Mustakallio, K. K., Blomqvist, K. & Laiho, K.: Papillary deposition of fibrin, a characteristic of initial lesions of dermatitis herpetiformis. *Ann Clin Res* 2: 13, 1970.
9. Mustakallio, K. K., Blomqvist, K. & Salo, O. P.: Papillary fibrin in dermatitis herpetiformis. *Arch Belg Derm Syph* 26: 441, 1970.

10. Riddle, J. M. & Barnhart, M. I.: The eosinophil as a source for profibrinolysin in acute inflammation. *Blood* 25: 776, 1965.
11. — Ultrastructural study of fibrin dissolution via emigrated polymorphonuclear neutrophils. *Amer J Path* 45: 805, 1964.
12. Ryan, T. J., Nishioka, K. & Dawber, R. P. R.: Epithelial-endothelial interaction in the control of inflammation through fibrinolysis. *Brit J Derm* 84: 50, 1971.
13. Salo, O. P., Laiho, K., Blomqvist, K. & Mustakallio, K. K.: Papillary deposition of fibrin in iodide reactions in dermatitis herpetiformis. *Ann Clin Res* 2: 19, 1970.
14. Salo, O. P. & Mustakallio, K. K.: IF-demonstration of fibrin in different skin diseases. Paper read at the Meet Europ Soc Dermat Res. Noordwijk, Holland 1971.
15. Turner, R. H., Kurban, A. K. & Ryan, T. J.: Inhibition of fibrinolysis by human epidermis. *Nature* 223: 841, 1969.
16. — Fibrinolytic activity in human skin following epidermal injury. *J Invest Derm* 53: 458, 1969.

Received December 13, 1971

Osmo P. Salo, M.D.  
Department of Dermatology  
University Central Hospital  
Snellmanink. 14  
00170 Helsinki 17  
Finland