

7. Cram, D. L., Resneck, J. S. & Jackson, W. B.: A congenital ichthyosiform syndrome with deafness and keratitis. *Arch Dermatol* 115: 467, 1979.
8. Thomson, M. L. & Sutarman: The identification and enumeration of active sweat glands in man from plastic impressions of the skin. *Trans Roy Soc Trop Med Hyg* 47: 412, 1953.
9. Cremers, C. W. R. J., Philipsen, V. M. J. G. & Mali, J. W. H.: Deafness, ichthyosiform erythroderma, corneal involvement, photophobia and dental dysplasia. *J Laryngol Otol* 16: 585, 1977.
10. Milot, J. & Sheridan, S.: Corneal leucomas in ichthyosis. *J Pediatr Ophthalmol* 11: 209, 1974.
11. Eriksen, L. & Cormane, R. H.: Oral retinoic acid as therapy for congenital ichthyosiform erythroderma. *Br J Dermatol* 92: 343, 1975.

## Loiasis: A Case Report

B. J. Vermeer and H. J. van der Kaay

*Department of Dermatology and Parasitology,  
University Medical Centre, Leiden, The Netherlands*

Received June 6, 1981

Loiasis is one of the filaria infections which affect man, caused by a nematode worm, *loa loa*, endemic in the West and Central African rain forest area up to the Sudan (7). Humans are infected during the bloodsucking phase of the infectious mangrove fly (*Chrysops* spp.) (3). Infective larvae pierce the proboscis sheath of the fly and subsequently burrow through the skin of the mammal host, i.e. man. Development into an adult worm takes 3–18 months. However, already several months after the infection, the typically subcutaneous swellings may appear, most likely an allergic tissue response of the host to toxins from migrating adult worms. These swellings are well known as Calabar swellings and usually disappear within 2–3 days. The swellings, which can be located near or around joints of wrist, knee or ankle can give rise to local pain and restriction of mobility, suggestive of an acute arthritis. The passage of a worm beneath the conjunctiva causes swellings of the eyelids and the worm can even be observed by the patient (1, 6).

Besides these symptoms produced by the adult worm, a *loa loa* infection can go unnoticed, except for a chance laboratory finding indicating the presence of a (hyper)eosinophily. Loiasis imported

into the USA and Europe has been reported several times (2, 4, 8, 9, 10, 11).

We report here a patient with loiasis imported into the Netherlands and from which 2 adult worms could be surgically removed from the skin during therapy.

## CASE REPORT

A female patient, 27 years old, had returned to the Netherlands over six months ago after a one year stay in Nigeria. Shortly after her return she started to complain about fugitive swellings around her wrists and lower part of the arm. During the previous few weeks swellings of both eyelids also occurred. The swellings lasted several days. Blood examination revealed an eosinophily of  $2400 \times 10^6/l$ , no microfilariae were detectable. By using an antibody against microfilariae, a positive serum test was found. IFA 1:64. Diethylcarbamazine citrate (DEC) treatment was started, with a dosage gradually increasing from 1.0 mg to 6.0 mg/kg daily, which is equivalent to 0.5–3.0 mg DEC base/kg. Two days after the treatment was begun, two reddish oedematous swellings appeared, one on the left upper arm and one on the left upper leg. Both caused itching and, on inspection, indicated a worm-like swelling in the centre (Figs. 1, 2).

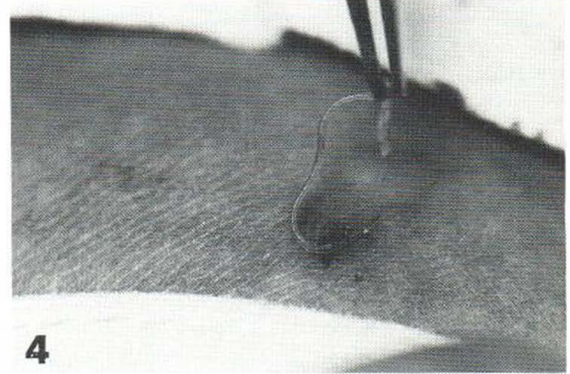
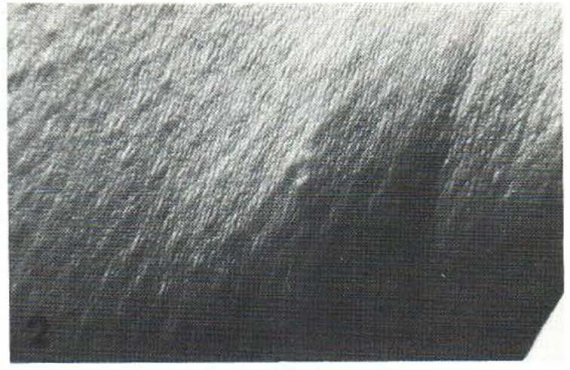
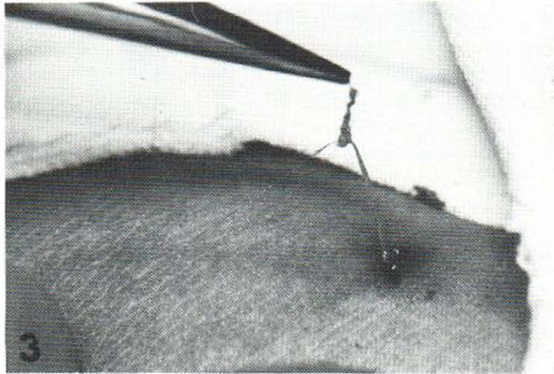

Through a small incision, the worms could be removed (Figs. 1–4). The treatment was completed in 3 weeks. The patient has since had no more complaints and can be considered cured.

## DISCUSSION

If a diagnosis of *loa-loa* infection is expected, the case history becomes an important piece of information. The endemic area is limited, and it is known that, while the infective larvae take many months to develop into adult worms, the latter can survive for many years, and cause the Calabar swellings. A presumptive diagnosis can be confirmed by the detection of microfilariae in peripheral blood, collected during the daytime. However, in a primary infection it may take several years before microfilariae can be found in the circulating blood. In patients without detectable microfilariae, one of the serological tests can be used (1).

When chemotherapy is indicated, diethylcarbamazine (Hetrazan<sup>®</sup>) is administered for 2–3 weeks. Therapy with DEC is started with an initial dose of 50 mg three times daily and each dose thereafter is increased by 50 mg until a total daily dose of 6 mg/kg of body weight is reached (5).

During the initial treatment with DEC one has to be alert for allergic reactions. To counteract these, it is advisable to give antihistamine or corticoster-



Figs. 1, 2. Reddish nodule, with a worm-like swelling in the centre, on the upper arm. Bar represents 1 cm.

Fig. 3. Removal of surrounding tissue.

Fig. 4. Removal of a worm from the nodule.

oids 20 mg/day as a precaution, one or two days before starting the treatment and to continue this during the first 4 days of treatment. Though DEC may also kill adult *loa-loa* worms, it is mainly active against the microfilariae. Repeated courses may be required to achieve a complete cure.

Because it is not possible to estimate the number of adult worms or wormload in an infection, it is important to remove surgically, under local anaesthesia, all adult worms, when they can be clearly located either during their migration, or when they appear during the course of an infection (5). The physician needs to be alert for worms appearing during the early days of treatment, when local reactions may reveal the site of an adult worm (Figs. 1 and 2). The case presented here is an example of such.

#### ACKNOWLEDGEMENT

We wish to thank J. J. W. Korff for expert technical assistance.

#### REFERENCES

- Adams, A. R. D. & Maegraith, B. G.: *Clinical Tropical Diseases*, 4th ed., 116 pp. Blackwell Scientific Publications, Oxford, 1966.
- Gibbs, R. D.: Loiasis: Report of three cases and literature review. *J Natl Med Ass* 71: 853, 1979.
- Gordon, R. M., Kershaw, W. E. & Creme, W.: The problem of loiasis in West Africa. *Trans R Soc Trop Med Hyg* 44: 11, 1950.
- Kazacos, K. & Smith, L. E.: Loiasis (loa-loa) in an African student in Indiana. *Am J Trop Med Hyg* 28: 213, 1979.
- Maegraith, B. G. & Gilles, H. M.: *Management and Treatment of Tropical Diseases*, 256 pp. Blackwell Scientific Publications, Oxford, 1971.
- Manson-Bahr, P. H. & Wilcocks, C.: *Manson's Tropical Diseases*, 16th ed., 691 pp. Baillière Tindall & Cassell Ltd, London, 1966.
- Ogunba, E. O.: Ecology of human loiasis in Nigeria. *Trans R Soc Trop Med Hyg* 66: 743, 1972.
- Sacks, H. N., Williams, D. N. & Eifrig, D. E.: Loiasis. *Arch Int Med* 136: 914, 1976.
- Stein, M. F. & Finkelstein, W. E.: Loiasis in Westchester City. *NY State J Med* 34: 1882, 1979.
- Westein, J. C. F.: Loiasis als importziekte in Nederland. *Ned Tijdschr Geneesk* 123: 1937, 1979.
- Zuidema, P. J.: Loiasis. *Ned Tijdschr Geneesk* 110: 165, 1966.