

2. Dulbecco, R. & Ginsberg, H. S.: Viral immunology. Cell-mediated immunity: immunosuppression, p. 1029. *In* Microbiology (ed. B. D. Davis, R. Dulbecco, H. N. Eisen & H. S. Ginsberg). Harper International 1980.
3. Hashimoto, K., Miki, Y., Nakata, S. & Matsuyama, M.: HLA-A10 in pemphigus among Japanese. *Arch Dermatol* 113: 1518, 1977.
4. Nuñez-Roldan, A., Arnaiz-Villena, A. & Nuñez-Ollero, G.: Contrôle génétique par la région HLA de la réponse immunitaire au facteur VIII chez les hémophiles. *C R Acad Sci [D] (Paris)* 288: 1719, 1979.
5. Park, M. S., Terasaki, P. I., Ahmed, A. R. & Tiwari, J. L.: HLA-DRw4 in 91% of Jewish pemphigus vulgaris patients. *Lancet* i: 441, 1979.
6. Ruocco, V.: Pemphigus. Phenomena of cell adherence, p. 106. *In* Cytodiagnosis in Dermatology (ed. V. Ruocco) 145 pp. CLU, Naples, 1980.
7. Sakurai, M., Takigawa, M., Terasaki, P. I., Imamura, S., Sakurami, T., Ueno, Y. & Park, M. S.: Absence of HLA-DRw2 in Japanese Pemphigus Vulgaris. *J Invest Dermatol* 76: 70, 1981.
8. Sertoli, P.: Cytopathology of pemphigus. *Int Gen Rev Dermatol* 11: 139, 1974.
9. Simon, D. G., Krutchkoff, D., Kaslow, R. A. & Zarbo, R.: Pemphigus in Hartford County, Connecticut, from 1972 to 1977. *Arch Dermatol* 116: 1035, 1980.
10. Zappacosta, S., De Felice, M., Fiore, M. & Ferrara, G. B.: The HLA System in the Campania Region: a genetic study. *Tissue Antigens* 16: 286, 1980.

## Multiple Comedones Confined to Xanthelasma

Takuo Tsuji, Masayoshi Furukawa,  
Ritsuko Soejima and Toshio Hamada

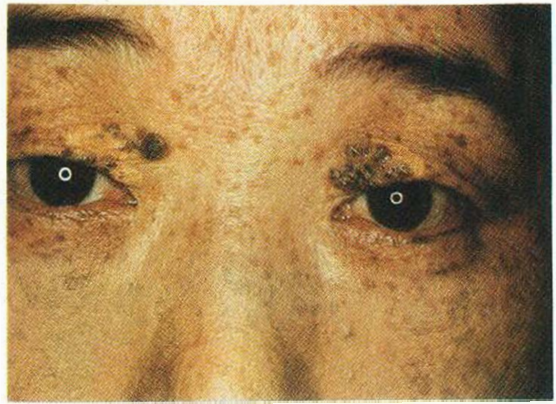
*Department of Dermatology, Osaka City University  
Medical School, Osaka, Japan*

Received February 17, 1982

**Abstract.** A case of multiple comedones which had developed on the xanthelasma of both upper eyelids of a 52-year-old woman is reported. It is suggested that there is a close relationship between comedones and xanthelasma.

**Key words:** Comedones; Xanthelasma

A comedo is a black or grey-brown horny plug projecting from a pilosebaceous orifice. They may arise in naevoid form, as acne vulgaris, familial comedones, acne venenata, and comedones following therapeutic irradiation, or in pseudo-xanthoma elasticum and solar elastosis (1).



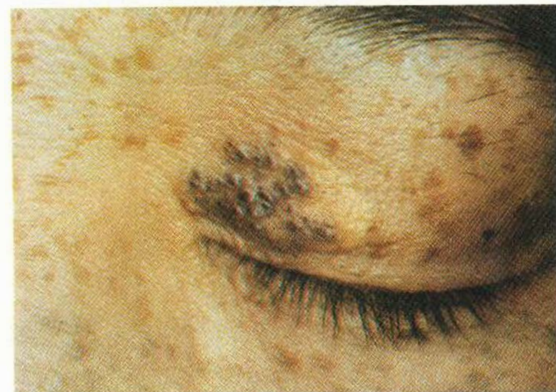*Fig. 1.* Multiple comedones are seen confined to the yellowish plaques on both upper eyelids.

The comedones we present here were confined to xanthelasma and do not resemble any comedone form previously reported.

### REPORT OF A CASE

A 52-year-old Japanese woman with multiple comedones on her upper eyelids was first seen in July 1981. She has had yellowish plaques on her upper eyelids for the past 5 years, on which the comedones have been developing. There was no history of acne vulgaris, UV or cobalt irradiation, excessive sun exposure, topical or systemic steroids or other therapies on the face (including the eyelids).

Results of physical examination, apart from skin lesions, were normal. She has had light-brown, pigmented macules, so-called freckles, scattered on the face since she was around 15 years old. A yellowish plaque measuring 1×3 cm was seen on the inner region of each upper eyelid (Figs. 1 and 2). There were about 20 and 10 come-



*Fig. 2.* Higher power view of comedones on the left upper eyelid.

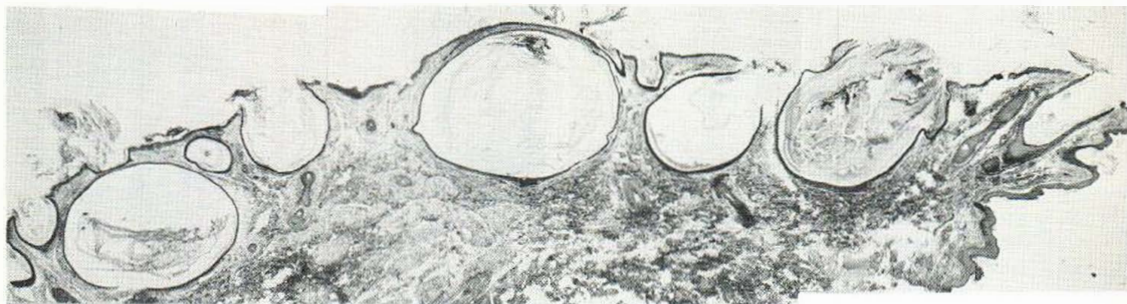


Fig. 3. Histologic appearance of comedones. Dilated follicle-like structures filled with lamellar keratinous material are seen invaginating into the dermis ( $\times 20$ ).

Comedones confined to the yellowish plaques of the left and right upper eyelids respectively. These ranged from pinpoint-sized dark papules to larger papules measuring up to 5 mm in diameter, with a central acuminate keratotic plug displaying a crateriform appearance (Fig. 2). The papules were devoid of inflammatory changes. There

were no lesions suspect of solar elastosis, including cutis rhomboidalis nuchae.

#### *Laboratory findings*

Complete blood cell count, serum protein, serum lipids, blood glucose, serological test for syphilis, and urinalysis showed no abnormalities.

#### *Histopathological studies*

Dilated follicle-like structures filled with lamellar keratinous material were found invaginating into the dermis (Figs. 3 and 4). The follicle wall was, for the most part, formed by 3 to 5 layers of epithelial cells (Figs. 4 and 5). In cross section, the dilated follicular lesions had the appearance of an epidermal cyst. The keratinous material filling the cavities contained an admixture of parakeratotic cells and melanin. Masses of foam cells, usually arranged perivascularly, were present around the dilated follicular structures (Figs. 3, 4 and 5). Sebaceous glands were atrophic and reduced in number. Basophilic degeneration of elastic fibres or solar elastosis could not be found in the dermis. Weigert stain showed that only a few and fine elastic fibres were present throughout the dermis.

## DISCUSSION

This case is unique in that multiple comedones are confined to yellowish plaque on the upper eyelids. The yellowish plaque has been diagnosed as xanthelasma palpebrarum without hyperlipoproteinaemia. The clinical features of the comedones in the present case appear to be similar to those seen in "nodular elastoidoses" or "Favre-Racouchot syndrome" (2, 3). In the latter case numerous large comedones are seen around the orbital and malar regions, and on the neck of those long-exposed to bright sunshine. The skin is yellow and thickened, showing signs of solar elastosis. In our case, however, there were no signs of solar elastosis, but masses of xanthoma cells around the comedones histologically. The clinical and histological

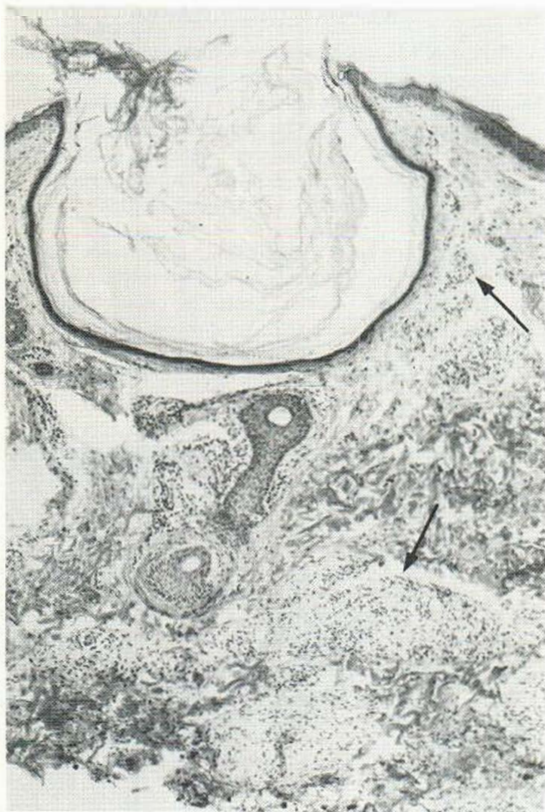

Fig. 4. Higher power view of part of Fig. 3. Masses of xanthoma cells (arrows) are present around and beneath the dilated follicular structure ( $\times 90$ ).



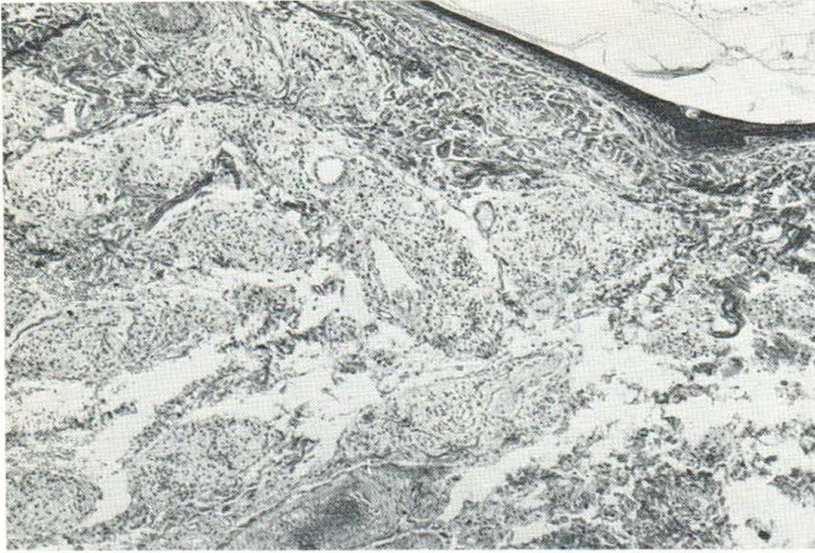


Fig. 5. Higher power view of part of Fig. 3. Masses of xanthoma cells, mostly arranged perivascularly, are present beneath the deepest part of the dilated follicular structure ( $\times 90$ ).

findings ruled out other possible pathological changes in the skin, including naevus comedonicus, naevoid follicular epidermolytic hyperkeratosis, acne vulgaris, familial comedones, acne venenata, acne medicamentosa, and comedones after injury to pilosebaceous follicles by ionizing radiation, or in pseudoxanthoma elasticum (1). Trichofolliculoma has rather similar pathological findings, but exhibits clinically a wool-like tuft of immature hair emerging from a central orifice and the lesions are usually solitary (4, 5). The pathological mechanism of comedones in this patient is unknown. The fact that the comedones were confined to the xanthelasma lesions suggests a close relationship between the comedones and xanthelasma. There are two possible explanations for this relationship. First, loose connective tissue around the pilosebaceous unit which was replaced by xanthoma cells might have induced dilation of hair follicles, resulting in the formation of comedones. Second, the destruction of pilosebaceous structures by surrounding xanthoma cells and subsequent abnormal repair of hair follicles might give rise to comedones. In addition, the decrease in elastic fibres throughout the dermis might be involved in the formation of comedones in this case.

#### REFERENCES

1. Ebling, F. J. & Rook, A.: The sebaceous gland. In *Textbook of Dermatology* (ed. A. Rook, D. S. Wilkinson, F. J. G. Ebling), ed. 3. 1691 pp., Blackwell Scientific Publications, Oxford, 1979.
2. Helm, F.: Ein Beitrag zum Favre-Racouchotschen Syndrom (knotige Hautelastoidose mit Cysten und Komedonen). *Hautarzt* 12: 265, 1961.
3. Cuce, L. C., Paschoal, L. H. C. & Curban, G. V.: Cutaneous nodular elastoidosis with cysts and comedones. *Arch Dermatol* 89: 798, 1964.
4. Miescher, G.: Trichofolliculoma. *Dermatologica* 89: 193, 1944.
5. Kligman, A. M. & Pinkus, H.: The histogenesis of nevoid tumor of the skin. The folliculoma, a hair-follicle tumor. *Arch Dermatol* 81: 922, 1960.

## The Changing Clinical Picture of *Microsporum canis* Infections in Sweden

Lennart Emtestam and Taavi Kaaman

Department of Dermatology  
and the Dermatological Laboratory,  
Södersjukhuset, Stockholm, Sweden

Received February 15, 1982

*Abstract.* All 22 cases of infections with *Microsporum canis* verified by culture during a five-year period were surveyed. Only tinea corporis was found. The clinical