

## BULLOUS ACRODERMATITIS DUE TO ZINC DEFICIENCY DURING TOTAL PARENTERAL NUTRITION: AN ULTRASTRUCTURAL STUDY OF THE EPIDERMAL CHANGES

Kaare Weismann, Nina Kvist and Takasi Kobayasi

*Departments of Dermatology and Pediatric Surgery, University of Copenhagen,  
Rigshospital, Copenhagen, Denmark*

**Abstract.** A 5 ½-year-old girl with idiopathic intestinal pseudo-obstruction became severely depleted of zinc during total parenteral nutrition and developed a vesico-bullous rash on face, hands and feet such as is seen in acrodermatitis enteropathica. Light and electron microscopy of a bullous lesion on one foot revealed a pronounced extracellular edema with cyst and cleft formation in the deep part of the epidermis. A few acantholytic cells were seen. In the electron microscope degenerate keratinocytes showed multiple vacuoles in the dark cytoplasm and slender, finger-like protrusions. Desmosomes were few. The basal lamina was well-preserved forming deep invaginations, which may serve to distinguish the condition from other bullous diseases of the skin.

**Key words:** Acrodermatitis enteropathica; Electron microscopy; Extracellular edema; Pemphigus-like; Total parenteral nutriton; Zinc deficiency

Skin changes are important clinical markers of acute and chronic zinc deficiency in man and animals (9). Earlier histopathological studies have dealt mainly with the changes of scaly, infiltrated skin lesions characteristic of a chronic zinc deficiency, as observed in acrodermatitis enteropathica (AEP) (2, 6, 9) and in acquired zinc deficiency syndromes (3, 8). Few studies have dealt with the acute vesico-bullous skin lesions of AEP (1, 6, 7) and acquired zinc deficiency (4, 9). In the present investigation we concentrated on the ultrastructural changes of the epidermis in a case of acquired zinc deficiency presenting with bullous acrodermatitis.

### CASE REPORT

The patient was a 5 ½-year-old girl who had suffered from intestinal pseudo-obstruction since early childhood. Biopsies had revealed the presence of normal ganglion cells in the rectal wall. At the age of 5 years she developed paralytic ileus and underwent a hemicolectomy. Subsequently

she was reoperated on twice because of intestinal adhesions causing ileus.

She was then started on total parenteral nutrition (TPN) which supplied about 0.5 mg zinc daily. The recommended daily dietary allowance at her age is about 10 mg zinc by mouth, of which approximately 2 or 3 mg is absorbed (9). After 2 months her condition deteriorated. she became febrile and soon a bullous rash appeared on her hands and feet, and a crusty eczema appeared around her mouth, nostrils, eyes and on her ears. She was then transferred to this hospital.

On admission, she was chronically ill, peevish, withdrawn and showed signs of photophobia. Bullae standing on a reddish erythema were present on the volar aspects

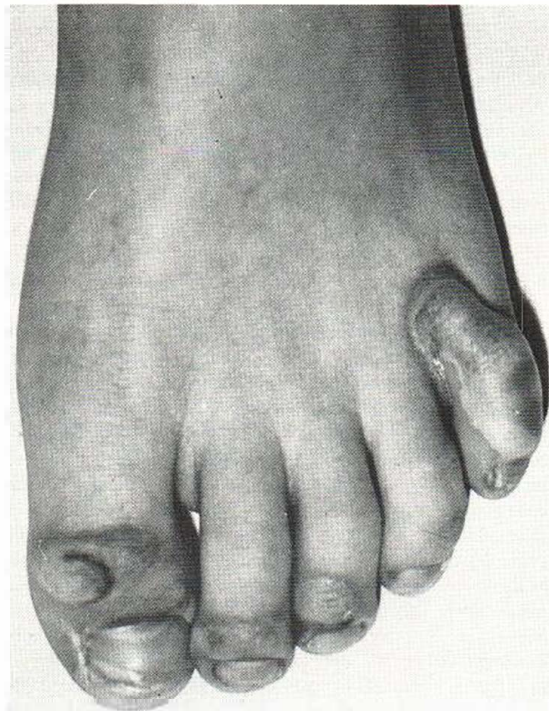

Fig. 1. Bullous acrodermatitis on left foot.

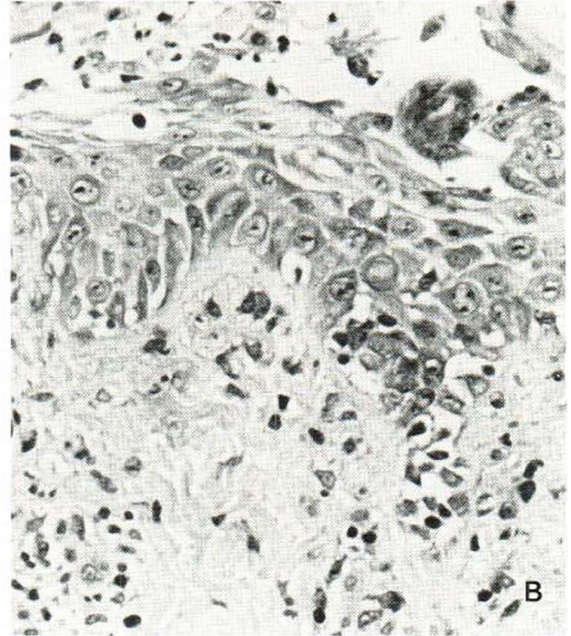
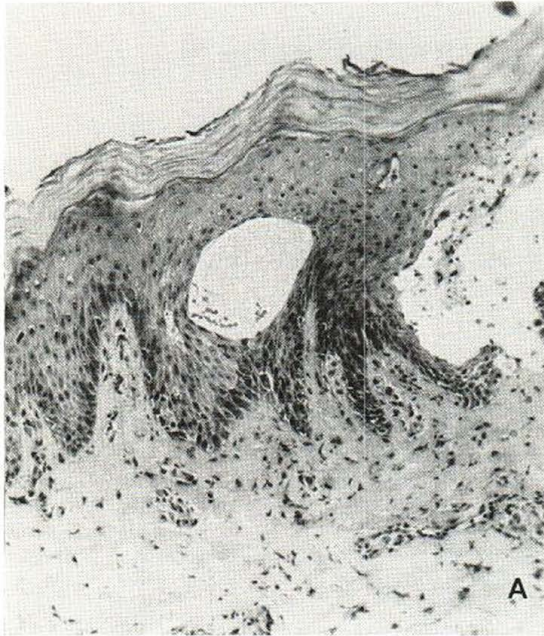


Fig. 2 A and B. Large intra-epidermal cysts and clefts are seen. In the dermal papillary layer there is a moderate perivascular infiltration of lymphocytes, neutrophilic granulocytes and histiocytes (A). Pronounced extracellu-

lar oedema is present at the level of the basal cells which appear degenerate. A few acantholytic cells are seen (B). H. E.,  $\times 106$  and  $\times 900$ .

of hands and fingers and on the dorsal areas of her toes (Fig. 1). Her scalp hair was thinned, and crusty eczema was present around her mouth, nostrils, eyes and ears. As her clinical condition was strongly suggestive of acute zinc deficiency, she was started on zinc supplementation by the intravenous route. Initially she received 5 mg zinc daily, one week later 7.5 mg daily, supplied as zinc sulphate heptahydrate. Her serum zinc level determined before zinc therapy was found to be very low,  $2.1 \mu\text{mol/l}$  (normal range  $10.4$  to  $18.6 \mu\text{mol/l}$ ). Plasma albumin was  $495 \mu\text{mol/l}$  ( $532$  to  $813$ ), serum  $\alpha_2$ -macroglobulin was  $4.77 \text{ g/l}$  ( $0.9$  to  $3.0$ ). The serum alkaline phosphatase level was subnormal for her age,  $192 \text{ U/l}$  ( $250$  to  $1000$ ).

Her response to zinc therapy was prompt, as seen in severe zinc deficiency. Within 2 days she was out of bed, playing eagerly with her toys. After one week the skin appeared practically normal except for a residual scaling on hands and feet. All her scalp hair was lost, but new dark hair soon grew out. Deep transverse Beau's lines appeared on all finger nails after 2 weeks, after 3 weeks similar changes were observed on her toe nails. There was a gradual and parallel rise in serum zinc and serum alkaline phosphate levels.  $^{65}\text{Zn}$  absorption, determined by whole body counting technique, was found low in the normal range, 28% (normal values 27 to 65%) (9). Turnover of absorbed  $^{65}\text{Zn}$  was increased. The findings were probably a consequence of the zinc supplementation. After 3 months in hospital she was discharged to continue TPN and an oral daily zinc supplementation of 10 mg, by which her plasma zinc level remained normal.

## MATERIAL AND METHODS

*Skin specimen.* Before zinc therapy was initiated, a 4-mm punch biopsy was obtained from the edge of a bulla on her left big toe (Fig. 1). The specimen was prepared routinely for conventional light microscopy and for transmission electron microscopy (for details see (10)). Hematoxylin-eosin, uranyl acetate and lead citrate were used for staining. A JEOL electron microscope was used for the ultrastructural study.

## RESULTS

*Light microscopy.* The epidermis was dominated by a pronounced extracellular edema, large cysts and cleft formation low in the epidermal cell layers (Fig. 2 A and B). The roof of the cysts was edematous, being formed of degenerate keratinocytes; the floor was degenerate basal cells. The dermal papillary layer showed perivascular infiltrates of lymphocytes, neutrophils and a few histiocytes.

*Electron microscopy.* Electron microscopy revealed changes similar to those found by light microscopy. There was a pronounced extracellular edema, especially at the level of the basal cell layer. Keratinocytes were degenerate and necrotic. Few desmosomes and hemidesmosomes were seen (Fig.

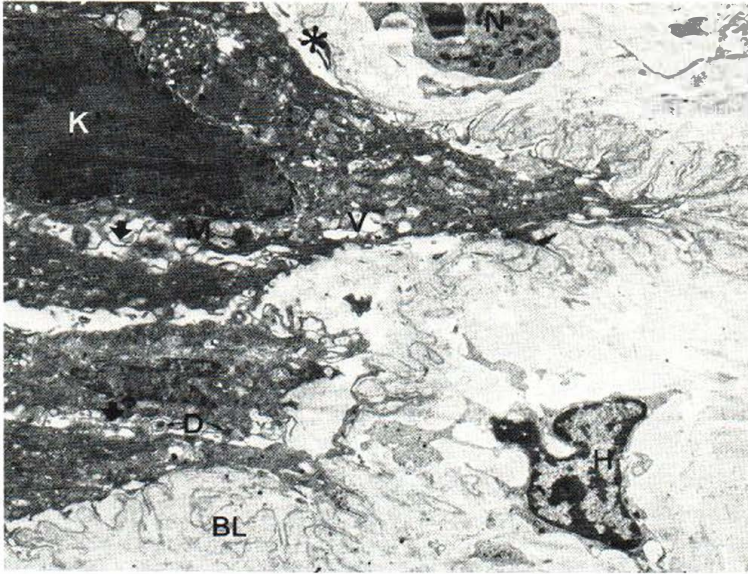


Fig. 3. A keratinocyte (*K*) is partly separated from the basal lamina (*BL*). The basal lamina shows deep, multiple invaginations, is monolayered and has no interruptions. There are numerous vacuoles (*V*) in the dark cytoplasm of the keratinocytes. Finger-like, slender protrusions are indicated by solid arrows. The area marked with an asterisk is shown in Fig. 4. *D* with thin arrows, desmosomes; *M*, mitochondria; *N*, neutrophilic granulocyte; *H*, histiocyte.  $\times 4000$ .

3). The basal cells were partly or completely separated from the basal lamina (Fig. 3). Slender finger-like protrusions of the cytoplasm and multiple vacuoles derived from mitochondria, lysosomes and a dilated endoplasmic reticulum were present in the degenerate keratinocytes (Fig. 4). The basal lamina was monolayered, forming deep invaginations in the underlying papillary layer of dermis (Fig. 3). Multiple thin anchoring fibrils were present (Fig. 4). At the edge of cystic lesions, normal regenerating keratinocytes were seen. They showed normal

desmosomes but no hemidesmosomes. The cysts contained mainly fibrin coagula, a few acantholytic keratinocytes, neutrophilic granulocytes and melanocytes.

## DISCUSSION

Light microscopy revealed epidermal changes similar to those reported in studies dealing with the acute vesico-bullous or erosive skin changes seen in AEP (1, 6, 7) and in severe zinc deficiency caused

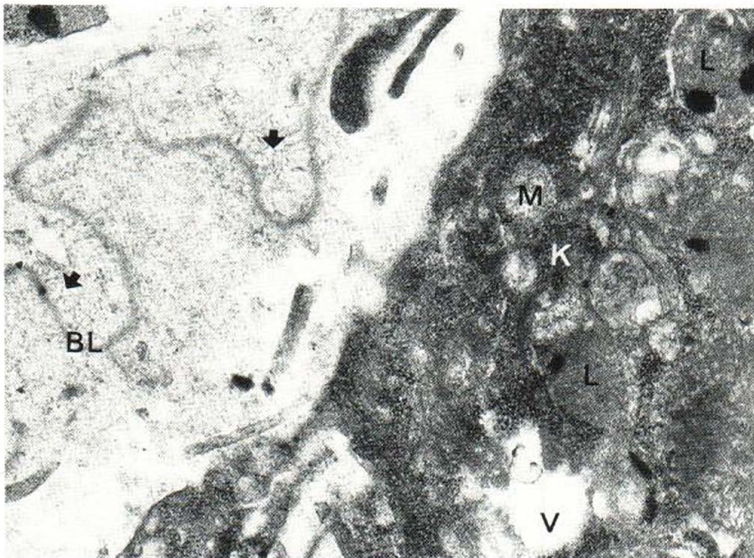


Fig. 4. A degenerate keratinocyte (*K*) contains vacuoles derived from cisterna of endoplasmic reticulum (*V*), mitochondria (*M*) and lysosomes (*L*). The monolayered basal lamina (*BL*) separated from the keratinocyte shows multiple thin anchoring fibrils (solid arrows).  $\times 20\,000$ .

by TPN (4, 9). The lack of parakeratosis in the present case was probably due to acute onset and young age of the lesion studied. Focal parakeratosis is characteristically seen in subacute and chronic zinc deficiency (2, 3, 5, 6, 8). Such lesions additionally show various degrees of spongiosis and irregular acanthosis, sometimes with psoriasis-like rete ridges. The designation parakeratosis psoriasiform could be used for this condition (9).

Electron microscopy has been performed on skin lesions of AEP infants. In the one studied by Ginsburg et al. (5) a chronic scaly lesion showed extracellular edema and cell degeneration mainly in the middle and outer part of the epidermis, whereas the basal cell layer was unaffected. Baudon et al. (1) took biopsies from an erosive skin lesion and found pronounced edema and cell degeneration in the deep part of epidermis, but with an intact basal lamina. Their findings are in agreement with the present study, indicating that the ultrastructural epidermal picture of severe acute zinc deficiency is identical in congenital and acquired states of deficiency of the element.

Zinc deficient animals never develop vesicobullous dermatitis characteristic of acute zinc deficiency in man. The changes are dominated by hyperkeratosis and parakeratosis. Rats deprived of zinc for 4 weeks were studied by electron microscopy (10). Two different types of ultrastructural changes were found. One was characterized by swollen keratinocytes with preserved desmosomes and multiple cytoplasmic protrusions of a coarser structure than the finger-like extensions observed here. The second type showed parakeratotic, severely degenerate keratinocytes with few, poorly developed desmosomes. As in man, the dermal changes were comparatively slight.

Acute zinc deficiency presenting with bullae, vesicles and erosions may be mistaken for other bullous diseases of the skin. The present finding of a deeply invaginated intact basal lamina without any interruptions may be helpful in distinguishing pem-

phigus vulgaris, familial pemphigoid, and epidermolysis bullosa of the junction blister type, from bullous acrodermatitis due to severe zinc deficiency.

## REFERENCES

1. Baudon, J.-J., Fontaine, J. L., Larregues, M., Feldman, G. & Laplane, R.: Acrodermatitis enteropathica. Étude anatomoclinique de deux cas familiaux traités par le sulfate de zinc. *Arch Franc Ped* 35: 63-73, 1978.
2. Brandt, T.: Dermatitis in children with disturbances of the general condition and the absorption of food elements. *Acta Dermatovener (Stockholm)* 17: 513-546, 1936.
3. Esca, S. A., Brenner, W., Mach, K. & Gschnait, F.: Kwashiorkor-like zinc deficiency syndrome in anorexia nervosa. *Acta Dermatovener (Stockholm)* 59: 361-364, 1979.
4. Ferrandiz, C., Henkes, J., Peyri, J. & Sarmiento, J.: Acquired zinc deficiency syndrome during total parenteral alimentation. *Dermatologica* 163: 255-266, 1981.
5. Ginsburg, R., Robertson, A. & Michel, B.: Acrodermatitis enteropathica. Abnormalities of fat metabolism and integumental ultrastructures in infants. *Arch Dermatol* 112: 653-660, 1976.
6. Piper, E. L.: Acrodermatitis in an adult. *Arch Dermatol* 76: 221-224, 1957.
7. Rodin, A. E. & Goldman, A. S.: Autopsy findings in acrodermatitis enteropathica. *Am J Clin Pathol* 51: 315-322, 1969.
8. Vloten, W. A. van, & Bos, L. P.: Skin lesions in acquired zinc deficiency due to parenteral nutrition. *Dermatologica* 156: 175-183, 1978.
9. Weissmann, K.: Zinc deficiency and effects of systemic zinc therapy (thesis). FADLs forlag, Copenhagen, 1980.
10. Weissmann, K., Christophersen, J. & Kobayasi, T.: Ultrastructural changes of zinc deficient rat epidermis: An electron microscopic study. *Acta Dermatovener (Stockholm)* 60: 197-202, 1980.

Received June 28, 1982

K. Weissmann, M.D.  
Department of Dermatology  
The Municipal Hospital  
Øster Farimagsgade 5  
DK-1399 Copenhagen K  
Denmark