

Ultrastructure of Uninvolved Oral Mucosa in Pemphigus Patients

JARKKO HIETANEN, OSMO P. SALO, LASSE KANERVA and
RAIJA KIISTALA

Department of Dermatology and Hospital for Allergic Diseases, University Central Hospital, Helsinki and Institute of Occupational Health, Helsinki, Finland

Hietanen J, Salo OP, Kanerva L, Kiistala R. Ultrastructure of uninvolved oral mucosa in pemphigus patients. *Acta Derm Venereol (Stockh)* 1983; 63: 491-494.

The uninvolved oral mucosa of seven pemphigus patients was compared with that of age- and sex-matched controls. Three patients had pemphigus erythematodes, two had pemphigus vulgaris, one had pemphigus foliaceus, and one pemphigus vegetans. Five out of seven pemphigus patients demonstrated wider intercellular spaces than the controls. This difference was seen in both basal and spinous epithelial cell layers and was more pronounced in the basal cell layer. There were fewer desmosomes and microvilli than in the controls. It appears that ultrastructural changes in pemphigus also occur in the uninvolved oral mucosa of pemphigus patients. *Key words: Oral cavity; Desmosomes; Microvilli; Acantholysis.* (Received June 2, 1983.)

J. Hietanen, Fredrikinkatu 71 A 23, SF-00100 Helsinki 10, Finland.

Pemphigus is a disease involving the skin and mucous membranes. Oral mucosa is often the initial site of lesions, especially in pemphigus vulgaris (1). Oral lesions are rarely or never found in connection with pemphigus foliaceus and erythematodes (2).

Widened intercellular spaces and reduced numbers of desmosomes have been reported in the uninvolved epidermis close to the site of a lesion in a pemphigus patient (3). It has also been suggested that both the uninvolved and involved oral mucosa of pemphigus patients shows widened intercellular spaces and fewer desmosomes than normal (4).

To the best of our knowledge, age- and sex-matched controls have so far not been studied; in this study we have compared the uninvolved oral mucosa of pemphigus patients with that of controls matched for age and sex.

PATIENTS AND METHODS

Punch biopsies (diameter 2 mm) were taken from the clinically uninvolved right buccal mucosa of seven pemphigus patients and seven clinically healthy volunteers matched for age and sex. For details of the patients, see Table I. Five of the patients were females (mean age 50.8 years) and two were males (mean age 51.0 years). Three patients had pemphigus erythematodes, two had pemphigus vulgaris, one had pemphigus foliaceus and one pemphigus vegetans.

Three of seven patients showed restricted pemphigus lesions on the skin and four had no lesions. Four of the patients were treated with systemic prednisone, one was treated with sodium aurothiomalate and two received no systemic treatment.

The samples taken for transmission electron microscopy were prefixed with 1.5% glutaraldehyde in 0.1 M sodium phosphate buffer (pH 7.2) for two hours. They were postfixated for 1.5 hours with 1% osmium tetroxide in 0.1 M phosphate buffer (pH 7.2). The sections were cut from Epon 812-embedded samples and stained with uranyl acetate and lead citrate.

The samples were viewed and photographed with a JEOL JEM-100CX TEMSCAN electron microscope at the Department of Electron Microscopy, University of Helsinki, Finland, at an accelerating voltage of 60 kV. The electron micrographs of the age- and sex-matched controls were examined and compared using a blind experimental design on a semiquantitative basis by two of the authors (J. H., L. K.).

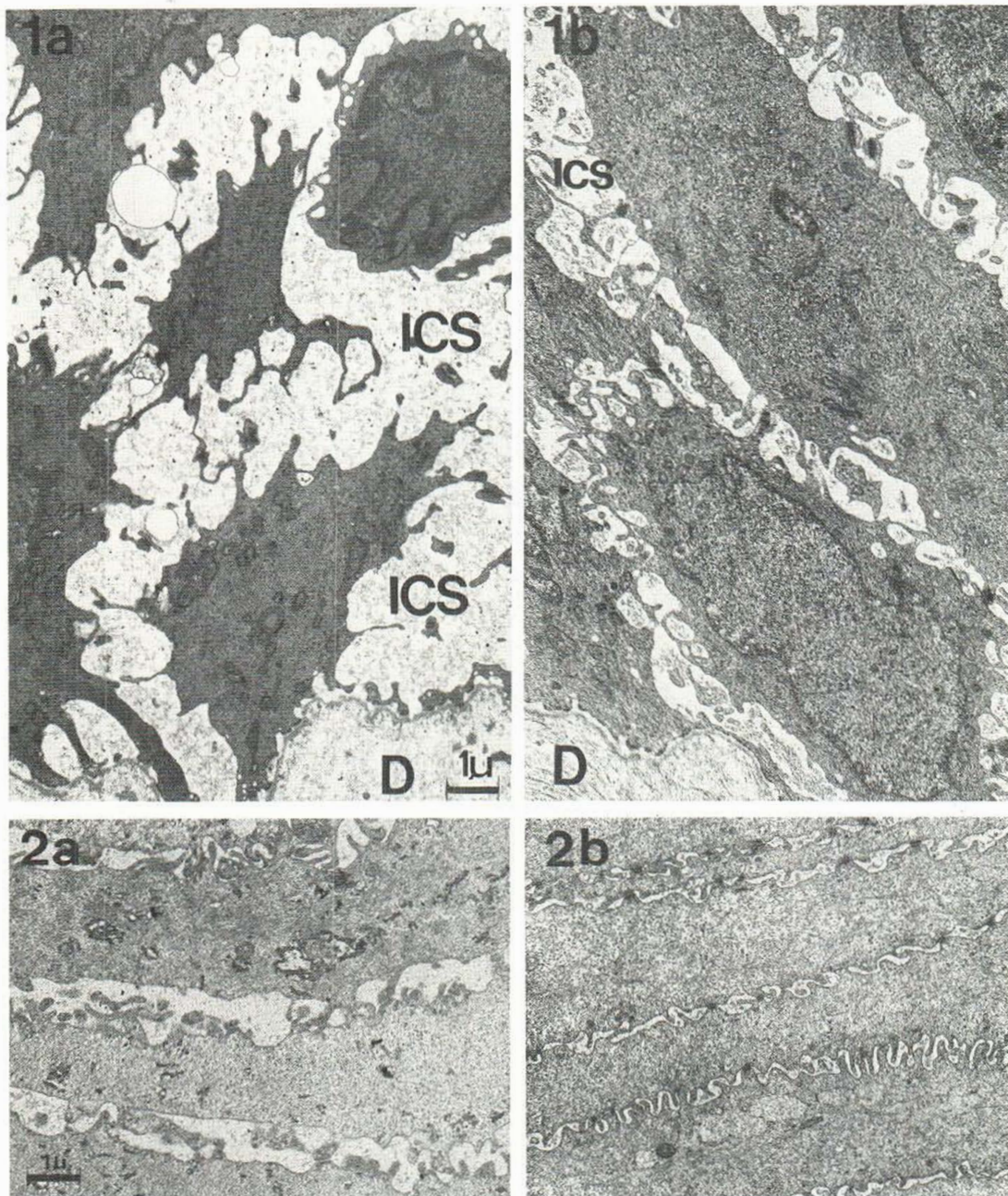


Fig. 1. (a) Uninvolved oral mucosal epithelium from a pemphigus patient (H. A.-S.). *(b)* Age- and sex-matched control (L. K.). Note the widened intercellular space (ICS), and fewer desmosomes and microvilli in the pemphigus case. *D*, papillary connective tissue. $\times 7500$, bar $1 \mu\text{m}$.

Fig. 2. Upper spinous layers from the same persons as in Fig. 1. The intercellular spaces are larger in the pemphigus case (Fig. 2a) than in the control (Fig. 2b). $\times 7500$, bar $1 \mu\text{m}$.

RESULTS

The intercellular spaces of the epithelium were usually wider in patients with pemphigus than in the age- and sex-matched controls (Fig. 1). A clear-cut difference between the pemphigus patients and controls was seen in five of the seven cases. One of the two patients not showing any difference in relation to the respective control case had pemphigus vegetans (T. N.) and the other had pemphigus erythematoses (E. T.).

The widening of the intercellular spaces was more marked in the basal cell layer than in the spinous layer. The basal cells of the pemphigus group displayed fewer microvilli and fewer desmosomes than those of the control group (Fig. 1). This difference could be seen in the five pairs of subjects who also displayed widening of the intercellular spaces. Also, the spinous epithelial cells of oral mucosa of pemphigus patients had fewer microridges (microvilli) on their surfaces and fewer desmosomes than controls in five of the seven cases (Fig. 2).

The structure of the desmosomes was normal in both the patients with pemphigus and the controls. The cell organelles were well-preserved in both groups. However, more mitochondria were seen in some samples from the control group than in the pemphigus group. Intercellular material could be seen, especially in the basal cell layers in both the pemphigus and the control groups. The basal lamina was unchanged in all cases.

DISCUSSION

The width of the intercellular space of normal epidermis has been a subject of much attention in recent years (5). A series of fixation experiments has shown that the width of intercellular space is dependent on the vehicle osmolality of the buffer used. On the other hand, the total osmolality of the fixative can vary over a wide range without affecting the width of the intercellular space (5). In the present study all the biopsy specimens were prefixed with exactly the same fixative (1.5% glutaraldehyde), which always had a buffer

Table I. Clinical data of pemphigus patients and their age- and sex-matched controls

No.	Patient	Age/ sex	Year of onset	Histo- pathology	Site of skin lesions	Inter- cellular antibody titre	Treatment	Con- trol	Age/ sex
1.	T. N.	21/F	1981	Pemphigus vegetans	—	1:100	Prednisone 10 mg/ day	S. G.	22/F
2.	H. A.-S.	40/F	1982	Pemphigus vulgaris	—	1:10	Prednisone 10 mg or 5 mg every other day	L. K.	42/F
3.	K. L.	55/F	1971	Pemphigus erythema- todes	—	1:10	—	G. J.	56/F
4.	E. T.	64/F	1982	Pemphigus erythema- todes	—	Negative	Prednisone 25 mg/day	L. I.	63/F
5.	E. V.	74/F	1982	Pemphigus erythema- todes	Chest, fore head, hairline, buttocks	Not taken	Prednisone 5 mg every other day	A. J.	73/F
6.	H. F.	40/M	1977	Pemphigus foliaceus	Legs	Negative	Sodium aurothioma- late 50 mg/month	V. H.	39/M
7.	L. F.	62/M	1973	Pemphigus vulgaris	Hairline	Negative	—	O. S.	57/M

osmolality of 400 mosm/kg H₂O, i.e. within the range of 230–400 mosm/kg H₂O recommended by Falck et al. (5). If the osmolality is under 230 mosm/kg H₂O a swelling artefact is produced, which may be the reason for the old idea of epidermal cells being very closely packed (5).

In the present study widened intercellular spaces, and fewer desmosomes and microvilli were found in five of the seven cases. In one patient with pemphigus erythematodes (E. T.) and one with pemphigus vegetans (T. N.) there was no clear-cut difference from the control subjects matched for age and sex. These two patients did not have any pemphigus skin lesions. Of the five patients showing ultrastructural oral changes three had restricted lesions on the skin and two had no lesions. In all patients the mild character of their disease was reflected in the low dosage of the systemic drug therapy and low serum intercellular antibody titres, except in one case (T. N.). However, her last titre was determined during an acute phase of the disease.

The width of the intercellular space diminished from basal layers to the surface. The widening of intercellular spaces was mainly seen by Braun-Falco & Vogell (3) in the spinous layers of the uninvolved skin of a patient with pemphigus. It must be remembered that the intercellular space between vital cells might be narrower, as the plastic embedding of electron microscopic samples may also cause slight shrinkage of cells and widened intercellular space.

The lesions of pemphigus are characterized by acantholysis, which is caused by an enzyme (pemphigus acantholysis factor) activated by pemphigus antibody (6, 7). On an ultrastructural level dissolution of glycocalyx leads to widened intercellular spaces and gradual loss of desmosomes (8, 9).

In the present study a smaller number of desmosomes was found in the oral epithelium of most of the pemphigus patients. In contrast to Braun-Falco & Vogell (3) we could not see any structural changes in pemphigus desmosomes when compared with control desmosomes. The cell surfaces of the oral epithelial cells of the present pemphigus patients had a smaller number of microvilli than the controls. This supports the idea that during acantholysis epithelial cells under both in vivo and in vitro conditions lose their microvilli and attain a smooth surface texture (1). The reduced number of microvilli and desmosomes in uninvolved skin may be an important contributory mechanism in the loss of cellular cohesion on blistering.

REFERENCES

1. Hietanen J. Pemphigus. An epidemiological, ultrastructural and immunological study. Thesis. Proc Finn Dent Soc 1982; 78: suppl. VI.
2. Pindborg JJ. Diseases of the skin. In: Jones JH, Mason DK, eds. Oral manifestations of systemic disease. London: Saunders, 1980; 326–329.
3. Braun-Falco O, Vogell W. Elektronenmikroskopische Untersuchungen zur Dynamik der Acantholyse bei Pemphigus vulgaris. I. Die klinisch normal aussehende Haut in der Umgebung von Blasen mit positivem Nikolski-Phänomen. Arch Klin Exp Dermatol 1965; 223: 328–346.
4. Hietanen J, Lounatmaa K. Freeze-fracturing of oral epithelial cells in pemphigus. Acta Odontol Scand 1982; 40: 415–420.
5. Falck B, Andersson A, Elofsson R, Sjöborg S. New views on epidermis and its Langerhans cells in the normal state and in contact dermatitis. Acta Derm Venereol (Stockh) 1981; 61: suppl. 99: 3–27.
6. Schiltz JR, Michel B, Papay R. Appearance of "pemphigus acantholysis factor" in human skin cultured with pemphigus antibody. J Invest Dermatol 1979; 73: 575–581.
7. Schiltz JR. Pemphigus acantholysis: a unique immunological injury. J Invest Dermatol 1980; 74: 359–362.
8. Hashimoto K, Lever WF. An electron microscopic study on pemphigus vulgaris of the mouth and the skin with special reference to the intercellular cement. J Invest Dermatol 1967; 48: 540–552.
9. Lever WF, Hashimoto K. The etiology and treatment of pemphigus and pemphigoid. J Invest Dermatol 1969; 53: 373–389.