

Steroid-induced 'Granulomas' in Hypertrophic Scar

JAG BHAWAN

Department of Pathology (Dermatopathology), University of Massachusetts Medical School, Worcester, Massachusetts, USA

Bhawan J. Steroid-induced 'granulomas' in hypertrophic scar. *Acta Venereol* (Stockh) 1983; 63: 560-563.

Intralesional steroids injected into hypertrophic scars and keloids can result in histiocytic and foreign body granulomatous reaction which may be confused with focal mucinosis or necrobiotic process such as rheumatoid nodule. An awareness of this possibility might avoid unnecessary investigations in the patient. *Key words: Keloid; Hypertrophic scar; Granuloma, intralesional steroid; Rheumatoid nodule; Mucinosis.* (Received January 19, 1983.)

J. Bhawan, Department of Pathology, University of Massachusetts Medical School, 55 Lake Avenue North, Worcester, Massachusetts 01605, USA.

Intralesional corticosteroid injection in keloids and hypertrophic scar is a well-known method of treatment (3). Some of these injected keloids, when resected, may be confused histologically with focal cutaneous mucinosis (4) or rheumatoid nodule (5). We recently encountered a hypertrophic scar in which similar changes were observed.

MATERIALS AND METHODS

The biopsy was obtained from a lesion on the shoulder of a 24-year-old white lady, which was clinically diagnosed as keloid. She received 4-weekly intralesional injection of triamcinolone prior to

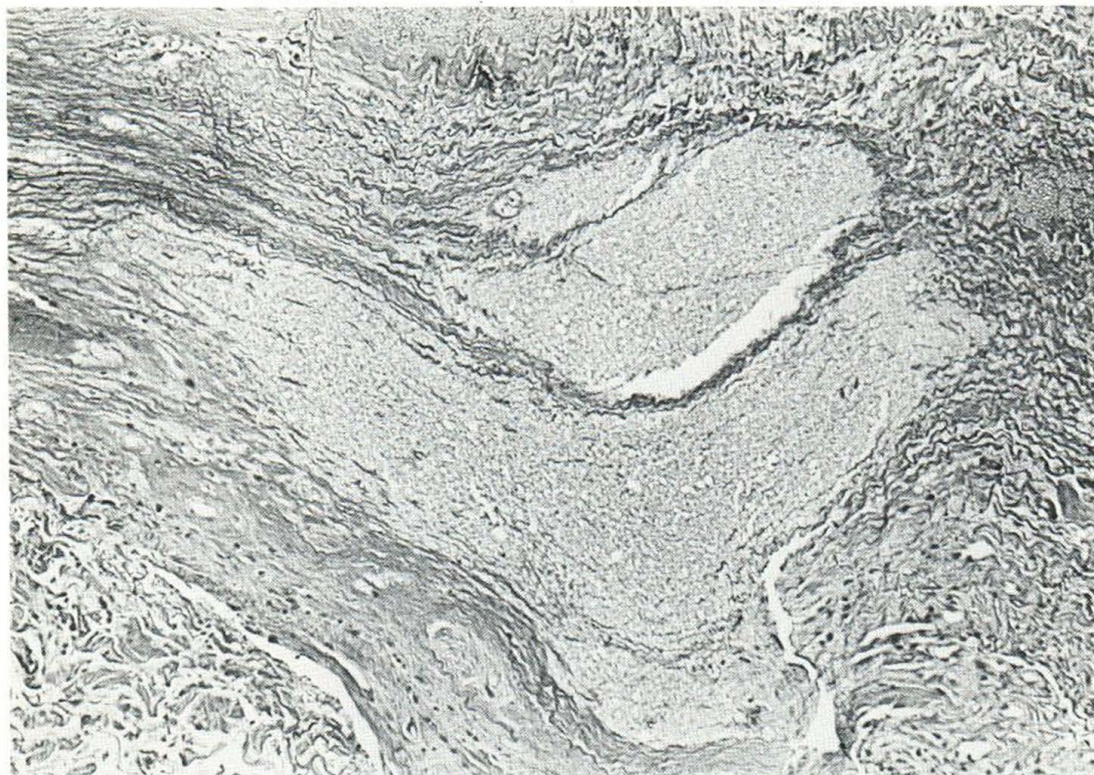

Fig. 1. Photomicrograph shows large pools of mucinous material without inflammatory reaction at the periphery. Hematoxylin and eosin, $\times 88$.

excisional biopsy one week after the last injection. The biopsy was processed for light microscopy and 5- μm paraffin wax-embedded sections were cut and stained with hematoxylin and eosin, PAS (with and without Diastase), alcian blue at pH 1.0 and 2.5 (with and without hyaluronidase), Masson's trichrome, colloidal iron, mucicarmine and stain for fibrin.

Pathology

Light microscopy of the H & E stained sections revealed the typical morphology of the hypertrophic scar. Within this scar, four lightly stained, well circumscribed areas were seen. Higher magnification revealed the lightly stained areas to consist of pools of granular to amorphous acellular, lightly staining material. No inflammatory cellular reaction was seen around one of them (Fig. 1), while a histiocytic and foreign body granulomatous response of variable degree was seen at the periphery of others (Figs. 2, 3). Histochemical examination excluded the fibrinous or acid mucopolysaccharide nature of the material.

DISCUSSION

Intralesional steroid injection of keloids and hypertrophic scars is a well-known therapeutic measure, used either alone (3) or as an adjunct to resection (1, 2). Such lesions, when resected after intralesional injection of steroids, show mucinous acellular material. Occasionally a foreign body and/or histiocytic granulomatous response may be seen around this material.

Some authors have reported fibrin surrounded by inflammatory reaction after injection of hydrocortisone (5). However, no special staining was performed to confirm the fibrin

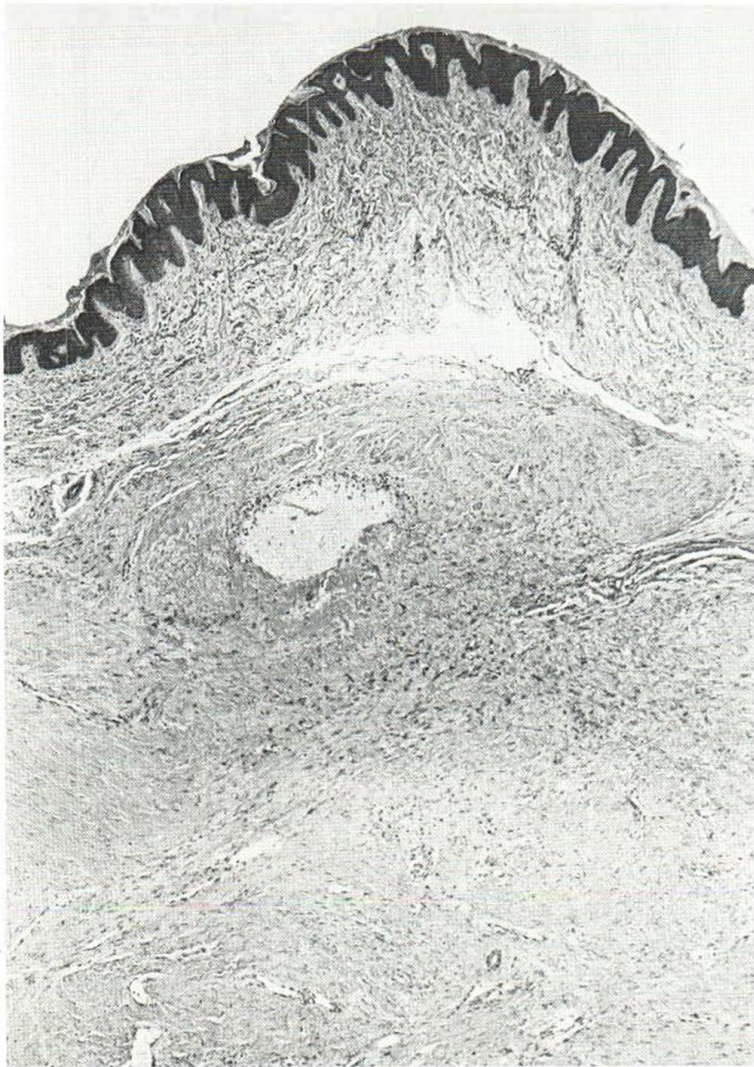

Fig. 2. Hypertrophic scar with a small, well circumscribed area of mucinous material and peripheral inflammatory reaction. Hematoxylin and eosin, $\times 35$.

nature of the material in that study. Furthermore, their patient was injected with hydrocortisone for 'tennis elbow'. The underlying basic pathology may have been different. Even though rheumatoid nodule may have to be considered in the differential diagnosis of a lesion such as shown in this study, the presence of fibrin has not been demonstrated in our study. Nor did Santa Cruz & Ulbright (4) observe a similar change in keloids, in a review of a large number of cases.

The pathogenesis of granulomatous response is not known. These changes may represent tissue reaction to the drug or the solubilizing vehicle (4). Weedon et al. felt that an inability of the injected material to disperse in the usual manner led to a foreign body reaction (5). However, similar granulomatous reaction has been observed in nasal mucosa following local injections of steroids for allergic rhinitis, where the role of mechanical factors will be difficult to implicate.

Weedon et al. did not observe any inflammatory reaction in keloid removed 4 days after

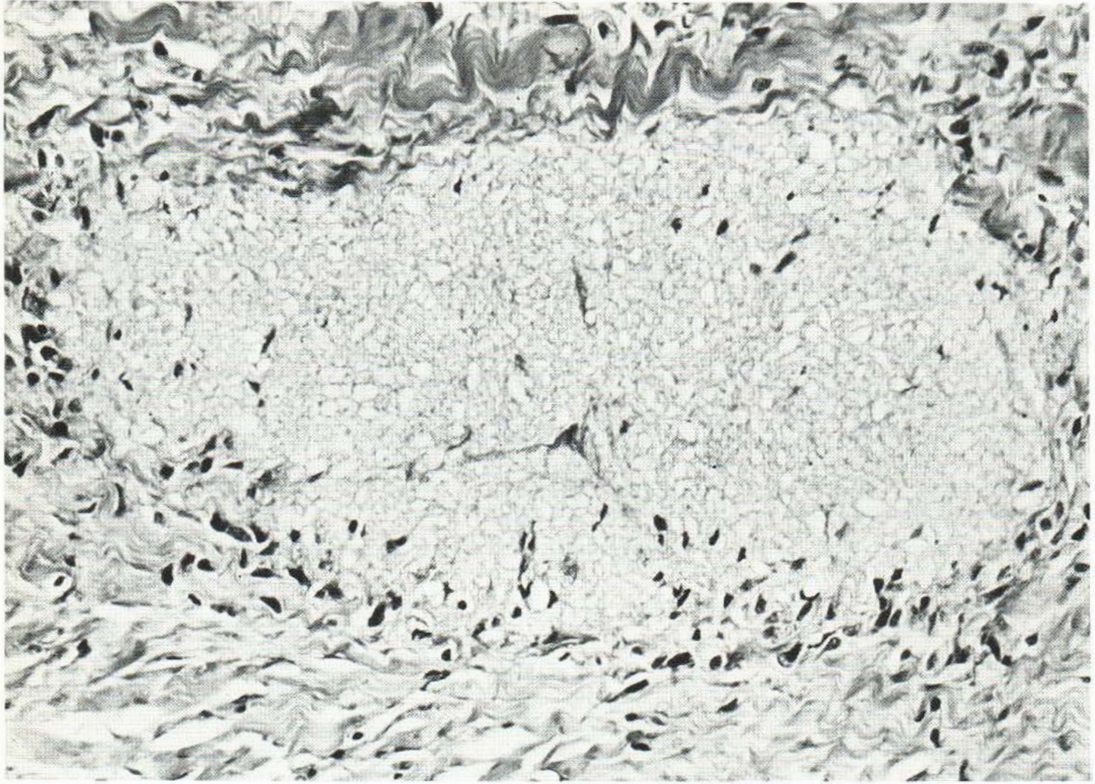


Fig. 3. Higher magnification clearly shows the foreign body granulomatous and histocytic reaction. Hematoxylin and eosin, $\times 200$.

the injection of steroids (5). It is therefore reasonable to assume that in this study the largest circumscribed area of acellular material without inflammatory response was the last injection (one week prior to resection), while the smallest with granulomatous reaction was the first injection (5 weeks prior to resection). It is quite possible that in time the injected steroid material either diffuses or is absorbed while leaving a small amount which may act as foreign material evoking an inflammatory reaction. Thus, the results of this study and that of Weedon et al. indicate that the foreign body granulomatous reaction is time dependent, whatever the mechanisms of its pathogenesis may be.

REFERENCES

1. Griffith BH, Monroe CW, McKinney P. A follow up study on the treatment of keloids with triamcinolone acetonide. *Plast Reconstr Surg* 1970; 46: 145.
2. Ketchum LD, Cohen IK, Masters FW. Hypertrophic scars and keloids: A collective review. *Plast Reconstr Surg* 1974; 53: 140.
3. McGuire HC. Treatment of keloids with triamcinolone acetonide injected intralesionally. *J Am Med Assoc* 1965; 192: 325.
4. Santa Cruz DJ, Ulbright TM. Mucin-like changes in keloids. *Am J Clin Pathol* 1981; 75: 18.
5. Weedon D, Gutteridge BH, Hockly RG, Emmett AJJ. Unusual cutaneous reactions to injections of corticosteroids. *Am J Dermatol Pathol* 1982; 4: 199.
6. Wolff M. Granulomas in nasal mucous membranes following local steroid injections. *Am J Clin Pathol* 1974; 62: 775.