

Pseudo-Kaposi Sarcoma of the Feet: An Electron Microscopic Investigation

LENA SECHER, KAARE WEISMANN and TAKASI KOBAYASI

*Department of Dermatology, Rigshospital and the Skin Clinic,
Municipal Hospital, Copenhagen, Denmark*

Secher L, Weismann K, Kobayasi T. Pseudo-Kaposi sarcoma of the feet: An electron microscopic investigation. *Acta Derm Venereol* (Stockh) 1984; 64: 246-249.

A case of pseudo-Kaposi sarcoma of the feet (acroangiodermatitis) is reported. The patient showed clinical and light-microscopical signs closely resembling Kaposi's sarcoma, but by electron microscopy of skin biopsies definite signs of degeneration of vascular walls and infiltrating cells were demonstrated. Electron microscopy should be applied when conventional histology is inconclusive or fits poorly to the anamnestic information and/or clinical appearance of the lesions. *Key words: Acroangiodermatitis; Kaposi's sarcoma.* (Received October 7, 1983.)

Lena Secher, Department of Dermatology, Rigshospital, 9 Blegdamsvej, DK-2100 Copenhagen, Denmark.

The increasing incidence of Kaposi's sarcoma reported in recent years sharpens our attention towards possible signs of this disease in skin or mucous membranes. Thus, the need for reliable differential diagnostic criteria is enhanced. Pseudo-Kaposi sarcoma is an acroangiodermatitis. The clinical and histological findings mimic true Kaposi's sarcoma (1,

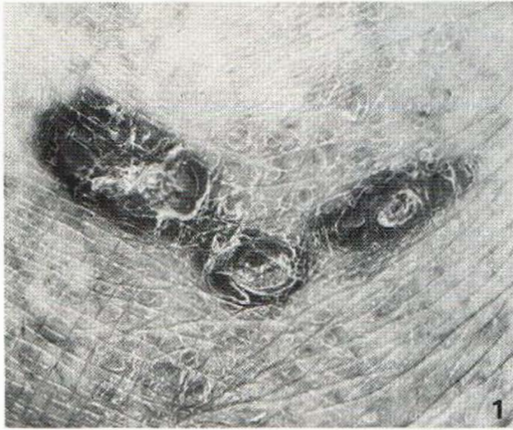
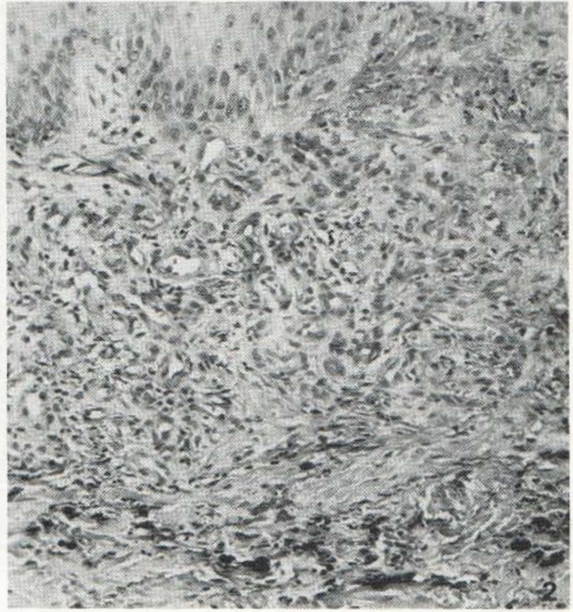


Fig. 1. Bluish-red nodular lesions on the lateral aspect of the left ankle.

Fig. 2. The papillary dermis shows proliferation of small vessels, extravasation of erythrocytes and a slight inflammatory reaction. The lower dermis contains pigment granules. $\times 240$.



2, 3). Electron microscopic investigations have characterized the ultrastructure of the cells in Kaposi's sarcoma (4, 5), especially the so-called spindle-cell (6). The aim of the present study is to describe the ultrastructure of the cells in pseudo-Kaposi sarcoma and to compare them with those of true Kaposi's sarcoma.

CASE REPORT

The patient was a 61-year-old male, who for more than a decade had suffered from papular and nodular, bluish-red infiltrates on both feet (Fig. 1). Phlebography verified venous insufficiency following deep thrombophlebitis, and in 1978 increased venous pressure of both legs was diagnosed. Resection of insufficient communicants in 1979 did not change the lesions on the feet, and the patient continued to complain of pain and soreness of the involved skin areas. There was little effect of anti-inflammatory treatment with topical steroids and tar, and local X-ray therapy also left the lesions uncharged. Regular control for several years has ascertained that no dissemination of the disease had taken place.

MATERIAL AND METHODS

Skin biopsies from the lesions on the feet was studied by conventional light microscopy. Specimens for electron microscopy were immediately fixed in ice-cooled 6% glutaraldehyde in 0.5 M cacodylate buffer pH 7.2 with 7.5% sucrose. The samples were osmicated, dehydrated in a series of alcohol solutions, and embedded in Epon 812. Ultrathin sections were stained by uranyl acetate and lead citrate and observed in a JEOL 100 CX electron microscope.

RESULTS

Light microscopy showed an atrophic epidermis. Localized in the upper part of the dermis was a well-defined cell infiltrate with mononuclear cells and eosinophils (Fig. 2). There was proliferation of small vessels and fibroblasts, but no atypical nuclei of endothelial cells

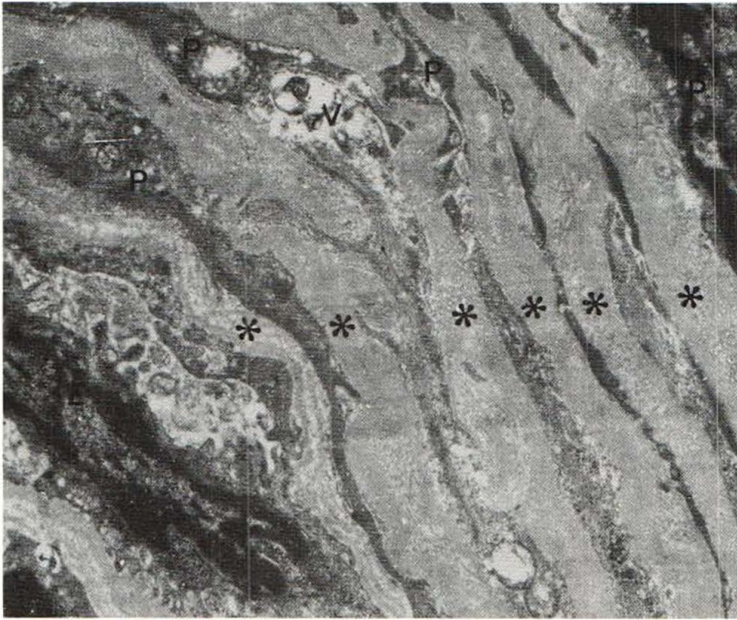


Fig. 3. Fraction of vessel wall with endothelial cell (*E*) showing an irregular surface, and pericytes (*P*) with vacuoles and multiple, thickened basal laminae (asterisk). $\times 12\,000$.

or abnormal fibroblasts were found. In the deep layers of the dermis there were extravasation of red cells and hemosiderin deposits.

Electron microscopic examination of the skin biopsy showed thickening of the vessel walls as a predominant feature (Fig. 3). The thickening was due to several concentric layers of pericytes with irregularly thickened basal lamina. The pericytes contained vacuolized mitochondria, and the cell membranes were indistinct; there was no evidence of hypertrophy. The endothelial cells also had vacuoles, and their basal lamina was thin and partly interrupted. The cell surfaces were irregular (Fig. 3). No spindle cells were seen, and neither pericytes nor endothelial cells contained nuclear bodies. There was oedema of the perivascular area, and the cell infiltrate was dominated by lymphoid cells. Some of them had vacuoles in the cytoplasm, condensates of chromatin and indistinct cell membranes. No mast cells were seen.

DISCUSSION

Light microscopy of the nodular lesions on the feet of our 61-year-old patient with venous insufficiency showed histopathological changes as seen in acroangiokeratosis or pseudo-Kaposi sarcoma (2). The pathogenesis of this condition is not known in all cases, but undoubtedly many cases are caused by congenital or acquired increase of the venous pressure of the lower extremities (1, 2). From the clinical appearance, Kaposi's sarcoma may be suspected, and histological examination may support this diagnosis. Ultrastructural investigations have established the spindle cell to be the characteristic neoplastic cell in Kaposi's sarcoma (6). The origin of this cell is uncertain, but most authors believe it to be a pericyte. Hypertrophied endothelial cells with increased mitotic activity, often containing nuclear bodies, are also a common feature of Kaposi's sarcoma.

Our investigation shows that no spindle cells or nuclear bodies are present in pseudo-Kaposi sarcoma. The ultrastructure of the proliferating pericytes shows signs of degener-

ation, and they are not hypertrophic. Probably they are the result of chronic stasis and oedema.

The importance of distinguishing the benign, chronic acroangiokeratosis or pseudo-Kaposi sarcoma from the malignant Kaposi's sarcoma is obvious. Furthermore, irradiation of the affected skin in pseudo-Kaposi sarcoma can increase the damage to blood vessels and thus add to the circulatory insufficiency believed to cause the skin changes. In cases, where conventional microscopy leaves doubt about the diagnosis, electron microscopy can be of use in differentiating the two conditions.

REFERENCES

1. Mali J W H, Kniper J P, Hamers A A. Acroangiokeratosis of the foot. *Arch Dermatol* 1965; 92: 515-518.
2. Brenner S, Ophir I, Krakowski A, Weinraub Z. Kaposi-like arteriovenous malformation and angiokeratosis (pseudo-Kaposi). *Cutis* 1982; 30: 240-256.
3. Weismann K, Kobayasi T. Acroangiokeratosis på underekstremiteterne. *Ugeskr Læg* (in press).
4. Hashimoto K, Lever W. Kaposi's sarcoma. Histochemical and electron microscopic studies. *J Invest Dermatol* 1964; 43: 539-549.
5. Mottaz J H, Zelickson A S. Electron microscope observations of Kaposi's sarcoma. *Acta Derm Venereol (Stockh)* 1966; 46: 195-200.
6. Niemi M, Mustakallio K K. The fine structure of the spindle cell in Kaposi's sarcoma. *Acta Pathol Microbiol Scand* 1965; 63: 567-575.