

SHORT REPORTS

Brittle Hair in Osteogenesis Imperfecta: Transmission and Scanning Electron Microscopy and Mycologic Assay

BO FORSLIND¹ and TAAVI KAAMAN²

¹Department of Medical Biophysics, Karolinska Institutet, Stockholm, and

²Department of Dermatology, Södersjukhuset, Stockholm, Sweden

Forslind B, Kaaman T. Brittle hair in osteogenesis imperfecta: Transmission and scanning electron microscopy and mycologic assay. Acta Derm Venereol (Stockh) 1984; 64: 418-420.

The brittle hair fibres from a case of osteogenesis imperfecta were studied by scanning and transmission electron microscopy. Normal hair fibres are extremely difficult to infect with *T. mentagrophytes*. As a tentative assay for biochemical defects of hair fibres, experimental dermatophytic infection of the hair with *T. mentagrophytes* was performed. The massive growth induced suggested that the experimental fungal infection may indeed indicate a biochemical defect in the hairs from our case of osteogenesis imperfecta. **Key words:** Osteogenesis imperfecta; Brittle hair; Kinky hair; Dermatophyte infection of hair; Experimental; Biochemical defect; Transmission and scanning electron microscopy. (Received April 6, 1984.)

B. Forslind, Department of Medical Biophysics, Karolinska Institutet, P.O. Box 60400, S-104 01 Stockholm, Sweden.

Studies of hair in osteogenesis imperfecta have not been performed previously. A single report on a case of a dominant syndrome resembling osteogenesis imperfecta with alopecia totalis is found in the literature (1). A possible connection between disturbance of hair growth, strength and the pathological sulfur metabolism in the bone collagen of this disease has prompted us to investigate a case using transmission electron microscopy (TEM) on thin sections and scanning electron microscopy (SEM) on small pieces of hair.

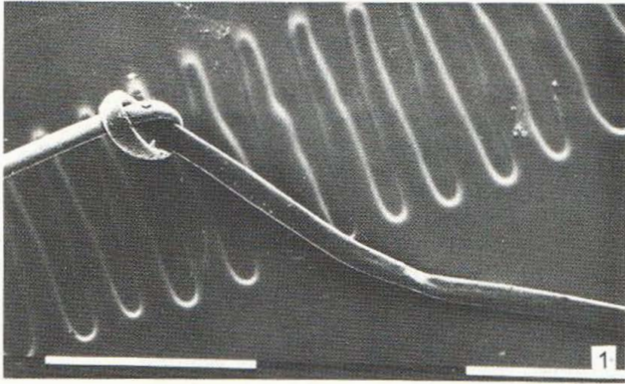
Biochemical assay of hair composition requires a comparatively large volume of hair which patients with hair problems often are reluctant to donate. Normal human hair is extremely difficult to infect with the common fungal strain *Trichophyton mentagrophytes*. As a test for possible biochemical abnormalities in the hair of our case we have inoculated hair fibres with the said organism.

CASE REPORT

The patient is a woman, 39 years old, with blue sclerae, brittle bones and several incidences of fractures since childhood. Fracture healings have been uncomplicated. The skin is prematurely aged but there is no history of skin disease. At consultation symmetrical, patchy alopecia in both temporo-occipital regions were observed. Initially pustules and scaling made the patient visit the clinic. The alopecia areas were not completely denuded, but the remaining hair fibres were kinky. Close inspection revealed that such fibres were also found in non-involved areas. Histopathological findings include changes in the connective tissue collagen a finding in accordance with the diagnosis of osteogenesis imperfecta.

MATERIAL AND METHODS

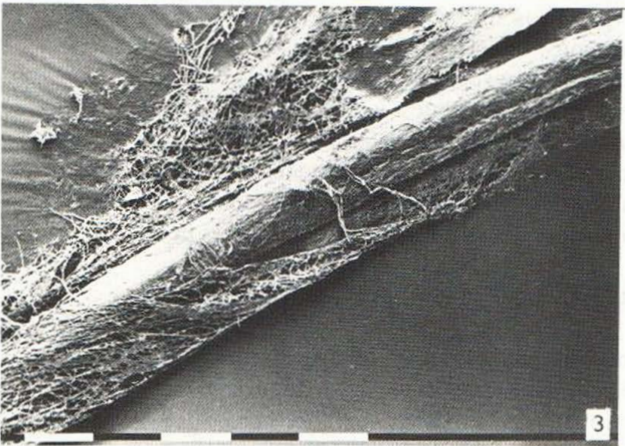
A few strands of hair were plucked from several areas of the scalp (involved and non-involved) with a rubber-coated pair of tweezers. After sterilization at 120°C the hair was inoculated with *T. mentagrophytes* (zoophilic strain) in a sterile water solution with yeast extract added and incubated at 25°C in a constant-temperature box (2).



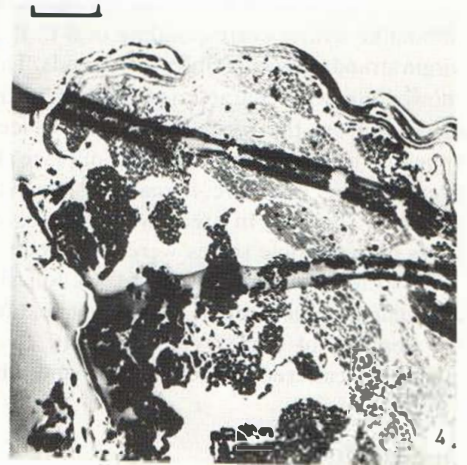1



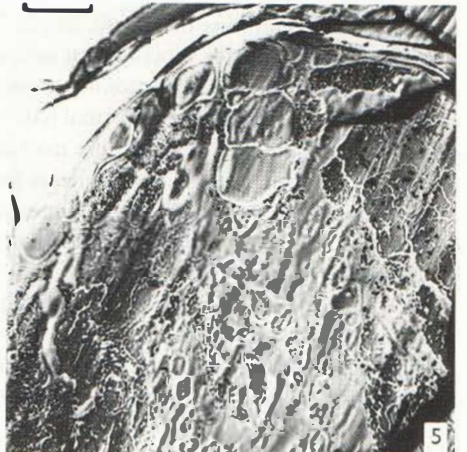2



3



4



5

Fig. 1. The flat, ribbonlike character of the osteogenesis imperfecta hair fibre is especially evident at the knot. White bar: 1 mm.

Fig. 2. Fracture at a kink. Note cuticular scales teased out of place at left. White bar: 0.1 mm.

Fig. 3. Hair from osteogenesis imperfecta with massive overgrowth by *T. mentagrophytes*.

Fig. 4. Virgin hair from osteogenesis imperfecta. This cross section of the hair fibre shows large lacunae corresponding to missing cells. The conspicuous wavy profile of the cuticle is to a certain degree caused by the preparation (cf. Figs. 1 and 2). TEM, black bar: 5 μ m.

Fig. 5. Cross section of fungus-infected hair from osteogenesis imperfecta. In the central, open area mycelia are seen. TEM, black bar: 5 μ m.

The specimens were examined at regular intervals and removed from the medium after one week of incubation. After ocular inspection specimens were transferred to 2.5% glutaraldehyde in a phosphate buffer (0.13 mol) at pH 7.2 and 4°C for 24 hours. A few specimens were post-osmicated in 2% OsO₄ in the phosphate buffer. Dehydration was performed in rising concentrations of alcohol, transfer to propylene oxide and embedding in Epon according to standard procedures. Thin sections (40 nm) cut on an LKB ultratome were stained with uranyl acetate and lead citrate. For SEM short pieces of hair with fungus colonies were transferred from the absolute alcohol to double sided Scotch tape on top of SEM specimen stubs which, after air drying for 24 hours, were sputtered with gold. TEM was performed on a Philips EM 301G at 80 kV, the SEM study on a Philips SEM 505 at 5 kV.

RESULTS

At SEM the hair fibres from osteogenesis imperfecta of our case (Fig. 1) were flat, ribbonlike with a corresponding oval to flat form in the cross section. This was valid for virgin strands as well as infected strands. The cuticular surface structure of the virgin fibres showed no gross characteristics different from those of any normal hair at corresponding distance from the root. However at places single shingles or smaller groups of scales appeared to have been teased out of place (Fig. 2). At fungus infection, *T. mentagrophytes* overgrows the hair fibre, in many instances to an extent where all cuticular structures were obscured (Fig. 3). In areas where the overgrowth is lost at preparation fine perforating holes in the cuticle scales were observed.

At TEM the hair fibre cross section showed an oval form with more or less intact cuticular arrangement. A prominent feature of the cortex was large lacunae created by the absence of cortex cells (Fig. 4). In experimental fungus infection the organisms appeared scattered in such lacunae and inbetween the cuticle scales (Fig. 5).

DISCUSSION

In many hair conditions of genetic origin scalp hair is sparse. Patients reluctantly donate samples of such hair for biochemical investigations, i.e. electrophoresis or for analysis of chemical composition, e.g. atomic absorption spectroscopy as these methods require comparatively large samples. Normal hair is very difficult to infest with dermatophytes but a biochemical defect in the hair fibre may allow such an infection. The structural defects of the hairs from our case of osteogenesis imperfecta suggested such a biochemical defect. The experimental dermatophyte infection successfully obtained suggests that such experimental infections may indeed provide indications for genetically or acquired changes in the biochemistry of hair fibres.

The substantial advantage of the technique is that only a few fibres are required, a loss accepted by most patients.

The possible relation between an abnormal sulfur metabolism in other tissues and a defect sulfur metabolism in the hair follicles corresponding to changed sulfur content of the mature hair fibre is under investigation with physical methods, e.g. PIXE analysis (3), and will be reported elsewhere.

REFERENCES

1. Kääriäinen H, Nono R. A dominant syndrome resembling osteogenesis imperfecta with total alopecia, hoarseness and premature ageing of skin. *Prog Clin Biol Res* 1982; 104: 167-170.
2. Ajello L, Georg L K. In vitro hair cultures for differentiating between atypical isolates of *Trichophyton mentagrophytes* and *Trichophyton rubrum*. *Mycopathologia et Mycologia Applicata* 1957; 9: 3-17.
3. Malmqvist K G, Carlsson L-E, Akselsson K R, Forslind B. PIXE—a new tool in quantitative dermatology. *Scan Electron Microsc* 1983; IV: 1815-1825.