

Skin Manifestations of Tularemia: A Study of 88 Cases in Northern Finland during 16 Years (1967-1983)

HANNU SYRJÄLÄ,¹ JAAKKO KARVONEN,² and AIMO SALMINEN³

Department of ¹Medicine, ²Dermatology and ³Medical Microbiology,
University of Oulu, Oulu, Finland

Syrjälä, H, Karvonen J, Salminen A. Skin manifestations of tularemia. A study of 88 cases in northern, Finland during 16 years (1967-1983). Acta Derm Venereol (Stockh) 1984; 64: 513-516.

88 tularemia patients with secondary skin manifestations seen in northern Finland during 1967-1983 are described in this paper. Tularemia was ulceroglandular in 57% and pulmonary in 27% of the patients. 68% of the patients were women. The most common secondary skin manifestation was papular or vesicopapular eruption which was seen in 42% of the patients. Erythema nodosum either alone or in combination with some other skin eruption was encountered in 28% and erythema multiforme in 9% of the patients. Erythema nodosum was seen more often in patients with pulmonary tularemia than in other types of the disease ($p < 0.01$). The clinical pictures of erythema nodosum and erythema multiforme caused by tularemia greatly resembled those caused by *Yersinia*. Tularemia should be remembered as one possible triggering factor of erythema nodosum and erythema multiforme. (Received April 26, 1984.)

H. Syrjälä, Department of Medicine, University Central Hospital, SF-90220 Oulu 22, Finland.

Tularemia is a zoonosis caused by *Francisella tularensis*, a small gram-negative rod. Man usually contracts tularemia through bites of mosquitos, horse flies and other insects or ticks, through handling infected animals, and, more rarely, by inhalation of infected dust or consumption of infected food or contaminated water. The clinical picture of tularemia depends on the route of infection. Ulceroglandular tularemia with a primary ulcer in the skin and corresponding regional lymphadenopathy is the most common clinical form. The less frequent forms are glandular, oculoglandular, enteral, oropharyngeal and pulmonary tularemia.

Papular lesions, erythema multiforme and erythema nodosum have been described as secondary skin signs of tularemia both in Europe and in the USA (1, 2), but the recent dermatological literature contains very few reports on this topic (3, 4).

In this paper we describe 88 patients with secondary skin manifestations of tularemia seen in northern Finland in 1967-1983.

MATERIALS AND METHODS

Patients

Since 1967, about 1 100 cases of human tularemia have been diagnosed in the Department of Medical Microbiology, University of Oulu. Medical records were available in 560 cases. Skin manifestations obviously due to tularemia were described in 82 cases. In addition, 5 patients were seen at the Department of Dermatology, University of Oulu, and one patient at the Department of Dermatology, North Carelian Central Hospital, Joensuu. The total number of the patients included in this study is hence 88 (28 male and 60 female). Their mean age was 38.3, range 2-70.

Methods

The diagnosis of tularemia was verified serologically in 87 patients, and *Francisella tularensis* was isolated in a guinea pig test from the pus of a primary skin ulcer in one patient. A fourfold or higher rise in the antibody titer was seen in 62 patients, a titer of 1:1280 or more in 17 patients and a titer of 1:640-1:160 with a clinical picture compatible with tularemia in 8 patients.

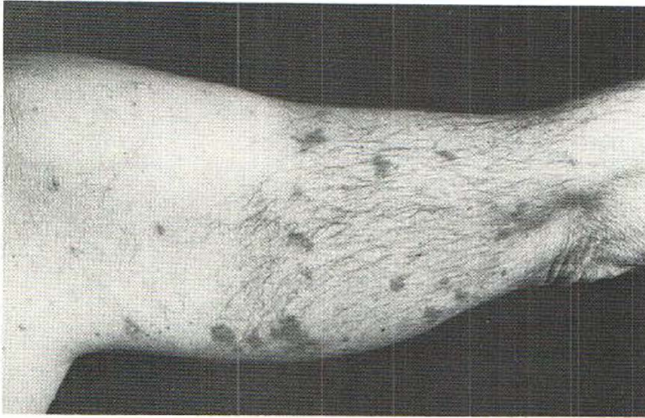

Fig. 1. Papular secondary skin manifestation in a patient with pulmonary tularemia. Typical small papules are seen in the shoulder region. The larger lesion on upper arm closely resembled erythema multiforme.

Skin biopsies for histopathological and immunohistological examination were taken from two patients with papular lesions and one with erythema multiforme.

RESULTS

Out of the 88 patients, 50 had ulceroglandular tularemia, 24 pulmonary, 6 glandular and 2 oropharyngeal tularemia. In 6 cases the type could not be defined with certainty due to defective case records.

The most common secondary skin manifestation was papular or vesicopapular eruption, which was seen in 42% of the patients (Table 1 and Fig. 1). Erythema nodosum alone or in combination with some other skin eruption was seen in 28% and erythema multiforme in 9% of the patients (Fig. 2). Acne-like lesions were seen in 6% and urticarial in 2% of the patients. In 14 (16%) cases it was impossible to determine the type of the skin eruption because of poor descriptions in the case records. The incidence of secondary skin signs was 14% (48 out of 333 patients) during the years 1967–1982. In 1983, patients with skin

Table 1. *The secondary skin manifestations of the 88 patients with tularemia*

Type of skin eruption	Type of tularemia					Total	
	Ulceroglandular	Pulmonary	Glandular	Oropharyngeal	Unknown	No.	%
Papular	24	8	3	—	2	37	42
Erythema multiforme	3	1	—	1	—	5	6
Erythema nodosum	6	10	1	1	1	19	22
Erythema multiforme + Erythema nodosum	2	—	—	—	1	3	3
Erythema nodosum + unidentified	—	2	—	—	1	3	3
Acne-like	3	1	1	—	—	5	6
Urticaria	1	—	—	—	1	2	2
Unidentified	11	2	1	—	—	14	16
Total no.	50	24	6	2	6	88	
Total%	57	27	7	2	7		100

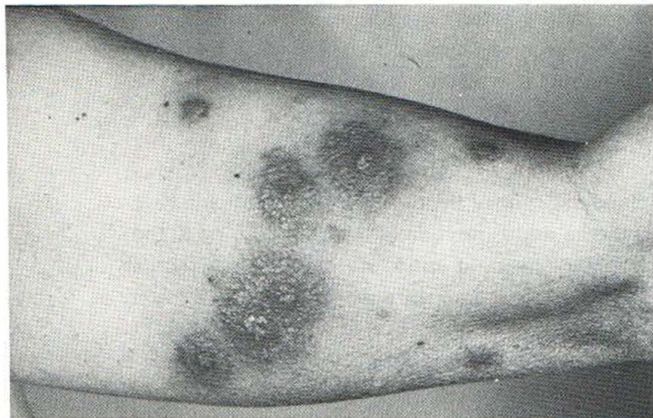


Fig. 2. Erythema multiforme in upper arm of a patient with oropharyngeal tularemia. The lesions are large, oedematous and in some areas almost blistering.

signs were specially looked for, and these patients were therefore excluded from the calculations of incidence.

Erythema nodosum was seen in 12 (50%) of the 24 patients with pulmonary tularemia compared with 8 (16%) of the 50 patients with ulceroglandular tularemia. The difference is significant ($p < 0.01$). Otherwise the type of eruption did not seem to correlate with the clinical type of tularemia.

The time from the onset of tularemia till the appearance of secondary skin eruptions varied from three days to several weeks, the median being 11 days. In papulotic lesions the interval was shorter (median 8 days) than in erythema nodosum (median 12.5 days).

The papular or vesicopapular eruptions were usually itchy and most often located in the legs and the arms. Most of the papules disappeared at the end of the second week. Erythema nodosum lesions were usually seen in the legs only, but some patients had lesions in their arms as well. The number of lesions varied from a few to so many that they nearly covered the legs. Erythema nodosum usually disappeared within two weeks. Erythema multiforme lesions were seen both in the trunk and in the extremities, but peripheral localisation in the hands and the feet was not as common as usually in erythema multiforme. The lesions were seen more often in the upper back, in the shoulders and in the proximal parts of the upper arms. The lesions usually disappeared within two weeks, but in one patient erythema multiforme lasted for six weeks. In three patients erythema nodosum occurred concomitantly with erythema multiforme. In one patient erythema multiforme was limited almost exclusively to the sun-exposed areas of skin.

Neutrophilic leukocytoclastic vasculitis was seen in one of the two biopsies from papular eruptions. In the remaining two biopsies a nonspecific perivascular lymphocytic infiltration was seen. Immunohistopathological examination showed deposits of IgM and C3 in the dermal vessels in one of the three patients studied, but otherwise the immunohistological findings remained negative.

DISCUSSION

In this study the incidence of secondary skin manifestations was 14%. This figure is obviously too low, because in a retrospective study like this, mild and limited skin eruptions have certainly been neglected by both the patients and the physicians. But the incidence is in accordance with the earlier reports, where it has varied from 8 to 35% (5, 6). The distinct female predominance seen in this material as well as in that described by Kleibel (1) is also seen in secondary skin signs caused by *Yersinia* (7) and in erythema

nodosum of various aetiologies (8). The reason for this female predominance is not known.

In our material, papular and vesicopapular eruptions constituted the most common secondary skin manifestation, which is in agreement with the other reports (9, 10). The localization in the sun-exposed areas in one patient was a new finding.

Erythema nodosum was seen in 28% of our patients, which exceeds clearly the frequencies recorded earlier (1-3, 6, 9-11). Pulmonary tularemia preceded erythema nodosum more commonly than the ulceroglandular type of the disease. A systemic disease might be a stronger triggering factor for erythema nodosum than in infection limited to the skin and the regional lymph nodes only. The short duration of tularemia erythema nodosum, usually two weeks or less, as well as the clinical appearance and the distribution of the lesions are also typical of erythema nodosum caused by *Yersinia*, but are different from the erythema nodosum nodules seen in connection with other diseases, e.g. sarcoidosis and streptococcal infections (8).

Erythema multiforme triggered by tularemia also greatly resembles that seen in yersiniosis (7). Both are often located in the shoulder region and the duration is about two weeks. The individual lesions are often clearly oedemic or even vesicular and usually fairly large, with diameters up to 3-4 cm. In our patients the frequency of erythema multiforme was smaller than earlier reported (1, 6). Simultaneous occurrence of both erythema multiforme and erythema nodosum, which was seen in three of our patients, has earlier been reported to occur in tularemia (1), yersiniosis (7) and occasionally also in other diseases (12).

As the clinical pictures of erythema nodosum and erythema multiforme in tularemia and in yersiniosis are nearly alike, it is surprising that the papular skin eruption so often seen in tularemia has not been reported to occur in yersiniosis. A possible explanation for this difference is that the participation of immune defence mechanisms of skin and the superficial lymph nodes might be essential for the appearance of secondary papular skin eruptions. This mechanism could be activated often in ulceroglandular tularemia, fairly seldom in pulmonary tularemia and rarely, if ever, in yersiniosis.

We conclude that papular eruption, erythema nodosum and erythema multiforme are typical secondary skin manifestations of tularemia. Tularemia should be included in the list of disease to be suspected in patients with erythema nodosum or erythema multiforme.

REFERENCES

1. Kleibel K. Les tularémides. Erythèmes polymorphes et érythèmes nouveaux tularéques. *Med Mal Infect* 1971; 1: 447.
2. Hitch JM, Smith DC. Cutaneous manifestations of tularemia. *Arch Dermatol* 1938; 38: 859.
3. Galle R, Chervonaz B, Texier J. Tularémie a forme nodulaire cutanée. Tularémides nouvelles. *Ann Dermatol Venerol (Paris)* 1982; 109: 767.
4. Lewis JE. Suppurative inflammatory eruption occurring in septicemic tularemia. *Cutis* 1982; 30: 92.
5. Pullen RL, Stuart BW. Tularemia. Analysis of 225 cases. *JAMA* 1945; 129: 495.
6. Dahlstrand S, Ringertz O, Zetterberg B. Airborne tularemia in Sweden. *Scand J Infect Dis* 1971; 2: 7.
7. Hannuksela M, Ahvonen P. Skin manifestations in human yersiniosis. *Ann Clin Res* 1975; 7: 368.
8. Hannuksela M. Erythema nodosum with special reference to sarcoidosis. *Ann Clin Res* 1971; 3, Suppl. 7.
9. Kavanaugh CN. Tularemia. A consideration of one hundred and twenty-three cases, with observation at autopsy in one. *Arch Intern Med* 1945; 55: 61.
10. Foshay L. Tularemia: A summary of certain aspects of the disease including methods for early diagnosis and the results of serum treatment in 600 patients. *Medicine* 1940; 19: 1.
11. Tielsch R. Über die exanthematischen Hauterscheinungen bei Tularämie. *Klinische Medizin* 1960; 15: 447.
12. Moreno AJ, Weisman I, Kennedy RL, Fort SL. Concurrence of erythema multiforme and erythema nodosum. *Cutis* 1983; 31: 275.