

## Skin Uptake of Gallium 67 in Cutaneous Sarcoidosis

P. M. HUISMAN<sup>1</sup> and E. A. VAN ROYEN<sup>2</sup>

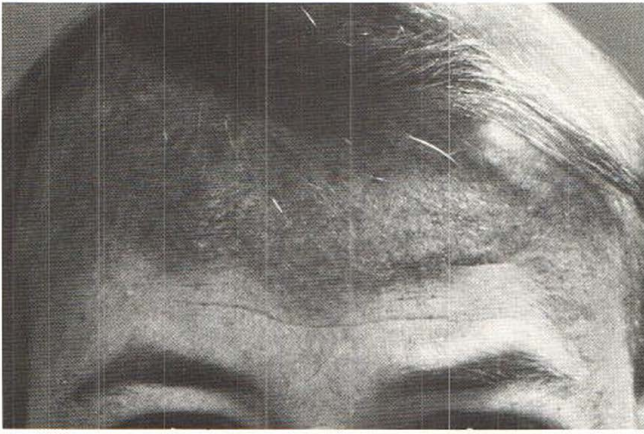<sup>1</sup>*Department of Dermatology and* <sup>2</sup>*Department of Nuclear Medicine, Academic Medical Center, Meibergdreef 9, 1105 AZ Amsterdam, The Netherlands*

Huisman PM, van Royen EA. Skin uptake of Gallium-67 in cutaneous sarcoidosis. *Acta Derm Venereol (Stockh)* 1985; 65: 243–247.

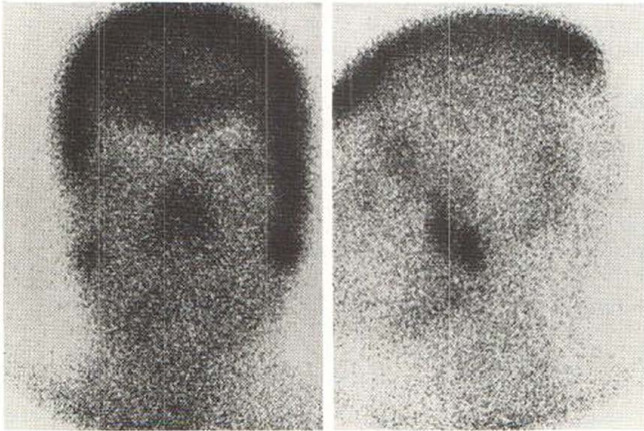
A patient is presented with cutaneous sarcoidosis of the scalp. Ga-67 was intensively taken up by the skin lesions. Systemic involvement of parotid glands and mediastinum was also demonstrated by Ga-67 scintigraphy. Prednisolone therapy reversed promptly the pathologic Ga-67 uptake. Ga-67 scintigraphy should be performed in all patients suffering from cutaneous sarcoidosis as being the most sensitive method to demonstrate systemic involvement. *Key words: Sarcoidosis; Scintigraphy; Prednisone therapy.* (Received October 3, 1984.)

P. M. Huisman, Department of Dermato-Venereology, Academisch Medisch Centrum, Meibergdreef 9, 1105 AZ Amsterdam, The Netherlands.

Gallium 67 (Ga-67) scintigraphy is a valuable tool in the diagnosis and follow-up of patients suffering from pulmonary sarcoidosis (1, 2, 3). The degree of Ga-67 uptake in the lungs reflects disease activity closely as assessed clinically (4), by biopsy (5) or by biochemical markers like lysozyme, angiotensin-converting enzyme (6).



*Fig. 1 a.* The patient before treatment. The indurated plaques and alopecia are clearly to be seen.



*Fig. 1 b.* Gallium-67 scintigraphy: Anterior (left) and lateral (right) view of the head demonstrating intensive Ga-67 activity in skin and parotid gland.

Uptake of Gallium 67 in extrathoracic structures is often noticed especially in lymph nodes and parotid glands. In the following we describe the intense uptake of Ga-67 in the skin of a patient suffering from cutaneous sarcoidosis of the scalp and its reversal by corticosteroid therapy.

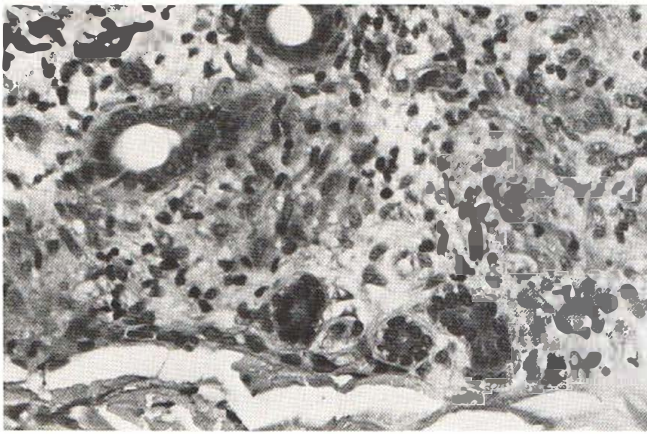
#### CASE REPORT

A 26-year-old man presented with indurated, purple plaques on the forehead and part of the scalp. The scalp was covered with yellow crustae (Fig. 1 a). In between those plaques atrophy of the skin was seen. The diseased skin showed a severe alopecia. On the dorsum of the left foot a purple macule was present. There was no history of dyspnea, coughing or wheezing. He was taking no medication. Apart from the cutaneous lesions general examination was unremarkable.

Both lesions were biopsied and showed large polycyclic epithelioid granulomas with foci of giant cells and some lymphocytes. No necrosis or caseation was present (Fig. 2). The epithelioid cells clearly appeared to contain lysozyme and  $\alpha_1$ -antitrypsin as demonstrated by special staining. These findings were highly suggestive of sarcoidosis.

Further investigation showed a neutrophilia and a lymphopenia (white cell count  $5.3 \times 10^9/l$  78.9% neutrophils, 10.5% lymphocytes, 8.9% monocytes). The haemoglobin and the ESR were normal. The creatinine, transaminases, LDH, alkaline phosphatase, total protein and protein electrophoresis were also normal.

The ACE (angiotensin converting enzyme) was highly abnormal: 430 U/l (normal less than 52 U/l).



*Fig. 2.* PA: Clusters of large plump epithelioid cells without caseation necrosis. Some lymphocytes at the periphery of tubercles.

The lysozyme was also abnormal: 4.2 mg/l (normal 2.0–2.2 mg/l). A chest X-ray and an X-ray of the hands showed no abnormalities.

Thereafter Ga-67 scintigraphy was performed in order to exclude pulmonary involvement. 48 h after the injection of 2 mCi of Ga-67 citrate, images were obtained with a gamma-camera. Routinely we perform anterior and posterior views of the chest, but also of the head to assess parotid gland activity. The image of the head demonstrated intense Ga-67 uptake in the scalp matching exactly the affected skin (Fig. 1 *b*). Apart from skin activity, increased activity was found in parotid glands and mediastinum, indicating systemic disease.

The final conclusion was that this patient was suffering from sarcoidosis of the skin but also of parotid glands and mediastinum. Treatment with prednisolone was instigated; the first week 40 mg daily, the second week 35 mg and so on until the sixth week after which the daily dosis was kept at 15 mg. Gradually the skin lesions cleared. Fig. 3 *a* shows the patient after six weeks of treatment.

Ga-67 scintigraphy was repeated after three weeks (Fig. 3 *b*). There was a complete clearance of activity in the skin, while parotid gland activity was strongly diminished and no mediastinal activity was found, ACE and lysozyme levels declined also after therapy.

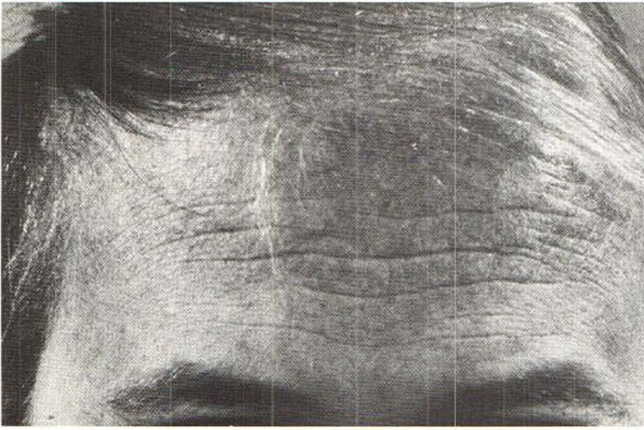
## DISCUSSION

A dermatological manifestation of sarcoidosis is reported in 10–35 % of cases of sarcoidosis (7, 8).

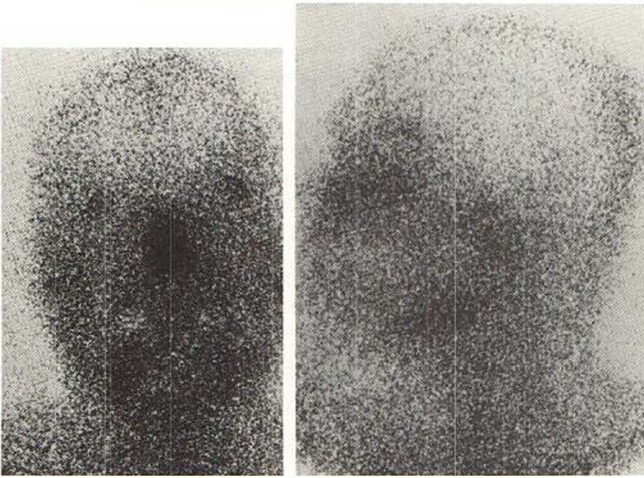
The diagnosis is established by clinical appearance and biopsy as was done in our patient. Systemic involvement is reported in about 50% of the patients presenting primarily with cutaneous sarcoidosis (9). Besides X-ray of the chest, measurement of ACE and lysozyme, we perform routinely Ga-67 scintigraphy of the thorax in these patients as a reliable tool to establish or reject pulmonary involvement. As a consequence of the findings in the patient presented, we reviewed retrospectively Ga-67 scintigraphy made in patients primarily presenting with cutaneous sarcoidosis. We found increased lung and hilus activity in 5 out of 5 patients. This demonstrates to our opinion the sensitivity of Ga-67 scintigraphy and its superiority to X-ray of the chest (9) and the ACE assay (10) in assessing systemic involvement in these patients.

We did not focus the gamma camera on the skin lesions in these patients although there has been one report of Ga-67 uptake in the skin (11). By chance we observed the intense Ga-67 uptake in the affected skin of the head. In parallel to a rapid healing of the skin lesions after institution of prednisolone therapy, also the Ga-67 activity in the skin disappeared.

The uptake of Ga-67 in the skin lesion of sarcoidosis raises an interesting question about



*Fig. 3 a.* The patient after six weeks therapy with Prednisolone.



*Fig. 3 b.* Gallium-67 scintigraphy after therapy: Anterior (left) and lateral (right) view of the head. Ga-67 activity in skin and parotid gland has disappeared almost completely.

its mechanism. It has been suggested that in the alveolitis of sarcoidosis the Ga-67 uptake reflects the intensity of the T-lymphocyte mediated component (12). However, the cutaneous lesions of sarcoidosis in our patients were characterized by scarce lymphocyte infiltration and consisted mainly of epithelioid granulomas. Skin biopsy and autoradiography of the tissue in patients with cutaneous sarcoidosis undergoing Ga-67 scintigraphy may offer a unique, relative non-invasive method to study the mechanism of Ga-67 uptake in sarcoidosis.

#### ACKNOWLEDGEMENT

We are indebted to P. Bakker, M.D. for his helpful comments on the histology.

#### REFERENCES

1. Schoot JB van der, van Marle-van der Goot M, Groen AS, de Jong J. Gallium-67 scintigraphy in benign lung disease. *Medical Radioisotope Scintigraphy*. Monte Carlo IAEA-SM 1972; 164/219: 633-640.
2. Beaumont D, Herry JY, Le Cloirec J, le Jeune JJ, de Labarthe B. Sensitivity of Gallium 67-scanning in sarcoidosis: Detection of biopsy proven pulmonary lesions radiographically undetectable. *Eur J Nucl Med* 1982; 7: 41-43.

3. Alberts Chr, Schoot JB van der, Groen AS. Gallium 67 scintigraphy as an index of disease activity in pulmonary sarcoidosis. *Eur J Nucl Med* 1981; 6: 205-212.
4. Siemens JK, Grebe SF, Sargent EN. Gallium-67 scintigraphy of pulmonary diseases as a complement to radiography. *Radiology* 1976; 118: 371-375.
5. Niden AH, Mishkin FS, Khurana ML. Gallium 67 citrate lung scans in interstitial lung disease. *Chest* 1976; 69: 266-268.
6. Alberts Chr, Van der Schoot JB, Van Datselaar JJ, Braat MCP, Roos CM. Gallium 67 scintigraphy, serum lysozyme and angiotensin-converting enzyme in pulmonary sarcoidosis. *Eur J Resp Dis* (in press).
7. Elgart M. Cutaneous lesions of sarcoidosis. *Primary Care* 1978; 5: 249.
8. Sharma OP. Cutaneous sarcoidosis: clinical features and management. *Chest* 1972; 61: 320.
9. Hanno R, Callen JP. Cutaneous sarcoidal granulomas and the development of systemic sarcoidosis. *Arch Dermatol* 1981; 117: 203.
10. Callen JP, Hanno R. Serum angiotensin I-converting enzyme level in patients with cutaneous sarcoidal granulomas. *Arch Dermatol* 1982; 118: 232.
11. Crystal G. Pulmonary sarcoidosis: A disease characterized and perpetuated by activated lung T-lymphocytes. *Ann Intern Med* 1981; 94: 73-94.
12. Lopez-Majano V, Sansi P. Gallium 67 uptake in cutaneous sarcoidosis. *Eur J Nucl Med* 1982; 7: 95.