

## **Familial Rolled and Spiral Hairs with Palmoplantar Keratoderma**

J. P. ORTONNE,<sup>1</sup> L. JUHLIN,<sup>1</sup> P. EL BAZE<sup>1</sup>  
and G. PAUTRAT<sup>2</sup>

*<sup>1</sup>Department of Dermatology, University of Nice, and <sup>2</sup>Centre International de Recherches Dermatologiques, Sophia Antipolis, Valbonne, France*

Ortonne JP, El Baze P, Juhlin L, Pautrat G. Familial rolled and spiral hairs with palmoplantar keratoderma. *Acta Derm Venereol* (Stockh) 1985; 65: 250-254.

A 59-year-old man with palmoplantar keratoderma and rolled spiral hairs on the abdomen and extremities is reported. His father had the same skin manifestations but his brother and sister only keratoderma palmoplantare. Scanning electron microscopy of the rolled hairs showed that they were coiled in a spiral around their own axis. These spiral hairs had lower

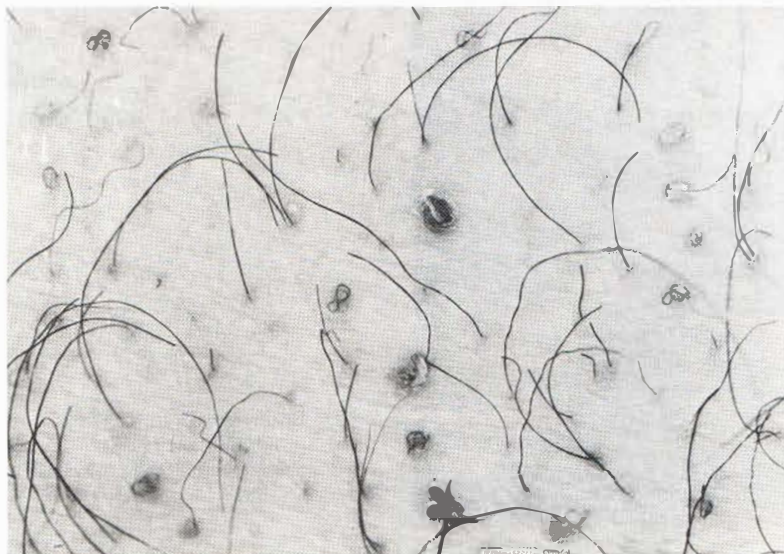

Fig. 1. Rolled hairs in hyperkeratotic follicles.

cysteine than the normal appearing hairs on the body. The scalp hair appeared normal but was low in cysteine which was compensated by an increase in threonine. Urine analysis showed a decrease of cysteine. *Key words: Spiral hair; Cysteine deficiency; Scanning electron microscopy.* (Received September 26, 1984.)

J. P. Ortonne, Service de Dermatologie, Hôpital Pasteur, 30 Ave de la Voie Romaine, F-06031 Nice, France.

Rolled hairs on the abdomen, shoulders and extensor part of the extremities have been reported in 5 patients with dry skin having treatment with oral corticosteroids. Cushing's disease or juvenile hypothyroidism (1 and 4). The patients had keratotic changes around the hair follicles. Rolled hairs have also been reported in 2 patients with neurodermatitis and in some patients who were otherwise healthy (1, 2, 5). Most of the patients are men

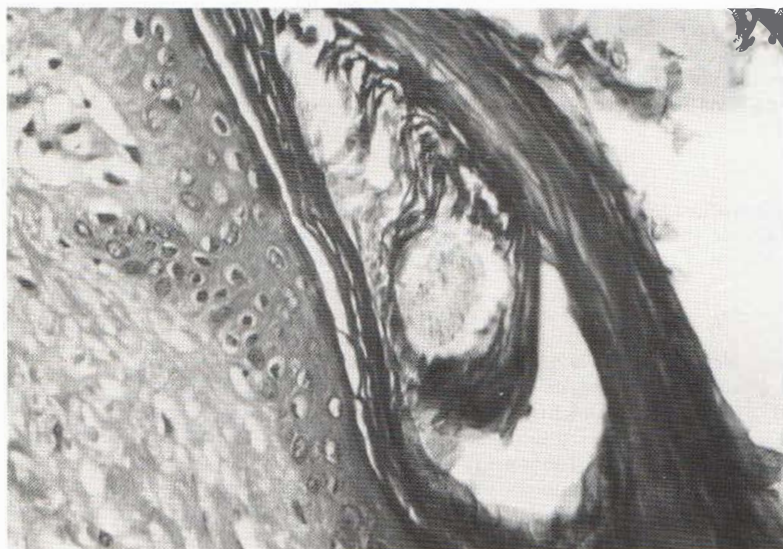



Fig. 2. A biopsy from the abdomen with an abnormal hair follicle and a rolled hair under the stratum corneum.



*Fig. 3.* Scanning electron microscopy showing a normal hair and the smaller rolled hairs indicated by arrows (▶). Bar below shows length of 100  $\mu\text{m}$ ; 20 kV.

over 50 years of age. The hairs which have penetrated the stratum corneum sometimes appear to be coiled as a spiral. We here report studies of a patient, member of a family, where rolled and spiral hairs occurred in two members together with keratoderma of palms and soles.

#### CASE REPORT

The patient is a 59-year-old man who was referred to the dermatology service in Nice for a plantar infection. The investigation revealed signs of a left-sided hemiplegia, alcoholic cirrhosis, and diabetes. Except for the increase of glucose routine laboratory examinations were normal as were W rays of the skeleton. His tissue group was A29, XI B7 B12.

#### *Skin manifestations*

On the palms and soles he had several 7–16 mm diameter round hyperkeratosis which had been present since childhood. On the thorax, abdomen and extensor surface of upper arm and legs he had normal appearing hairs as well as shorter hairs growing in a spiral form and coming out from hyperkeratotic, slightly elevated brown-coloured hair follicles (Fig. 1). He had observed these hairs for some years. The patient's father, brother and sister had a similar palmo-plantar keratoderma. His father also had spiral hairs. The hairs on scalp, eye brows and eyelids appeared normal as well as teeth and nails.

#### *Histology*

The palmo-plantar lesions showed a marked lamellar hyperkeratosis with a thick granular layer and acanthosis. A biopsy from the abdomen showed a follicular hyperkeratosis with horizontally rolled hair shafts under the stratum corneum. Cross-sections of hairs were commonly seen under the stratum corneum (Fig. 2).

#### *Scanning electron microscopy*

The biopsy was fixed in 2.5% glutaraldehyde in PBS at 4°C for 24 hours. It was then rinsed in PBS, dehydrated in 30, 50, 70 and 90% graded alcohol and critical point dried before sputtering with gold. Pictures were taken in a Jeol T300 scanning electron microscope using 20 kV. Coiled hairs were seen under the stratum corneum (Fig. 3). Hairs which passed through the corneal layer were turned in a spiral giving them an abnormal appearance like a twined thread (Fig. 4). A cross-section of the hair confirmed that it was a single hair which was twisted around its own axis.

Amino acid analysis of the spiral hairs showed a decreased content of cysteine and an increase of glycine when compared to normal appearing hairs on the body (Table I). The scalp hair of our patient

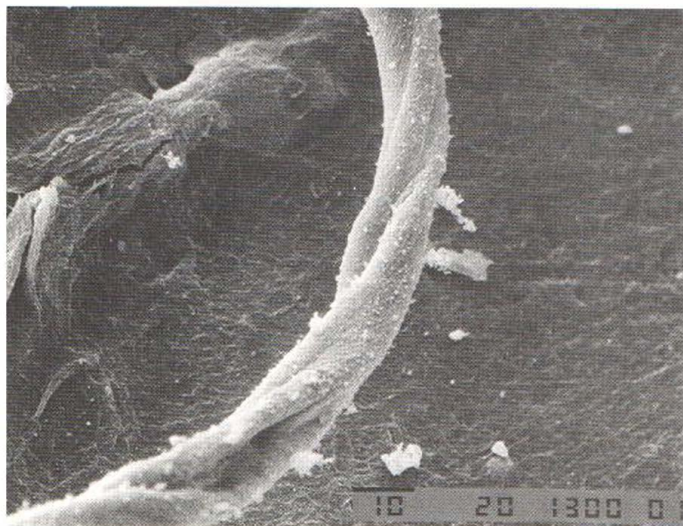


Fig. 4. Detail of a rolled hair showing that it is twisted in a spiral. Bar below indicates length of 10  $\mu$ m; 20 kV.

had low cysteine and high threonine levels. Amino acid analysis of urine showed a decreased level of cysteine (6 micromol/24 hours) and a 13 times increase of ornithine (125 micromol/24 hours) when compared to urine from healthy subjects.

## DISCUSSION

The clinical picture and histology of the rolled hairs studied by us are similar to those earlier published (1-6). Our patient's father also had rolled hairs and hereditary palmo plantar keratoderma suggesting a link between the two disorders. Kanerva et al. (5)

Table I. Percentage amino-acid residues in hair

	Patient		Healthy subjects, N=4	
	Normal body hair	Spiral hair	Scalp hair	Scalp hair
Lys.	3.5	4.9	3.7	3.4-3.7
His.	3.9	3.2	0.4	0.5
NH <sub>3</sub>	8.7	9.7	15.5	7.4-11.1
Arg.	5.9	3.8	7.2	5.8-6.6
Asp	5.3	6.5	9.3	5.0-6.0
Thr	5.3	4.8	15.3	6.9-7.6
Ser	12.6	15.4	14.7	10.6-11.6
Glu	11.9	13.4	8.1	12.1-12.7
Pro	7.6	4.2	8.5	7.2-8.3
Gly	7.0	14.7	5.8	5.5-6.4
Ala	4.6	5.6	4.4	4.5-4.6
Cys	17.2	6.6	1.3	16.9-17.6
Val	5.8	4.3	6.5	5.6-5.8
Met	0.4	0.6	0.6	0.4-0.5
Ileu	2.8	2.6	3.5	2.5-2.7
Leu	6.0	5.3	7.1	5.9-6.5
Tyr	2.0	2.0	1.6	1.4-1.6
Phe	1.7	2.1	2.0	1.6-1.8

demonstrated by scanning electron microscopy how the hairs were rolled like a sleeping serpent in the follicle under the stratum corneum. The extracted hair had a normal appearance of the hair cuticle. The hairs of our patient were often rolled and the free part was sometimes coiled like a spiral when seen by the naked eye. It was, however, also markedly twisted in a spiral around its own axis thus making the surface abnormal (Fig. 4). Amino acid analysis showed that the spiral hairs had less cysteine than the normal appearing hairs on his body. A decrease of cysteine in scalp hair and of cystine in urine could indicate a deficiency of amino acids. A decrease of such sulfur containing amino acid has been observed in patients with trichthiodystrophy with neuroectodermal symptoms (7). Urine analysis of such patients are however normal. The normal appearance of the patients scalp hair could be due to the finding that the cysteine decrease here was compensated by an increase of threonine which is also rich in sulfur.

## REFERENCES

1. Ferguson AG, Derblay PR. Rolled hairs. *Arch Dermatol* 1963; 87: 311-314.
2. Koga M, Shimada H. Rolled hairs. *Rinsho Derma (Tokyo)* 1974; 16: 1055-1062.
3. Kanerva L, Niemi KM, Lassus A, Rantanen T. Scanning electron microscopic visualization of rolled hair (poils en spirale). *Acta Derm Venereol (Stockh)* 1983; 64: 61-64.
4. Maekawa Y, Kito M, Hiramatsu R. Rolled hairs and hypertrichosis. *J Dermatol* 1983; 10: 157-160.
5. Adatto R. Pils en spirale (poils enroulés). *Dermatologica* 1963; 127: 145-147.
6. Unna PG. *Histopathologie der Hautkrankheiten*. Berlin: Hirschwald, 1894: 292.
7. Price VH, Odom RB, Ward WH, Jones FT. Trichothiodystrophy. Sulfur-deficient brittle hair as a marker for a neuroectodermal symptom complex. *Arch Dermatol* 1980; 116: 1375-1384.