

4. Agrup G, Sjöstedt L. Contact urticaria in laboratory technicians working with animals. *Acta Derm Venereol (Stockh)* 1985; 65: 111-115.
5. Registration of allergen preparations, Nordic guidelines. NLN publication No 7, Nordic Council on Medicines. Uppsala, Sweden, 1982.
6. Lowry OH, Rosenbrough NJ, Farr AL, Randall RJ. Protein measurement with the Fohlin phenol reagent. *J Biol Chem* 1951; 193: 265-275.
7. Bensadoun A, Weinstein D. Assay of proteins in the presence of interfering materials. *Anal Biochem* 1976; 70: 241-250.
8. Yman L, Ponterius G, Brandt R. RAST-based allergen assay method. *Develop Biol Stand* 1975; 29: 151-165.
9. Løwenstein H. Quantitative immunoelectrophoretic methods as a tool for the analysis and isolation of allergens. *Progr Allergy* 1978; 25: 1-62.

Reticular Erythematous MucinosiS Syndrome in a Patient with PolyarthritiS

B. A. C. DIJKMANS,¹ W. BERGMAN,² F. EULDERINK³
and K. A. E. MEIJERS¹

¹Department of Rheumatology, ²Department of Dermatology and ³Department of Pathology, University Hospital, Leiden, The Netherlands

Dijkmans BAC, Bergman W, Eulderink F, Meijers KAE. Reticular erythematous mucinosiS syndrome in a patient with polyarthritiS. *Acta Derm Venereol (Stockh)* 1986; 66: 442-445.

A patient with seronegative oligoarthritiS who developed the reticular erythematous mucinosiS (REM) syndrome is described. This syndrome is considered to be a dermatological entity unrelated to systemic disorders. Aggravation of the rash by exposure to sunlight and a good response to anti-malarial agents suggest a relationship with rheumatological disorders, e.g. rheumatoid arthritiS and systemic lupus erythematosus. Dermatologists consulted by a patient with the REM syndrome should be aware of the possibility of an associated rheumatological disease. (Received January 15, 1986.)

B. A. C. Dijkmans, Department of Rheumatology, University Hospital, P.O. Box 9600, 2300 RC Leiden, The Netherlands.

The reticular erythematous mucinosiS (REM) syndrome is a relatively new dermatological entity characterized by a net-like, reddish blue, somewhat infiltrated rash on the chest, upper back, neck, or abdomen (1). Microscopical examination of biopsy specimens shows a perivascular lymphocytic infiltrate and characteristic dermal deposits staining non-metachromatically with Alcian blue (1). At present about 50 cases of REM syndrome can be found in the literature (2). This disease is not known to be related to systemic disorders. However, the aggravation of the rash by exposure to sunlight (1, 3) as also seen in lupus erythematosus, and the response to treatment with antimalarial agents (1, 3) as seen in rheumatoid arthritiS and cutaneous features of lupus erythematosus, suggest a relationship with rheumatological disorders.

The following report of a patient with seronegative oligoarthritiS who developed a REM syndrome supports this hypothesis.

CASE REPORT

A previously healthy 36-year-old Caucasian man came to our out-patient clinic in December 1984 because some of his joints were painful and tender. Two and a half months earlier after an attack of "flu", he had developed these symptoms in the left mandibular joint, metatarsophalangeal joints II,

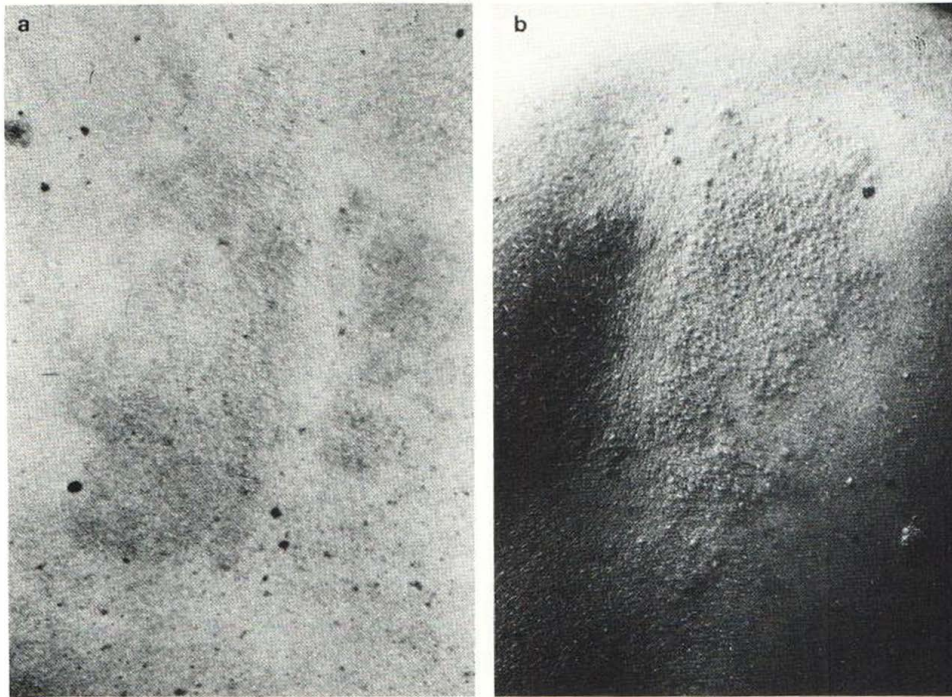


Fig. 1. Areas of pink reticulate erythema are present on the skin of the middle part of the upper back (a). These areas are infiltrated, as shown by floodlight photography (b).

III and IV of both feet, and the proximal interphalangeal joint IV of the right hand. He also had morning stiffness which woke him early in the morning and lasted for an hour. The anamnesis disclosed no further abnormalities, in particular neither diarrhea nor inflammation of the eyes.

On examination the patient was a healthy male with a height of 181 cm and weighing 82 kg. The pulse rate was 68/min, the blood pressure 160/100 mmHg. Examination showed no skin abnormalities or lymphadenopathy. The heart and lungs were normal. The liver was not enlarged and the spleen was not palpable. Ecoulement was absent and there were no ophthalmological abnormalities. On pressure pain was felt in the above-mentioned joints, and tangential joint pressure gave pain in the metatarsophalangeal joints of both feet. Examination of the back disclosed no abnormalities.

The erythrocyte sedimentation rate was 6 mm (Westergren) in the first hour, haemoglobin was 9.5 mmol/l, and the white blood cell count was $7.7 \times 10^9/l$ with normal differentiation. The Waaler-Rose and latex fixation tests were negative and antinuclear factors absent.

Liver, kidney and thyroid function tests were normal, as was the serum iron value. The results of urinalysis were normal. The HLA-B27 antigen was absent. Radiographs of the chest, hands, feet and pelvis were normal.

At that time, a diagnosis of seronegative oligoarthritis was made, HLA-B27 negative, without further classification, and the patient was treated with indomethacin.

In January 1985 the patient developed a red, infiltrated erythematous lesion, 20 cm in diameter between the scapulae (Fig. 1). On the basis of this clinical picture, the diagnosis of REM syndrome was made. A biopsy specimen of skin from the lesion supported this diagnosis (Fig. 2). Microscopy showed infiltration of lymphoid cells around small vessels, mainly in the upper dermis and around a hair follicle. The papillary dermis had a particularly loose stroma and showed intense staining with Alcian blue. In March 1985 the patient developed urethritis. Since culture of urethral fluid showed no chlamydiae or bacteria (including gonococci), incomplete Reiter's syndrome seemed to be the most likely diagnosis. Exposure to solar radiation led to slight aggravation of the skin lesion. Anti-malarial therapy was not instituted.

The oligoarthritis improved during the treatment with indomethacin; in June 1985, treatment with indomethacin was stopped. In August almost no signs of arthritis were present and the urethritis had completely disappeared, but the skin lesion was unchanged.

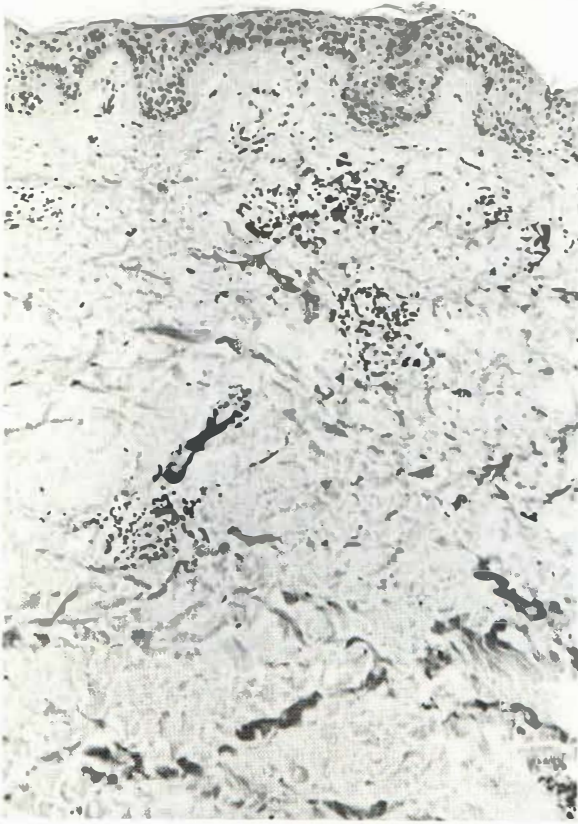


Fig. 2. Micrograph of a section of biopsied skin showing perivascular round cell infiltrates in the dermis. The latter has an edematous appearance due to the mucinosis. Haematoxylin and eosin, $\times 65$.

DISCUSSION

The REM syndrome is considered to be a clinico-histological entity with involvement restricted to the structure of the skin (1). This view has been supported by the case histories of almost all of the patients, who were otherwise healthy. However, one patient with joint pain has been reported (4) as well as one with chronic uveitis of unknown etiology (5). Uveitis is associated with many systemic diseases, including ankylosing spondylitis (6). The present case history of a patient with polyarthritis and the REM syndrome suggests a possible relationship between this syndrome and a rheumatologic disorder; however, we were unable to exclude completely a skin reaction to indomethacin. The suggestion of a relationship between the REM syndrome and a rheumatological disorder is supported by reports describing photosensitivity in the REM syndrome (1, 3), as seen in systemic lupus erythematosus, as well as the response to treatment with anti-malarial agents. However, the histological picture of lupus erythematosus differs from that of the REM syndrome (7). In the latter the epidermis appears normal, but a variable dense perivascular and sometimes also perifollicular lymphocytic infiltrate is present (7). This infiltration occurs primarily in the superficial dermis but may also reach deeper layers (7). In addition, there is a more or less pronounced edema of the dermal connective tissue (7). According to some authors the looseness of the dermis associated with the REM syndrome is caused by deposition of acid mucopolysaccharides (5, 8). Since such deposits

were not found in all of the patients with clinical REM syndrome, the question arose whether this syndrome is a form of mucinosis or is histologically related to known inflammatory skin diseases but has a specific clinical expression (7).

Features of seronegative oligoarthritis have been described as components of Reiter's syndrome and reactive arthritis. Moreover, seronegative oligoarthritis is associated with psoriasis (9) and inflammatory bowel conditions such as ulcerative colitis and Crohn's disease (10). A variety of dermatological abnormalities have been described in the latter disease, for example erythema nodosum, aphthous stomatitis, and pyoderma gangrenosum (10). On the one hand, because of the benign course of the REM syndrome, this dermatological abnormality can easily be overlooked by gastroenterologists and rheumatologists, and on the other hand, dermatologists consulted by a patient with a REM syndrome should be aware of the possibility of a rheumatological disorder.

ACKNOWLEDGEMENT

The authors are greatly indebted to Hanny Hins for typing the manuscript.

REFERENCES

1. Steigleder GK, Gartmann H, Linker U. REM syndrome: reticular erythematous mucinosis (round-cell erythematosis), a new entity? *Br J Dermatol* 1974; 91: 191-199.
2. Boer EM de, Nieboer C, Pluis AHG, Verburgh-Van der Zwan N, Van Dijk E. Reticulaire erythemateuze mucinosis. *Ned Tijdschr Geneesk* 1983; 127: 668-671.
3. Balogh E, Nagy-Verzékény K, Fórizs E. REM syndrome: an immediate therapeutic response to hydroxychloroquine sulphate. *Acta Derm Venereol (Stockh)* 1980; 60: 173-175.
4. Kocsard E, Munro VF. Reticular Erythematous Mucinosis (REM syndrome) of Steigleder: its relationship to other mucinosis and to chronic erythemas. *Austr J Dermatol* 1978; 19: 121-124.
5. Smith NP, Sanderson KV, Crow KD. Clinical meeting of the St. John's Hospital Dermatological Society: 5 June 1975. Reticular erythematous mucinosis syndrome. *Clin Exp Dermatol* 1976; 1: 99-103.
6. Van der Linden S, Valkenburg HA, Cats A. Is uveitis associated with ankylosing spondylitis or with HLA-B27? *Br J Rheumatol* 1983; 22 (Suppl 2): 146-147.
7. Vanuytrecht-Henderickx D, Dewolf-Peeters C, Degreef H. Morphological study of the reticular erythematous mucinosis syndrome. *Dermatologica* 1984; 168: 163-169.
8. Steigleder GK, Kanzow G. Muzinablagerungen in der Dermis und REM-Syndrom. *Hautarzt* 1980; 31: 575-583.
9. Wright V. Psoriatic arthritis. In: Kelley WM, Harris Jr ED, Ruddy S, Sledge CB, eds. *Textbook of rheumatology*. Philadelphia: WB Saunders Company, 1981: 1047-1062.
10. Good AE. Enteropathic arthritis. In: Kelley WM, Harris Jr ED, Ruddy S, Sledge CB, eds. *Textbook of rheumatology*. Philadelphia: WB Saunders Company, 1981: 1063-1075.