

Expansion of Large Granular Lymphocytes in Psoriatic Erythroderma

A Case Report

STEFANO CALVIERI and ANDREA FATTOROSI

Institute of Dermatology, University of Rome "La Sapienza", Rome, Italy

Calvieri S, Fattorossi A. Expansion of large granular lymphocytes in psoriatic erythroderma: a case report. *Acta Derm Venereol (Stockh)* 1986; 66: 497-501.

A psoriasis patient developed erythroderma after the withdrawal of a self-administered chronic topical glucocorticoid therapy. A marked expansion of cells with the morphological and phenotypic features of large granular lymphocytes was noticed in peripheral blood. Functional investigations revealed that these cells responded poorly to polyclonal activators and exhibited antibody-dependent cellular cytotoxicity and natural killer activity. Blood abnormalities completely subsided in about two months in the absence of any cytostatic therapy and coincided with the recovery from the erythroderma and the spreading of classical psoriatic plaque lesions. This excluded an underlying malignant process. This patient represents the first report of a previously undescribed immunological disorder in psoriatic erythroderma. *Key words: Immunological abnormalities: Glucocorticosteroids.* (Received November 21, 1985.)

A. Fattorossi, Clinica Dermatologica, Università di Roma, Viale dell'Università, 00185 Rome, Italy.

Psoriasis is a well-characterized chronic skin disorder. Topical glucocorticosteroids are an established form of antipsoriatic therapy that allows a fair alleviation of symptoms with an acceptable risk of side effects (1). On the other hand, the use of systemic corticosteroids is potentially dangerous as acute withdrawal of administration may convert stable plaque psoriasis to the erythrodermic form (1). Although topically applied high potency glucocorticoids have been reported to enter the circulation and produce systemic side effects (2), psoriatic erythroderma seems to be a very rare complication of local steroid discontinuation and has even been denied by some authors (3). Systemic glucocorticoids are widely recognized as immunomodulating agents (4, 5). However, there is little information available on their possible effect on the immune system when applied topically over long periods. To our knowledge, no consistent immunological abnormality has been described in psoriatic erythroderma subjects receiving topical glucocorticoid treatment. In this report we evaluated a series of immunological parameters in a psoriasis patient who developed severe erythroderma one week after withdrawal of a self-administered high dosage topical glucocorticoid application. The results of phenotypic and functional studies on circulating mononuclear cells are reported and related to the clinical status.

CASE REPORT

The patient, P. N., a 30-year-old man, had suffered from psoriasis for ten years. On admission, we noticed skin atrophy, striae, telangiectasia, and alteration of fat distribution leading to a cushingoid appearance. Classical, well-margined erythematous scaly psoriasis plaques were also noted. He referred daily application of a desoxymethasone cream (0.25%) on his trunk, arms and legs for about six months. Occlusive dressing was sometimes used. Routine blood examination showed no evident abnormality. The application of topical glucocorticoid was therefore slowly withdrawn. After a week, the patient developed erythroderma with malaise and high fever (39.2°C). There was diffuse edema of

Table I. Specificity of monoclonal antibodies

Antibody	Trade	Main specificity
OKT3	Ortho	Peripheral T-cells
OKT4	Ortho	Helper/inducer T-subset
OKT8	Ortho	Suppressor/cytotoxic T-subset
OKUa-1	Ortho	Class II MHC antigens
OKM1	Ortho	Phagocytes. Null cells
Leu 7	Becton Dickinson	Natural killer cells. Antibody-dependent killer cells

the skin with mild exfoliation. The oral mucous membranes were erythematous. The spleen was not palpable. Superficial lymph nodes were slightly enlarged and tender. No other remarkable signs were noticed on physical examination. Laboratory studies disclosed a WBC count of $9000/\text{mm}^3$, with 65% neutrophils, 25% lymphocytes and 5% monocytes. Two thirds of the lymphocytes were larger than normal and contained azurophilic granules. Nuclei were round with only slight indentation. These cells were therefore referred to as large granular lymphocytes (LGL) (6). The patient was administered liquids and broad spectrum antibiotic therapy despite repeated negative blood cultures. He recovered from both the erythroderma and hematological abnormalities after two months. At that time, classical psoriatic plaques were clearly evident on his trunk and arms.

MATERIALS AND METHODS

All tests were carried out on mononuclear cells (MC) purified from peripheral blood by Ficoll/Hypaque density gradient centrifugation (5).

Phenotypic profile and functional assays

Six monoclonal antibodies, OKT3, OKT4, OKT8, OKIa-1, OKM1 and Leu 7 were used (Table I). The specificities of these reagents have been reported in more detail elsewhere (7, 8). F(ab)₂ fragments of

Table II. Phenotypic profile and functional activity of patient's mononuclear cells at the onset of erythroderma, during the clinical course, and after complete recovery

Slg = surface immunoglobulin bearing cells; FcR⁺ = cells carrying receptors for the Fc fragment of IgG; phagocytes = cells able to ingest IgG-coated latex particles; ADCC (antibody dependent cytotoxicity) and NK (natural killer activity) are expressed as % of specific lysis; PHA (phytohemagglutinin) and ConA (Concanavalin A) responses are expressed as SI (stimulation index) obtained using optimal concentration of each mitogen; nd = not done

	% Positive cells			
	Onset	One month	Recovery	Normal values
OKT3	68	71	nd	65±3
OKT4	32	35	41	42±4
OKT8	48	36	30	20±4
OKIa-1	12	8	nd	18±6
OKM1	10	13	12	15±5
Leu 7	42	38	26	20±8
Slg	5	nd	3	5±5
E-rosettes	70	nd	59	60±8
FcR ⁺ cells	38	nd	nd	25±10
Phagocytes	15	18	10	12±9
ADCC (%)	82	nd	67	65±4
NK (%)	62	nd	49	50±5
PHA (SI)	15	24	53	>30
ConA (SI)	8	28	45	>25

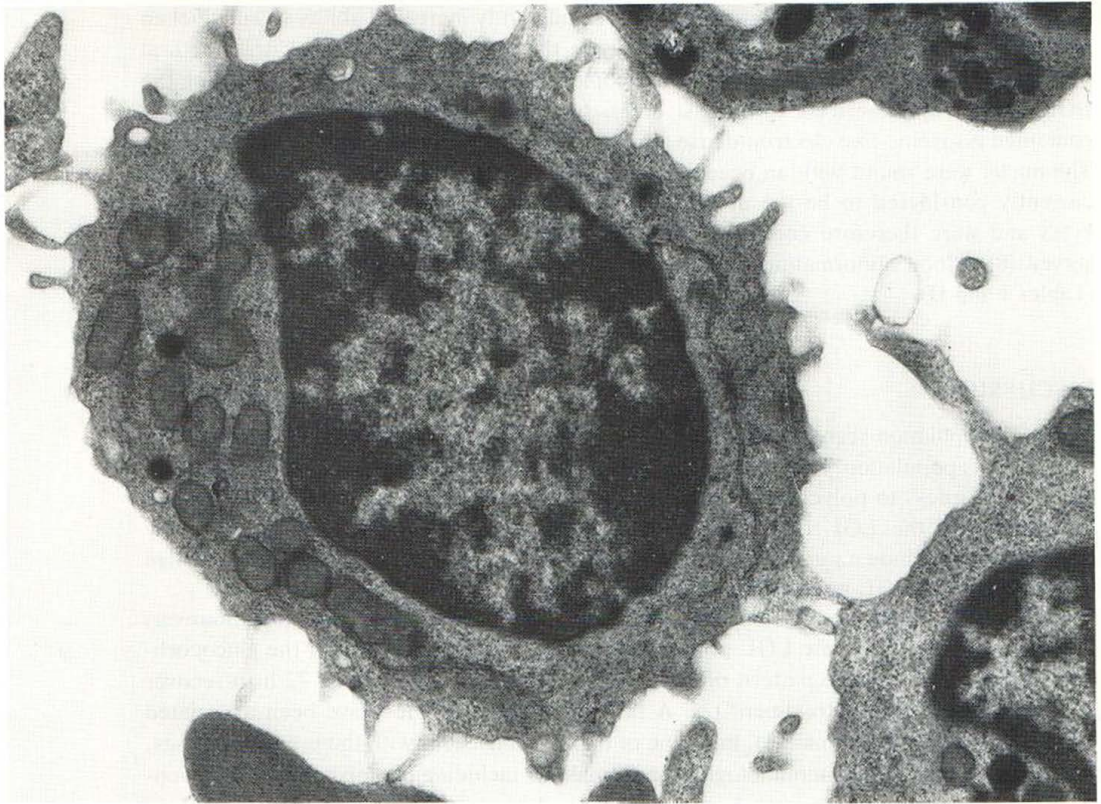


Fig. 1. Representative large granular lymphocyte from peripheral blood mononuclear cell preparation ($\times 27\,000$).

a goat antiserum against $F(ab)_2$ fragments of human immunoglobulins (Ig) were used for staining surface Ig, a marker of B lymphocytes. The sheep erythrocyte receptor on T lymphocytes was assessed by the E-rosette technique (7). Cells bearing receptors for the Fc fragment of IgG and phagocytes were investigated using IgG-coated latex particles as previously described in detail (9). MC were then investigated for their response to polyclonal activators. Briefly, ^3H -thymidine uptake was measured after a 72 h incubation with increasing concentrations of phytohemagglutinin (PHA) 1 μg , 2 μg , and 4 $\mu\text{g}/\text{ml}$, and Concanavalin A (Con A) 3 μg , 6 μg , and 12 $\mu\text{g}/\text{ml}$. These mitogen concentrations had been previously shown to be optimal for normal subjects in our laboratory (7). Since LGL are largely responsible for antibody-dependent cellular cytotoxicity (ADCC) and natural killer (NK) activity, the cytotoxic capacity of the patient's MC was investigated. Briefly, ^{51}Cr -labelled chicken erythrocytes were coated with specific rabbit IgG and incubated with increasing amounts of MC. For NK activity, a ^{51}Cr -labelled K562 cell line was used as a target (8). MC from normal subjects were evaluated in parallel in each functional assay.

For ultrastructural studies, MC were fixed in buffered glutaraldehyde and stained with uranyl acetate and lead citrate (10). Blood studies were repeated at the onset of erythroderma, one month later, and again after complete recovery.

RESULTS

The percentage of OKT8+ and Leu 7+ cells were significantly elevated above the normal range (average value plus 2 standard deviations of normal subjects). A slight, not significant increase in MC with receptors for the Fc fragment was also noted. No other phenotypic abnormalities were evident. In keeping with this profile, MC showed a

decreased response to PHA and Con A, and a significantly increased ability to kill chicken erythrocytes in the ADCC test or K562 cells in the NK test (Table II). Ultrastructural examination (Fig. 1) confirmed light microscopic evidence of cells closely resembling the LGL population described by Grossi et al. (6). The cytoplasm was fairly large and contained lysosome-like electron-dense granules without any evident sign of phagocytosis. The nuclei were round with an occasional indentation. These morphological features are currently considered to be the ultrastructural markers of cytotoxic/suppressor lymphocytes and were therefore consistent with the phenotypic and functional profile we observed (8). Blood abnormalities completely subsided after recovery from erythroderma (Tables I and II).

DISCUSSION

The LGL population seen in our patient had the phenotypic and functional features of the normal LGL population, namely, reactivity with Leu 7 and OKT8 monoclonals, diminished responsiveness to polyclonal activators, and cytotoxic activity. Moreover, the prompt reversibility of the LGL lymphocytosis in the absence of any cytoreductive therapy allowed us to exclude an underlying malignant process. The significance of such a benign expansion of the LGL population remains debatable.

Glucocorticoids are potent immunomodulating agents (2). They do not exert, however, the enhancing effect on the LGL population we report here. In addition, the glucocorticoid-induced shifts in the pattern of circulating leukocytes take at most 72 h to recover after discontinuation of treatment (2). A few blood abnormalities have been associated with psoriatic erythroderma (11), but none of them is consistent with the present findings. Interestingly, a series of immunological abnormalities including diminished T-cell responsiveness to polyclonal activators has been described in a patient who developed erythroderma following phenytoin administration (12). Therefore, in spite of the obvious differences between that case report and the present one, we speculate that a reversible alteration of immune regulation may be involved in certain erythrodermas.

It is clearly beyond our aim to assign a definite role to the immune system in the pathophysiology of the disease. But we do emphasize that patients with psoriatic erythroderma or erythroderma of other cause should be carefully screened for immunological abnormalities by periodic examination.

REFERENCES

1. Anderson TF. Psoriasis. *Med Clin North Am* 1982; 66: 769-794.
2. Karen AF, Weston WL. Topical glucocorticoids. *Ann Allergy* 1983; 50: 68-76.
3. Marks J. Erythroderma and its management. *Clin Exp Dermatol* 1980; 7: 415-422.
4. Fauci AS, Dale DC, Balow JE. Glucocorticoid therapy: Mechanisms of action and clinical considerations. *Ann Intern Med* 1976; 84: 304.
5. Fauci AS. Mechanisms of the immunosuppressive and antiinflammatory effects of glucocorticosteroids. *J Immunopharmacol* 1979; 1: 1.
6. Grossi CE, Cadoni A, Zicca A, Leprini A, Ferrarini M. Large granular lymphocytes in human peripheral blood. *Blood* 1982; 59: 277-282.
7. Fattorossi A, Del Prete GF, Giannotti B, Moretti S, Palermo A. Heterogeneity of Sézary cells. Multiparameter approach in two cases. In: MacDonald DM, ed. *Immunodermatology*. Butterworths, 119-121.
8. Pandolfi F, Semenzato G, De Rossi G, Quinti I, Guglielmi C, Pezzuto A, Lopez M, Toniatti G, Fontana L, Abo T, Aiuti F. HNK-1 monoclonal antibody (Leu7) in the identification of abnormal expansions of large granular lymphocytes. *Clin Exp Immunol* 1983; 52: 641-647.
9. Salsano F, Fattorossi A, Pisarri-Salsano S. The IgG-latex test for simultaneous identification of

- lymphoid cells with Fc receptors for IgG and of phagocytic cells. In: Progress in lymphology. Avicenum Press pp. 157-159.
10. Venable JM, Coggeshall R. A simplified lead citrate stain for use in electron microscopy. *J Cell Biol* 1965; 25: 407-408.
 11. Farber EM, Van Scott EJ. Psoriasis. In: Fitzpatrick TB, Eisen AZ, Wolff K, Freedberg IM, Austen KF, eds. *Dermatology in general medicine*. McCraw-Hill, p. 240.
 12. Lillie MA, Yang LC, Honig PJ, August CS. Erythroderma, hypogammaglobulinemia, and T-cell lymphocytosis. Occurrence following therapy with phenytoin. *Arch Dermatol* 1983; 119: 415-418.