

Focal Naevoid Hypotrichosis

J. H. BARTH and R. P. R. DAWBER

The Slade Hospital, Oxford, UK

Barth JH, Dawber RPR. Focal naevoid hypotrichosis. *Acta Derm Venereol (Stockh)* 1987; 67: 178-179.

A case of naevoid hypotrichosis affecting two symmetrical areas in the parietal regions is described. (Received July 25, 1986.)

J. H. Barth, Department of Dermatology, The Slade Hospital, Headington, Oxford OX3 7JH, UK.

A 4-year-old black boy was seen with well defined areas of hypotrichosis in the parietal regions of the scalp. The two lesions were symmetrically distributed and there was no scarring. He had an uneventful birth after a normal full term pregnancy. No forceps or scalp electrodes had been used.

At birth there were two completely bald patches which had gradually enlarged in proportion to the growth of the head. Hairs had grown within these areas during the following years but at 4 years they were clearly still only sparse (Fig. 1). Individual hairs within the hypotrichotic areas were of normal length and colour.

DISCUSSION

Focal non-scarring hypotrichosis or alopecia in infancy is uncommon. The commonest cause of localized congenital alopecia is naevoid (1). Epidermal naevi may be flat at birth but become thickened and warty as the child grows. Organoid naevi are evident at birth. Congenital triangular aplasia is present at birth but does not grow hairs. Occipital alopecia of the newborn occurs at about 3 months and is due to the physiological delay of the hair fall after telogen conversion.

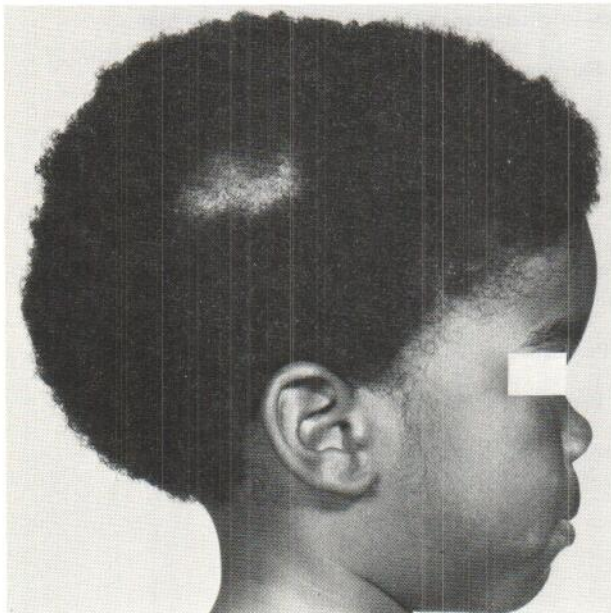


Fig. 1. Lateral view of head demonstrating area of hypotrichosis. An identical area can be seen on the contra-lateral aspect.

In childhood, other non-scarring alopecias should be considered. Alopecia areata does not present at birth with subsequent sparse growth of normally pigmented hairs. Tick bite alopecia is transient (2). The presence of normal length hairs within the hypotrichotic area excludes trichotillomania.

Alterations in hair growth are often recognized as naevoid in origin. Hair follicle naevi (3), straight hair (4) and woolly hair naevi (5) have been described. We conclude that the hypotrichotic areas in this child's scalp are naevoid in origin.

REFERENCES

1. Rook AJ, Dawber RPR. Diseases of the hair and scalp. Oxford: Blackwell Scientific Publications, 1982: 53.
2. Heyl T. Tick bite alopecia. *Clin Exp Dermatol* 1982; 7: 537-542.
3. Pippone M, Aloï F, Depaoli MA. Hair-follicle nevus. *Am J Dermatopathol* 1984; 6: 245-247.
4. Lange Watzin G, Poulsen T, Thomsen K. Straight hair nevus in a patient with straight hair. *Acta Derm Venereol (Stockh)* 1983; 63: 570-571.
5. Goldin HM, Bronson DM, Fretzin DF. Woolly-hair nevus; case report and study by scanning electron microscopy. *Pediatr Dermatol* 1984; 2: 41-44.

Retinoids and Systemic Chemotherapy in Cases of Advanced Mycosis Fungoides. A Report from the Scandinavian Mycosis Fungoides Group

LARS MOLIN,⁷ KRISTIAN THOMSEN,¹ GUNNAR VOLDEN,⁴ PETER JENSEN,⁵ ERIK KNUDSEN,² ALLAN NYFORS⁶ and HENNING SCHMIDT³

Departments of Dermatology, ¹Finsen Institute, Copenhagen, ²Hvidovre Hospital, Copenhagen, ³University Hospital, Odense, Denmark, ⁴University Hospital, Trondheim, ⁵Rikshospitalet, Oslo, ⁶Haukelands Sykehus, Bergen, Norge and ⁷University Hospital, Linköping, Sweden

Molin L, Thomsen K, Volden G, Jensen P, Knudsen E, Nyfors A, Schmidt H. Retinoids and systemic chemotherapy in cases of advanced mycosis fungoides. A report from the Scandinavian mycosis fungoides group. *Acta Derm Venereol (Stockh)* 1987; 67: 179-182.

In cases of advanced mycosis fungoides, the systemic chemotherapy combination of bleomycin, cyclophosphamide and prednisolone was given to 8 cases, and the same 3-drug combination with the addition of oral retinoids given to 12 cases. All cases were in a progressive phase of the disease. Remission was obtained in 5/8 cases treated with the combination and in 7/12 cases treated with the combination plus retinoids. The remissions were complete in half of the cases, but relapse occurred within 3 to 6 months in all but 2 cases. The two treatment patient groups were not fully comparable but the conclusion is that the addition of retinoids to systemic chemotherapy combination regimens is of some advantage. There still exists, however, need of more adequate treatment modalities in advanced mycosis fungoides. *Key word: Tumour stage.* (Received June 5, 1986.)

L. Molin, Department of Dermatology, University Hospital, S-581 85 Linköping, Sweden.

Need still exists for more efficient treatment of cases of advanced mycosis fungoides. Hitherto no treatment regimen has been able reliably to induce remission in cases where mycosis fungoides has entered the tumour stage or has disseminated to lymph nodes or viscera. Previously, bleomycin has been used in a short series of such patients (1). Although remission was obtained in a high proportion of cases, an unacceptably high incidence of side effects often led to abandonment of this treatment. Cyclophosphamide