

# Immunohistochemical Investigation of Dermal Capillaries in Chronic Venous Insufficiency

WOLFGANG VANSCHIEDT, HELMUT LAAFF, JOHANNES M. WEISS and ERWIN SCHÖPF

Department of Dermatology, Albert-Ludwigs-Universität Freiburg, Freiburg, FRG

**Skin biopsies from the area of the medial malleolus of 24 patients with chronic venous insufficiency, of 5 patients without signs or history of chronic venous insufficiency and of seven corpses without manifestation of chronic venous insufficiency, were sectioned and stained with hematoxylin and eosin and with Ki-67, a monoclonal antibody expressed in the nuclei of proliferating cells. Hematoxylin- and eosin-stained sections of all specimens were assessed blindly to determine the state of capillary increase in stasis dermatosis. Twenty-four patients were found to have different stages of stasis dermatosis. During the examination of the Ki-67 frozen sections, close attention was paid to the capillary bed of all sections for any Ki-67-positive nuclei in capillary cells. None of the three groups showed positive staining of nuclei in capillary cells. This finding proves that there is no capillary proliferation, but an elongation and distension of the capillaries. Key words: Stasis dermatosis; Capillary proliferation; Monoclonal antibody Ki-67.**

(Accepted July 19, 1990.)

Acta Derm Venereol (Stockh) 1991; 71: 17-19.

W. Vanschiedt, Department of Dermatology, Albert-Ludwigs-Universität Freiburg, Hauptstr. 7, D-7800 Freiburg, Federal Republic of Germany.

The mechanisms that lead to skin disorders in chronic venous insufficiency (CVI) such as purpura jaune d'ocre, ankle flare, dermatoliposclerosis, atrophy blanche, and venous leg ulcers are not yet fully understood. Various theories have been proposed to account for the venous ulceration (1). However, none of these theories has adequately explained the skin indurations seen in patients with CVI.

During the last 30 years, various reports about the histological and morphological changes observed in the skin of the lower limbs of patients with CVI have been published. In 1956, the late Ian Whimster (2) observed a pronounced increase in the number of capillary loops visible in cross section of the skin

adjacent to a venous ulcer. These changes are characteristic of indurations preceding venous ulceration. Burnand et al. (3) proposed that there is a significant correlation between the inability of the calf muscle pump to reduce foot vein pressure during exercise and the number of capillaries in the skin. Burnand et al. (3) stated in their studies that one cannot be certain whether the increase in capillaries seen in the histological section is a true increase or only an elongation and distention of the dermal capillaries.

The question as to whether there is a proliferation of capillaries or merely a capillary deformation has not been answered. In this study, we report our findings on the changes in the capillary bed in human skin obtained with an immunohistological method. Skin biopsies were stained with the monoclonal antibody Ki-67. This reacts with a human nuclear antigen expressed only in proliferating cells. By this approach it is possible to determine whether there is capillary proliferation in CVI or merely an elongation.

## MATERIALS AND METHODS

### Patients

On the basis of their clinical history, patients were assigned to groups according to their dermal status using the classification of CVI (Stages I-III) introduced by Widmer (4).

This study included a total of 29 patients. Skin samples from seven cadavers were additionally examined. Twenty-four out of 29 patients (12 females, 12 males) showed symptoms of CVI. Six of these 24 patients were classified as CVI stage II and 18 as CVI stage III. The average age of the patients with CVI was 52.6, range 40-74 years. The other 5 patients (4 females, 1 male) without signs or history of CVI had an average age of 19 years, range 13-28 years.

The biopsies were obtained from the Department of Dermatology, School of Medicine, Freiburg. All of the specimens were 8-15 mm long and 2-3 mm wide. They contained cutis and subcutaneous fat and were taken either during surgery or under local anesthetic from an area of approximately 5-20 cm above the medial malleolus.

Another seven tissue samples were taken from cadavers



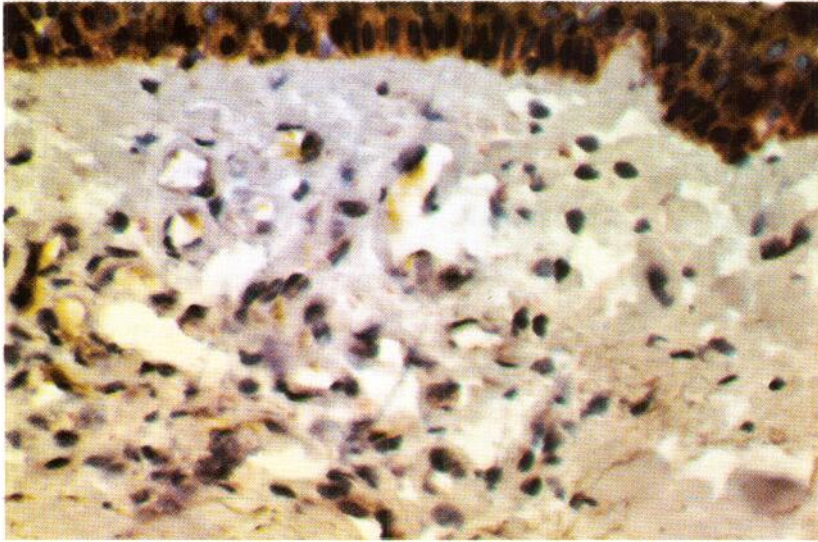


Fig. 1. Stasis dermatosis from a patient with CVI. No positive staining of nuclei in capillaries is visible. Frozen section stained with Ki-67 ( $\times 100$ ).

(3 females, 4 males) at autopsies performed at the Department of Forensic Medicine, School of Medicine, Freiburg. These circular samples were  $4 \times 4$  mm in size, taken from approximately 7–9 cm above the medial malleolus. The cadavers had reached an average age of 21.7 years, range 6–33 years. There were no signs suggesting varicose veins or any skin alterations connected with CVI.

The samples were divided. Half were fixed in formalin, dehydrated and embedded in paraffin wax; these were sectioned and stained with hematoxylin and eosin. The remainder were shock-frozen in liquid nitrogen and kept at  $80^\circ\text{C}$  until sections were cut, and then stained with Ki-67 by means of the alkaline phosphatase anti-alkaline phosphatase (APAAP) technique.

#### Monoclonal antibodies and staining

The monoclonal antibody Ki-67 was procured from Dakopatts (Glostrup, Denmark). This antibody reacts with a nuclear antigen present in all proliferating cells in human tissue. Expression of the antigen occurs in the phases G1, S, M and G2 of the active cell cycle. The nucleus consistently lacks the antigen during G0 phase (5).

Staining was performed by using the APAAP technique (6). The 5- $\mu\text{m}$  frozen sections were fixed in acetone (10 min) and in chloroform (30 min). They were subsequently incubated in the following solutions:

1. primary antibody diluted into Tris-buffered saline (TBS) 1:40, then rinsed in TBS for 10 min;
2. rabbit immunoglobulins to mouse immunoglobulins 1:40:30 min. This antibody was diluted in a 1:2 mixture of TBS and heat-inactivated normal human serum, then rinsed in TBS for 10 min.
3. APAAP diluted in TBS 1:100:30 min, then rinsed in TBS for 10 min.
4. Development of the alkaline phosphatase label:

Three solutions were prepared just before incubation:

- Solution 1. 25 ml propandiol buffer, 70 ml aqua tridest, 40 mg levamisole
- Solution 2. 50 mg naphthol AS-BI and 0.6 ml N,N-dimethylformamide
- Solution 3. 200  $\mu\text{l}$  5% new fuchsin solution 500  $\mu\text{l}$  aqueous solution of sodium nitrite. The two solutions were mixed by shaking for 60 s.

Solution 3 was added to solution 1, then solution 2 was added. While stirring, the solution was adjusted to pH 8.7 by adding 1 N HCl. The solution was filtered and the sections were incubated in it for 30 min on a shaker. Then the sections were rinsed in TBS, and counterstained with Meyer's hemalaum for 60 s and cover-slipped with glycerol gelatin.

Frozen sections of a tonsil were stained along with the skin samples as controls. The positive control showed positive staining of germinal centres. The negative control was not incubated with the primary antibody and showed no positive staining.

To assess the histologic status of the specimens the sections were examined by two observers. They were unaware of the clinical findings connected with the sections. The sections stained with hematoxylin and eosin were used to assess the pathologic changes of the capillaries in the skin of the patients. The sections stained with hematoxylin and eosin and with Ki-67 were analysed independently without knowledge of the findings of the other.

#### RESULTS

Eighteen out of 24 hematoxylin and eosin sections from patients with CVI stages II and III showed the typical histological signs of stasis dermatosis with an increase in the number of capillary loops. Different stages of stasis dermatosis were found in the sec-

tions, ranging from slight to gross increases in capillary loops. The other 6 had no pathological changes. The skin sections of the 5 patients without CVI as well as those of the 7 cadavers had normal capillaries without any dermal pathologic changes. The capillaries of the Ki-67-stained frozen sections were thoroughly examined. Neither the increased number of capillary loops in sections of patients with CVI nor the normal capillaries in those of patients and cadavers without CVI showed Ki-67-positive staining in any nuclei. The stratum basale contained positive-stained nuclei as expected, giving an internal positive control (Fig. 1).

## DISCUSSION

This study examined the capillaries of the skin in CVI, in sections with different stages of stasis dermatosis, using monoclonal antibody Ki-67. We were able to show that the proliferation marker Ki-67 is negative in all nuclei of capillaries. This holds true for all stages of stasis dermatosis and proves that no stage of stasis dermatosis is accompanied by capillary proliferation.

Burnand et al. (3) have shown that there is a significant increase in the number of the capillary loops correlating with venous hypertension during exercise. Since there are no signs of proliferation, it must be assumed that the capillaries are elongated as well as dilated by the venous pressure. This distention and elongation of the terminal vessels may lead to alterations in the vessels' wall structure and of the pericapillary space (7). The widening of intercellular spaces probably causes the hyperpermeability to fibrinogen and other large molecules that pass into the interstitial space (8). This process follows edema and reactive inflammation (9). A

pericapillary fibrin cuff is the result of the deposition of fibrinogen around the capillaries (8, 10). Linked to other damages of the capillaries, this may lead to a malnutrition of the tissue through an impeded oxygen diffusion.

## ACKNOWLEDGEMENT

We are very grateful to Ms K. Roth and S. Bauer, M.D. for their assistance.

## REFERENCES

1. Browse NL. Venous ulceration. *Br Med J* 1983; 286: 1920-1922.
2. Whimster I. Cited in: Dodd H, Cockett FB. *The pathology and surgery of the veins of the lower limb*. London: Churchill-Livingstone, 1956: 262-266.
3. Burnand KG, Whimster K, Clemenson G, Thomas ML, Browse NL. The relationship between the number of capillaries in the skin of the venous ulcer-bearing area of the lower leg and the fall in foot vein pressure during exercise. *Br J Surg* 1981; 68: 297-300.
4. Widmer LK. *Peripheral venous disorders*. Basle Study III. Bern, Stuttgart, Wien: Huber, 1978.
5. Gerdes J, Schwab U, Lemke H, Stein H. Production of a mouse monoclonal antibody reactive with a human nuclear antigen associated with cell proliferation. *Int J Cancer* 1983; 31: 13-20.
6. Schaumburg-Lever G. The alkaline phosphatase anti-alkaline phosphatase technique in dermatopathology. *J Cutan Pathol* 1987; 14: 6-9.
7. Wenner A, Leu HJ, Spycher M, Brunner U. Ultrastructural changes of capillaries in chronic venous insufficiency. *Exp Cell Biol* 1980; 48: 1-14.
8. Burnand KG, Whimster I, Naidoo A, Browse NL. Pericapillary fibrin in the ulcer-bearing skin of the leg: the cause of lipodermatosclerosis and venous ulceration. *Br Med J* 1982; 285: 1071-1072.
9. Leu HJ. Histopathologie der chronisch-venösen Insuffizienz. *Hautarzt* 1985; 36 (suppl 7): 163-164.
10. Browse NL, Burnand KG. The cause of venous ulceration. *Lancet* 1982; ii: 243-245.