

UV-induced Squamous Cell Carcinomas in the Hairless Mouse

Morphological Characteristics and Transplantation in the Syngenic and Nude Mouse

R. CADI,¹ J. C. BEANI,¹ M. JACROT,² N. PINEL³ and P. AMBLARD¹

¹CHRU Clinique Dermato-Siphiligraphique, ²Faculté de médecine, Laboratoire de Cytogénétique and ³CHRU Service de Pathologie cellulaire et de Microscopie électronique, Grenoble, France

Squamous cell carcinomas were induced by UVB in the hairless mouse HRO hr/hr. Twelve mice were irradiated three times a week at a dose of 0.19 J/cm². The average latency period for the appearance of the first tumour is 16 weeks and by the 21st week, tumour incidence is 100%. Further observation of these tumours shows that their growth is independent of irradiation dose and that the tumours continue to appear even after cessation of irradiation. Histological and cytological examination of these tumours show them to have characteristics of malignancy. Transplantation in athymic mice suggests that UVB provokes immune deficiencies in hairless mice similar to those seen in conditioned nude mice. Key words: Ultraviolet radiation; Photocarcinogenesis; HRO hairless mice; Athymic mice.

(Accepted July 26, 1990.)

Acta Derm Venereol (Stockh) 1991; 71: 32–36.

R. Cadi, CHRU Service de Dermatologie, BP.217 38043 Grenoble Cedex, France.

It has been known for many years that the UV component radiation in natural light is the important agent in skin ageing and cutaneous tumours. Epidemiological studies suggest that more than 90% of squamous cell carcinomas are the result of over-exposure to sunlight, and most particularly to UV (1). Experimental findings in mice have shown that UVB radiation (280–320 nm) is more carcinogenic than UVA (320–400 nm) (2, 3) and UVC (254–280 nm) (4). Other epidemiological and experimental studies have shown that the carcinogenic risk is proportional to the cumulative UV dose throughout a lifetime (5, 6). A number of other experiments (2, 7) have been carried out on mice and two rather similar theories have been proposed by Blum (5) and de Gruijl et al. (8), according to which the time of

tumour appearance consists of a dose-dependent initiation time and a dose-independent promotion time.

Several studies by Kripke (9) have shown that in the mouse, most UV-induced cutaneous tumours are highly antigenic. Indeed, 75% of these tumours are rejected after transplantation into normal syngenic mice. On the other hand, pre-treatment of syngenic host mice by UV invariably induces a state of tolerance to these photo-induced tumours. UV treatment even induces the generation of suppressive T lymphocytes (ST) which are responsible for the suppression of photo-induced tumour rejection (10, 11). Recently, Romerdahl & Kripke (12) have shown that ST lymphocytes facilitate the growth of these tumours by specifically blocking the generation of Th anti-tumour 'helper' T lymphocytes. These alterations in the immune system defences by UVB affect not only the rejection of transplanted photo-induced tumours, but also contribute significantly in the production of primary tumours.

In the present study, we induced cutaneous tumours by UVB irradiation of hairless mice. The post-irradiation evolution of tumours was studied. These UVB-induced tumours were then transplanted into syngenic and athymic mice after histological evaluation.

MATERIALS AND METHODS

Animals

The mice used in this photo-carcinogenic study were female hairless type HRO (hr/hr) obtained from the breeding centre (CNRS, Orléans, France). The animals were 7–8 weeks old at the beginning of the experiment. They were housed in plastic cages and had free access to food and acidified water (pH = 3). There were 12 mice in the treated group and 7 in the control group. For the transplantation studies we used female hairless and athymic mice (type

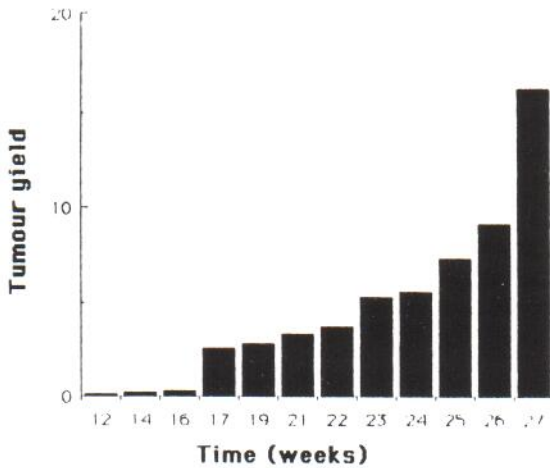


Fig. 1. Tumour yield (total number of tumours/number of surviving mice) vs. time. 12 mice were irradiated 3 times/week for 26 weeks, receiving 0.57 J/cm^2 per week. Minimally detectable tumours $\geq 1 \text{ mm}$ diam.

Swiss/nu obtained from IFFA CREDO France). They were kept isolated in a room with limited access, housed in sterile cages and given estrone in their drinking water ($1 \mu\text{g/ml}$ water).

Light source

The light source consisted of a UV apparatus (Biotronic) composed of two sets of three 40 W fluorescent tubes (one set of UVA: Vilbert-Lourmat T-40L, spectrum distribution: 320–400 nm, max = 365 nm and one set of UVB: Vilbert-Lourmat T-40 M, spectrum distribution: 280–320 nm, max = 312 nm), having an energy of 6 mW/cm^2 . The apparatus is controlled by a microprocessor and is precision programmed in minutes or Joules. The irradiation dose is monitored on the back of the animals by two captors specific for UVA or UVB (Radiometer RX, Vilbert-Lourmat, France). This apparatus permits the irradiation of several mice simultaneously and uniformly and the temperature at the animal's level did not exceed 30°C .

Irradiation procedure

During irradiation, the mice were fixed by the tail with adhesive tape at 25 cm from the fluorescent tubes. They were irradiated three times a week by UVB (280–320 nm) whose spectrum has a maximum absorption at 312 nm. Each exposure delivered 0.19 J/cm^2 corresponding to 0.63 minimal erythema dose (MED) for 1 min and 50 s. The mice were treated for 26 weeks and they were sacrificed when the tumours reached a diameter greater than or equal to 2 cm. The total duration of the experiment was 42 weeks.

Tumour development time

The animals were weighed and observed weekly for changes in skin appearance and tumour presence. The median latent period (T_{50} = number of weeks irradiated to the

time when at least half of the mice have at least one tumour $\geq 1 \text{ mm}$ in diameter) was determined.

Transplantation technique

The tumour tissue was dissected from the mouse and cut down the centre with a scalpel. The necrotic areas were trimmed away. The solid, grossly viable tumour was cut into 2 to 4 mm^3 fragments and transplanted sub-cutaneously onto the back of syngenic or athymic mice, and the incision was closed with absorbable suture.

Tumour histology

The mice were killed and the tumour tissue was fixed for routine staining HPS for light microscope examination. Other specimens were fixed in 2% glutaraldehyde for electron microscope examination.

Tumour cytology

The imprint of the tumour was fixed in a solution of methanol and acetone (v/v) and stained with PAP (13).

RESULTS

Tumour inducement by UVB

Tumour incidence. None of the control mice developed tumours throughout the entire experimentation period. The 12 irradiated mice all developed cutaneous tumours. The first tumour was found by morphological examination at the 12th week of irradiation. 50% of the mice (T_{50}) developed at least one tumour $\geq 1 \text{ mm}$ after an average latency time of 16 weeks of irradiation. By the 21st week, all of the mice were affected. The mean number of tumours per surviving mouse increased as a function of time, at the 26th week reaching 10.2 ± 3 (Fig. 1).

Morphological examination. The first morphological modifications were apparent after the second irradiation exposure and consisted of erythema, dehydration and desquamation of the skin. These first signs disappeared during the second week of irradiation. The continued irradiation caused a thickening of the skin and cutaneous tumours then began to appear from the 12th week of irradiation. These tumours were in the form of nodules which can only be discerned by eye when they have reached a diameter $\geq 1 \text{ mm}$. They were formed on the parts of the mouse which were exposed to UVB (head and back). The tumours subsequently evolved and changed morphology. Two aspects can be distinguished: salient nodes whose dimension varies from 1 mm to 2 cm. They did not show ulceration initially. These nodes had a hard consistency and often a cornified excrescence on the surface and were rarely infiltrating. The second aspect corresponds to infil-

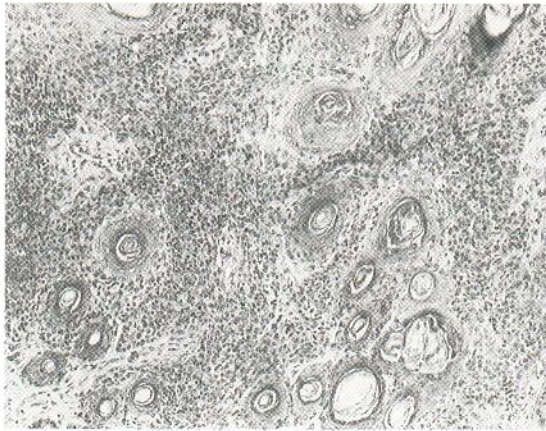


Fig. 2. Photo-induced squamous cell carcinoma invading the dermis and presenting cellular atypias and horn pearls. HPS, $\times 132$.

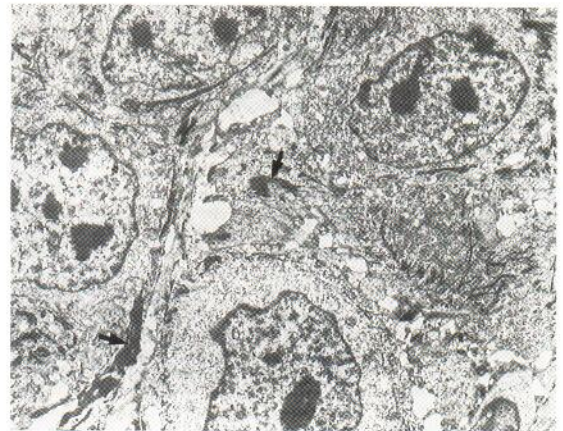


Fig. 3. Electronmicrograph of photo-induced squamous cell carcinoma: irregularity of nuclear contours with multiplication of nucleoli. Tonofilaments grouped into bundles (arrow), $\times 4000$.

trating and confluent lesions which can attain a considerable volume and they frequently presented a central, hollowing ulceration and invasive infiltration. In pathology, all of these tumours are classed morphologically as squamous cell carcinomas and show varying degrees of differentiation.

Histopathological and ultrastructural examinations. The skin of the control hairless HRO is characterized by: a thin epidermis 1 to 3 cells deep, a non-differentiated basal cellular layer aborted hair follicles, intra-dermic cysts derived from hyperkeratosis of aborted hair follicles and a thick stratum corneum. The electron microscope shows differentiation characteristic of keratinocytes. In mice exposed to UVB, a histological evolution can be detected in the skin after irradiation. The first modifications after irradiation occurred as an epidermal hyperplasia with hyperacanthosis and hyperkeratosis. The second modification, which results from the continued exposure to UVB, is the formation of keratinizing tumours (Fig. 2). They present a picture of anarchic and irregular epidermal proliferation with cells in varying degrees of maturity. Keratinization occurs either on the surface or within the proliferation area of the tumour in the form of horn pearls. These tumours infiltrate the underlying dermis, to varying degrees, and are either squamous cell carcinomas in various degrees of differentiation. Electron microscopy shows that these tumour have the following characteristics (Fig. 3): the nuclei are abnormal and composed essentially of heterochromatin, there are several nucleoli or one voluminous

nucleolus, the tonofilaments are grouped into bundles, the mitochondria have dense inclusions, there are numerous desmosomes, and the dermal conjunctiva is composed of disorganized bundles of collagen with variable fibril diameters and decreased amounts of elastin.

Cytologic examination. The tumour imprints (Fig. 4) were made immediately after excision (Papanicolaou staining) (13) and had the following cytological characteristics: presence of many necrotic cell, fibrous cells strongly keratinized, nucleated corneocytes, varying degrees of hyperkeratosis, well differentiated haloperinuclear space, condensed, clumped chromatin, several nucleoli per nucleus and

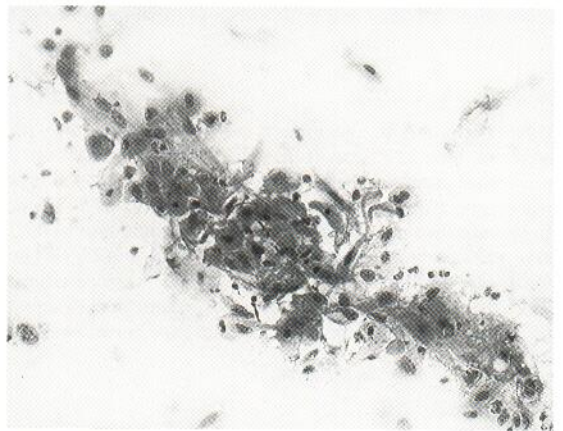


Fig. 4. Imprints of photo-induced squamous cell carcinoma showing cells of varying shapes and nuclear polymorphism. Papanicolaou stain, $\times 264$.

abnormal nuclei, often two to a cell. This set of characteristics is indicative of the malignancy of these photo-induced squamous cell carcinomas.

Evolution of photo-induced tumours after cessation of irradiation

The daily examination of the mice during the weeks following cessation of irradiation showed that the tumours continued to appear. Indeed after cessation of irradiation the number of tumours per survivor rose from 10.2 ± 3 to 18.2 ± 4 at the 27th week (Fig. 1), but after this it was difficult to have an exact count due to tumour confluence. The pre-existing tumours continued to grow and some attained a considerable volume though none of the tumours exceeded 8 mm in diameter at cessation of irradiation.

Transplantation of photo-induced tumours

The previously described tumours were transplanted into two types of hosts: In syngenic mice, photo-induced tumours were grafted sub-cutaneously into 4 non-irradiated and 4 irradiated syngenic mice. In the first case, a single graft 'took' and the tumour cells were cultured *in vitro* to obtain a murine cell line. In the latter, all the graft took. In athymic mice, samples from the same tumours were grafted into 4 nude mice with and without estrone in the drinking water. In the first case (2 mice), all the grafts took. The average latency time was 5 days and the average time for the tumour to double in volume was 6 days. In the latter, no graft took. After successful grafting, the tumour tissue was regrafted into different athymic hosts for 12 successive passages. Each passage took an average of 15 days. The experimental model obtained from a photo-induced murine tumour as thus well established and all of the histopathological characteristics of the primitive tumour were maintained.

DISCUSSION

The hairless HRO mouse as a model for photocarcinogenesis was chosen because in this albino strain the epidermis is thin, thus permitting the UV to reach the basal layer. The results of this study obtained by irradiating a group of 12 mice with a fractionated dose of UVB at about 0.6 J/cm^2 per week show that this model gives a 100% irradiation response. Moreover, the average time for the appearance of the first tumour is 16 weeks, which is 1-4

weeks less than in previous studies (14-16), while our tumour incidence curve does not differ significantly from these authors. Thus the HRO mouse model for photocarcinogenetic tumour induction appears to be well suited to this type of study as opposed to the other hairless strains.

Macroscopic examination during this study showed that the skin underwent a series of transformations under chronic irradiation, beginning with erythema and desquamation. After the 12th week of treatment, tumours begin to appear in the thickened skin. Histological examination of tumours ≤ 2 mm showed epidermal hyperplasia while the others were classified as squamous cell carcinomas in different stages of maturation. This is in contrast to previous studies (14, 17) using various mouse strains in which most UV-induced tumours were histologically fibrosarcomas. At the dermal level, electron microscope studies revealed anomalies in the collagen and elastic fibres. Other studies carried out on mice (18) showed that UVB provokes elastic fibre anomalies at the dermo-epidermal junction. This group of alterations in the skin of hairless mice provoked by UV is also seen in pathological cases of human skin (19, 20).

The follow-up observations of mice after cessation of irradiation clearly showed that tumour growth is not dependent on further irradiation and that these photo-induced tumours continue to appear after treatment has ended. This suggests that UVB energy of 14.82 J/cm^2 delivered over 26 weeks is sufficient to induce irreversible phenomena which lead to carcinogenesis in this type of mouse. These results confirm the hypotheses that the induction of tumours requires that a sufficient amount of energy be delivered over a sufficient period of time (5) and that tumour growth is independent of irradiation (8).

Kripke's work has shown that photo-induced tumours are highly antigenic (9). Indeed, most of these tumours are rejected after transplantation into syngenic mice. On the other hand, pretreatment with UV induces a systematic and durable tolerance to these tumours. The generation of T lymphocyte suppressors (TS) is the basis of this tolerance mechanism (10, 11). Previous work by Thorn (21) has shown that the generation of TS does not diminish the primary response of cytotoxic T lymphocytes (CTL), but lowers the formation of memory CTL. Recently, Romerdahl & Kripke (12) found that TS induced by UV blocks the *in vivo* generation of anti-tumour T'helper' cells (Th). This question of

UV-provoked tolerance specific to photo-induced tumours in syngenic mice led us to test whether this type of tumour is always transplantable in athymic mice, given that this model has no mature T lymphocytes.

The results of our photo-induced tumour transplantation experiments on normal and irradiated syngenic mice are identical to those obtained by Kripke (9). For transplantation in athymic mice, two results were obtained: all grafts were rejected in the non-treated mice, while in mice treated with estrone, none of the grafts were rejected in Swiss/nu females for the same tumour type. The latter treatment was designed to lower the natural killer cell level (in press) which was extremely high in the athymic mouse. These results are comparable to those obtained by Kripke (9) and they suggest the hypothesis that UVB irradiation of the hairless HRO mice leads to immune deficiencies similar to those obtained in athymic mice treated with estrone.

ACKNOWLEDGEMENT

The authors wish to thank Professor H. Beriel and Professor Stoebner for their helpful collaboration.

REFERENCES

1. Causes and effects of stratospheric ozone reduction: An Update. Washington, DC: National Academic Press, 1982.
2. Forbes PD, Davies RE, Urbach F. Experimental ultraviolet photocarcinogenesis: Wavelength interactions and time-dose relationship. *Natl cancer Inst Monograph* 1978; no 50: 31-38.
3. Cole CA, Forbes PD, Davies RE. An action spectrum for UV photocarcinogenesis. *Photochem Photobiol* 1986; 43: 275-284.
4. Lill PH. Latent period and antigenicity of murine tumours induced in C₃H mice by short wavelength ultraviolet radiation. *J Invest Dermatol* 1983; 81: 342-346.
5. Blum HF. On the mechanism of cancer induction by ultraviolet radiation. *J Natl Cancer Inst* 1980; II: 443-485.
6. Fears TR, Scott JS. Change in skin cancer morbidity between 1971-1972 and 1977-1978. *J Natl Cancer Inst* 1982; 365-370.
7. Willis I, Menter JM, Whyte HJ. The rapid induction of cancer in the hairless mouse utilizing the principle of photoaugmentation. *J Invest Dermatol* 1981; 76: 404-408.
8. De Grujil FR, Van Der Meer JB, Van Der Leun JC. Dose-time dependence of tumour formation by chronic UV exposure. *Photochem Photobiol* 1983; 37: 53-62.
9. Kripke ML. Antigenicity of murine skin tumours induced by ultraviolet light. *J Natl Cancer Inst* 1974; 53: 1333-1336.
10. Fisher MS, Kripke ML. Systemic alteration induced in mice by ultraviolet light irradiation and its relationship to ultra-violet carcinogenesis. *Proc Natl Acad Sci (USA)* 1977; 74: 1688-1692.
11. Spellman CW, Daynes RA. Modification of immunologic potential by ultraviolet radiation. II. Generation of suppressor cells in short-term UV-irradiated mice. *Transplantation* 1977; 24: 120-126.
12. Romerdahl CA, Kripke ML. Role of helper T-lymphocytes in rejection of UV-induced murine skin cancers. *Cancer Res* 1988; 48: 2325-2328.
13. Papanicolaou GN. A new procedure for staining vaginal smears. *Science* 1942; 95: 438.
14. Roberts LK, Bernhard EJ, Daynes RE. Experimental ultraviolet radiation carcinogenesis: I. Relationship of the major histocompatibility complex to tumour latency and immunogenicity. *Photodermatology* 1984; 57-64.
15. Forbes PR, Blum HF, Davies RE. Photocarcinogenesis in hairless mice: dose-response and the influence of dose-delivery. *Photochem Photobiol* 1981; 34: 361-365.
16. Bisset DL, Hannan DP, Orr TR. An animal model of solar aged skin: histological, physical and visible changes in UV-irradiated hairless mouse skin. *Photochem Photobiol* 1987; 46: 367-378.
17. Kripke ML. Latency, histology and antigenicity of tumours induced by ultraviolet light in three inbred mouse strains. *Cancer Res* 1977; 37: 1395-1400.
18. Kligman LH, Akin FS, Kligman AM. The contribution of UVA and UVB to connective tissue damage in hairless mice. *J Invest Dermatol* 1985; 84: 272-276.
19. Lynch PJ. Sun light and aging of the skin. *Cutis* 1976; 18: 451-453.
20. Kligman AM. Comments on the stratum corneum in the biologic effect of UV radiations. Oxford: Pergamon Press, Urbush ed. 1969: 165-176.
21. Thorn RM. Specific inhibition of cytotoxic memory cells produced against UV-induced tumours in UV irradiated mice. *J Immunol* 1978; 121: 1920-1926.