

# Cutaneous Vasculitis Induced by Food Additives

NIELS K. VEIEN<sup>1</sup> and ANNELISE KROGDAHL<sup>2</sup>

<sup>1</sup>Dermatology Clinic, Aalborg, and <sup>2</sup>Institute of Pathology, Aalborg Hospital, Aalborg, Denmark

**A case of leukocytoclastic vasculitis in a 24-year-old woman is described. A severe eruption of vasculitis occurred after placebo-controlled oral challenge with 50 mg ponceau. The patient was asked to adhere to a diet free from food additives, and the vasculitis faded after a period of 2 months. Key words: Ponceau; Oral challenge; Diet treatment.**

(Accepted July 10, 1990.)

Acta Derm Venereol (Stockh) 1991; 71: 73–74.

N. K. Veien, The Dermatology Clinic, Vesterbro 99, DK-9000 Aalborg, Denmark.

Foodstuffs and food additives have previously been incriminated as a cause of purpura and cutaneous vasculitis, in a few patients together with urticaria (1–3).

A case of vasculitis induced by food colouring is presented.

## CASE REPORT

A 24-year-old woman was seen because of a 6-month history of tender, reddish-brown lesions on the thighs and lower legs. Crops of new lesions occurred at irregular intervals. At the time of examination, she presented with a large number of infiltrated lesions with a symmetrical distribution on the thighs and lower legs. The lesions varied in size from a few mm to 15 mm in diameter. New lesions were bright red, while older lesions were various shades of yellow, brown or blue. A clinical diagnosis of allergic vasculitis was made, and a histological examination showed leukocytoclastic vasculitis (Fig. 1).

Extensive laboratory investigation showed no evidence of underlying disease, such as infection, blood dyscrasias or immunological abnormalities, including collagen diseases.

The patient suspected food items as the cause of the problem, and one eruption occurred after a meal which had included artificially coloured foods. A double-blind, placebo-controlled oral challenge was carried out with the following food additives: 50 mg sunset yellow, 50 mg tartra-

zine, 50 mg ponceau, 250 mg Na-propionate, 500 mg sorbic acid and 250 mg Na-benzoate. The substances were given in identical capsules, and the patient ingested one capsule per week.

The patient experienced a severe eruption of vasculitis 2 h after the ingestion of one capsule which, when the code was broken at the end of the challenge, was found to have contained ponceau. There was associated arthropathy of the ankles and fingers. The eruption (Fig. 2) faded after about one week. A less severe, similar eruption occurred after ingestion of the capsule seen to have contained tartrazine, while none of the other capsules caused any skin reaction.

The patient was instructed to avoid food additives, in particular the azo dyes, ponceau and tartrazine. She was

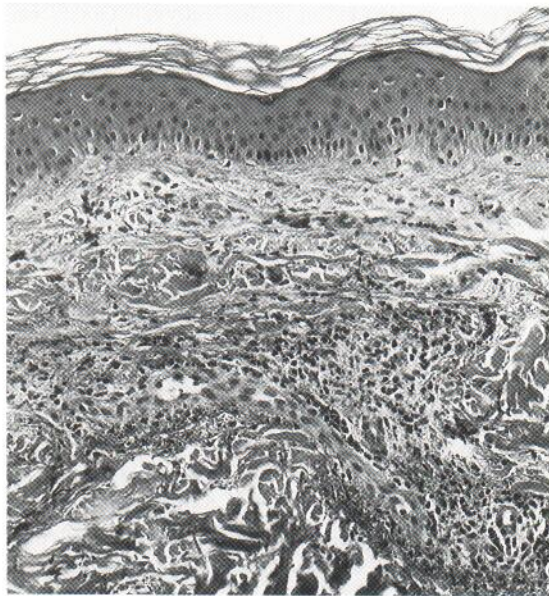


Fig. 1. Leukocytoclastic vasculitis with perivascular infiltrates consisting mostly of neutrophils and nuclear dust. Fibrin deposits can be seen within and around capillaries and venules in the dermis ( $\times 125$ ).

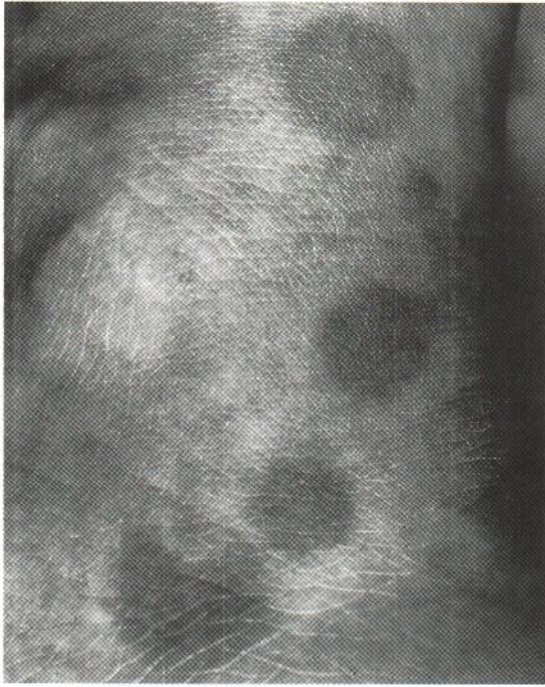


Fig. 2. Reddish-brown palpable infiltrates on the lateral aspect of the left ankle.

free of symptoms when seen 2 months after the initiation of this restrictive diet. A telephone follow-up was made after the patient had restricted the intake of food additives for 6 months, and at this time the said she had experienced only slight eruptions after having inadvertently eaten foods containing additives.

## DISCUSSION

The combination of flares after controlled challenge with azo dyes and cessation of symptoms after following a diet free from food additives suggests that the leukocytoclastic vasculitis seen in this patient was indeed caused by the ingestion of azo dyes.

This type of reaction is rarely reported. Michaëlsson et al. (1) described 7 patients in whom purpura could be reproduced after oral challenge with acetylsalicylic acid or food additives, most commonly tartrazine.

In a review of 330 patients with urticaria, Juhlin (2) found 3 patients who also had purpura. One-third of the 330 patients reacted to oral challenge with various food additives. Some overlap between urticaria and vasculitis has also been seen, and urticarial vasculitis is now an accepted clinical entity (4).

Eisenmann et al. (3) have also reported 2 patients similar to the patient described in the current paper. One of these patients experienced eruptions of vasculitis after the ingestion of whole kernel bread. This patient showed a positive intracutaneous test reaction to rye flour. The other patient in the study reacted to carrot and rice curry. A histological examination of a positive intracutaneous test to carrot showed leukocytoclastic vasculitis. Likewise, Ruzicka et al. (5) found evidence of leukocytoclastic vasculitis in the biopsy of a prick test from a patient who developed vasculitis after ingestion of pyridoxin.

The challenge doses used in the current study were rather high compared with the doses usually recommended for urticaria patients (6). Under certain circumstances it is possible to ingest a relatively high dose of food additives. Häberle (7) found that some types of candy contain as much as 285 mg tartrazine per kilo. Ruzicka (8) has suggested the use of challenge doses of tartrazine in the range 10–50 mg. In view of this information, the doses chosen for the current study do not appear to have been unrealistic.

## ACKNOWLEDGEMENT

This study received financial support from Aalborg Stifts Julelotteri.

## REFERENCES

1. Michaëlsson G, Pettersson L, Juhlin L. Purpura caused by food and drug additives. *Arch Dermatol* 1974; 109: 49–52.
2. Juhlin L. Recurrent urticaria: clinical investigation of 330 patients. *Br J Dermatol* 1981; 104: 369–81.
3. Eisenmann A, Ring J, von der Helm D, Meurer M, Braun-Falco O. Vasculitis allergica durch Nahrungsmittelallergie. *Hautarzt* 1988; 39: 319–21.
4. Wiles JC, Hansen RC, Lynch PJ. Urticarial vasculitis treated with colchicine. *Arch Dermatol* 1985; 121: 802–805.
5. Ruzicka T, Ring J, Braun-Falco O. Vasculitis allergica durch Vitamin B<sub>6</sub>. *Hautarzt* 1984; 35: 197–199.
6. Juhlin L. Additives and chronic urticaria. *Ann Allergy* 1987; 59: 119–23.
7. Häberle M. Klinische und lebensmittelchemische Aspekte bei Unverträglichkeitsreaktionen auf Salicylat- und Additiva-haltige Lebensmittel. *Zbl Haut* 1987; 153: 75–95.
8. Ruzicka T. Diagnostik von Nahrungsmittelallergien. *Hautarzt* 1987; 38: 10–15.