

Tuberculosis Cutis Orificialis: An Association with Evans' Syndrome

Sir,

Tuberculosis cutis orificialis is a rare form of cutaneous tuberculosis which occurs on the mucous membranes and periorificial skin due to autoinoculation of mycobacteria from progressive tuberculosis of internal organs (1, 2), especially in the immunodepressive state. It usually presents as a manifestation of advanced systemic disease and poor prognosis (3). Males are more frequently affected than females. According to Tappeiner & Wolff (2), it occurs most commonly in middle-aged or older persons; this condition is only found in about 0.2% of patients with internal tuberculosis in one series. Evans' syndrome is a hematologic disorder that shows autoimmune hemolytic anemia and immune thrombocytopenia; it is probably caused by an immunoregulatory abnormality (4). We here present a case of tuberculosis cutis orificialis which developed alongside Evans' syndrome.

CASE REPORT

A 52-year-old man with a 2-year-history of Evans' syndrome presented with a 5-month history of an expanding perianal ulcer. Twenty years earlier he had been treated with antituberculous drugs for 6 months due to pulmonary tuberculosis. Two years earlier he had been diagnosed as an Evans' syndrome, for which he had been treated with prednisolone, azathioprine and hydroxychloroquine sulfate.

Physical examination of the perianal area revealed a painful, sharply demarcated, 8.5 × 5.5 cm in size, shallow ulcer with erythematous halo (Fig. 1A). Complete blood count was normal (hemoglobin 11.2 g/dl, hematocrit 34.6%, white cell count 6,900/mm³, platelet count 97,000/mm³ and reticulocyte count 1.2%). Anti IgG antibody for herpes simplex virus was positive but anti IgM was negative. Wound culture was negative for herpes simplex virus and positive for *Escherichia coli*.

The CD4/CD8 ratio in peripheral blood was 1.0, and scoring in the Pasteur Merieux multitest was zero. Chest X-ray showed irregular mottled density and small nodular infiltration in both upper lung fields but did not show interval change when compared with old chest films. Small bowel series and barium enema showed multiple nodular filling defect in the terminal ileum and polypoid filling defect in the ileocecal valve area, suggesting intestinal tuberculosis. Mantoux test was negative. Direct smears of sputum and wound for acid-fast bacilli (AFB) were positive and cultures of sputum and wound revealed *Mycobacterium tuberculosis*. *M. tuberculosis* DNA was detected by the polymerase chain reaction technique in a specimen from the skin lesion (Fig. 2). We used two primers based on IS6110 repeated sequence and known to be specific to the *M. tuberculosis* complex. The sequences of the primers were 5'-GCATCGAGGTGGCCAGATGC-3' and 5'-CCTGCGAGCGTAGGCGTCCG-3', described elsewhere (5).

Skin biopsy stained with hematoxylin-eosin showed pseudocarcinomatous hyperplasia in the epidermis and perivascular and granulomatous inflammatory cell infiltration in the dermis. Granuloma was composed of epithelioid cells, mononuclear cells, and a few eosinophils and multinucleated Langhans' type giant cells. Caseation necrosis within the granuloma was absent, but focal degenerative change of connective tissue was present. Focal aggregates of acid-fast bacilli were observed in the dermis, but fungal elements were not observed in the PAS-stained section.

Antituberculous drugs, including isoniazid (400 mg/day), rifampin (600 mg/day), ethambutol (1200 mg/day) and pyrazinamide (1500 mg/day), were prescribed for the patient. In 4 weeks, the lesion improved markedly, leaving an atrophic scar (Fig. 1B), and constituent symptoms were nearly absent.

DISCUSSION

The incidence of cutaneous tuberculosis has declined throughout the world because of the availability of effective antituber-

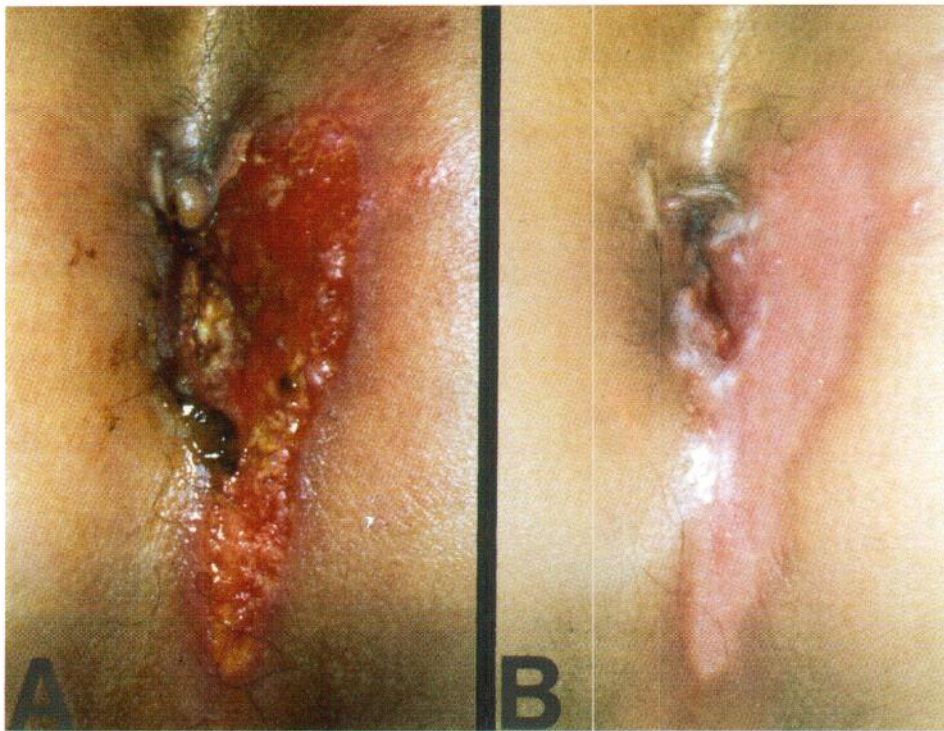


Fig. 1. Ulcerated skin lesion on the perianal area before treatment (A) and 4 weeks after treatment (B).

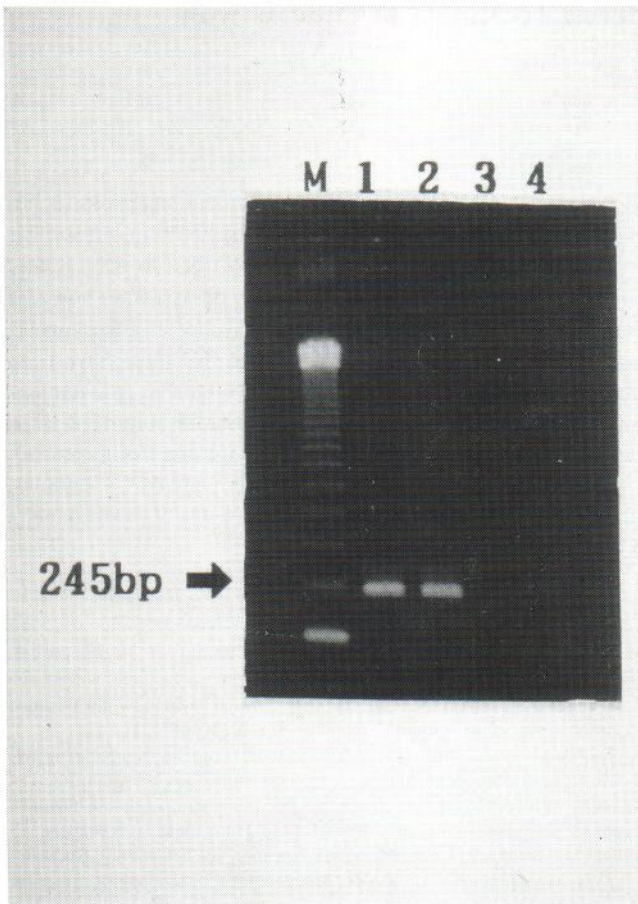


Fig. 2. Result of polymerase chain reaction using primers in a specimen from the skin lesion showed 245 bp amplified product (*Mycobacterium tuberculosis*) (arrow). Lane 1: patient's sample. Lane 2: positive control – *M. tuberculosis* DNA. Lanes 3–4: negative control – distilled water. M: ladder marker.

culous drugs, the elimination of infected milk herds, and an elevation in living standards. However, because of malnutrition and the presence of acquired immunodeficiency syndrome (AIDS), there has been a recent increase in tuberculosis in certain areas of the world (3, 6). Among tuberculosis of the skin, tuberculosis cutis orificialis is extremely rare and typically occurs in patients with advanced underlying pulmonary, intestinal or urogenital involvement (1, 3).

In Evans' syndrome, Wang et al. (8) identified immunoregulatory abnormalities and documented a markedly decreased CD4/CD8 ratio and decreased serum IgM, IgA, and IgG levels. Wilson et al. (4) reported a patient with Evans' syndrome who had a deeply ulcerative lesion of the penis and scrotum, which proved to be herpes genitalis due to herpes simplex virus type 2.

In addition to herpes genitalis, many other ulcerative processes, such as trauma, fixed drug eruption, Behçet's syndrome, syphilis, chancroid, granuloma inguinale, infectious mononucleosis, amebiasis cutis, fungal or mycobacterial infection and malignancy, may occur on the genital area and must also be considered in the differential diagnosis.

In our case, bacterial examination and skin biopsy revealed *M. tuberculosis*. *M. tuberculosis* DNA was demonstrated by the polymerase chain reaction technique in a specimen from the skin lesion.

Considering the overall symptoms, signs, past history and laboratory tests, we believed that this skin lesion resulted from autoinoculation for intestinal tuberculosis and by impaired cellular immunity due to Evans' syndrome itself and from long-term corticosteroid and immunosuppressive therapy for the patient. In this case, radiological study of the intestinal tract showed the probable existence of intestinal tuberculosis.

REFERENCES

1. Savin JA. Mycobacterial infections. In: Champion RH, Burton JL, Ebling FJG, eds. Textbook of dermatology. Oxford: Blackwell Scientific Publications, 1992: 1033–1063.
2. Tappeiner G, Wolff K. Tuberculosis and other mycobacterial infections. In: Fitzpatrick TB, Eisen AZ, Wolff K, Freedberg IM, Austin KF, eds. Dermatology in general medicine. New York: McGraw-Hill, Inc., 1993: 2370–2387.
3. Moschella SL, Cropley TG. Diseases of the mononuclear phagocytic system (the so-called reticuloendothelial system). In: Moschella SL, Hurley HJ, eds. Dermatology. Philadelphia: W. B. Saunders Co., 1992: 1089–1100.
4. Wilson DC, Werth SG, King LE Jr. Ulcerative lesions and herpes simplex virus type 2 in a patient with Evans' syndrome. South Med J 1990; 83: 1484–1486.
5. Thierry D, Cave MD, Eisenach KD, Crawford JT, Bates JH, Gicquel B, et al. IS6110, an IS-like element of *Mycobacterium tuberculosis* complex. Nucleic Acids Res 1990; 18: 188–189.
6. Chaisson RE, Schechter GF, Theuer CP, Rutherford GW, Echenberg DF, Hopewell PC. Tuberculosis in patients with the acquired immunodeficiency syndrome: clinical features, response to therapy, and survival. Am Rev Respir Dis 1987; 136: 570–574.
7. Evans RS, Takahashi K, Durane RT, Payne R, Liu C. Primary thrombocytopenic purpura and acquired hemolytic anemia. Arch Intern Med 1951; 87: 48–65.
8. Wang W, Herrod H, Pui C, Presbury G, Williams J. Immunoregulatory abnormalities in Evans' syndrome. Am J Hematol 1983; 15: 381–390.

Accepted June 27, 1994.

Sung Wook Kim¹, Sung Woo Choi¹, Baik Kee Cho¹, Won Houh¹ and Jong Wook Lee². Departments of ¹Dermatology and ²Internal medicine, St. Mary's Hospital, Catholic University Medical College, 62, Yoido-Dong, Yongdeungpo-Ku, Seoul, 150-010, Korea.