

Scrotal Angiokeratoma in a Young Man

Sir,

An unusual case of angiokeratoma of Fordyce that occurred in a young man is described.

CASE REPORT

A 26-year-old man presented with bleeding from the scrotum. The initial episode of bleeding had occurred 5 months earlier. He had previously noticed some macules, which had increased in number, but which he ignored. He had intended to neglect the bleeding as well, but his sexual partner feared that they might be related to a sexually transmitted disease (STD). So, he was forced to consult the STD branch of our clinic.

The skin of the scrotum showed multiple red or purple lesions, rarely larger than 2–3 mm in diameter (Fig. 1). All lesions were non-tender and there was no evidence of varicocele, tumour of the testis or inguinal hernia. We diagnosed angiokeratoma and as this disease was not an STD, the patient requested no further treatment.

DISCUSSION

Angiokeratoma of the scrotum, which first was described in 1896 by Fordyce in a 60-year-old man, was believed to occur primarily in men over 50 years of age. Recently, patients in

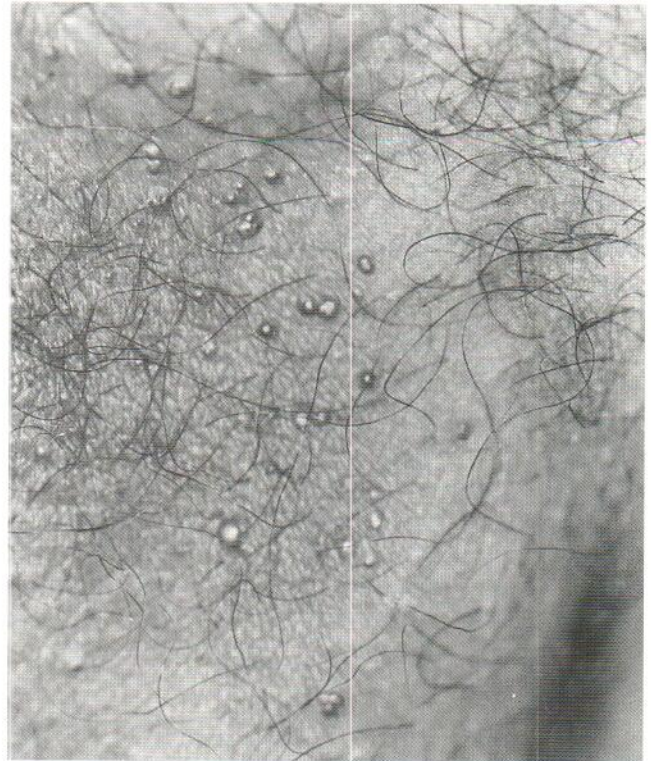


Fig. 1. Multiple red or purple papules scattered over the scrotum.

their forties have been reported, and it is doubtful whether adolescent patients are rare (1-3).

REFERENCES

1. Miller M, Corey GR, Neelon FA. Angiokeratoma of Fordyce. *N C Med J* 1990; 51: 71.
2. Parrotte DM. Angiokeratoma: a cause of scrotal bleeding. *South Med J* 1985; 78: 487-488.
3. Sintes RN, Hernandez JP, Florencio VD, Solano JL. Angioqueratoma. A proposito de 93 observaciones. *Med Cutan Ibero Lat Am* 1988; 16: 255-261.

Accepted May 22, 1995.

Tomoyuki Hisa¹, Shoji Taniguchi¹, Yasushi Goto¹, Hiroyuki Teramae¹, Kazuhisa Osato², Kennichi Kakudo³ and Masaharu Takigawa⁴ ¹Department of Dermatology, Osaka City University Medical School, 1-5-7 Asahimachi, Abeno-ku, Osaka 545, ²Division of Venereology, Osaka Bandai Clinic for Sexually Transmitted Diseases, Osaka, ³Department of Pathology, Wakayama Medical College, Wakayama and ⁴Department of Biochemistry, Okayama University Dental School, Okayama, Japan.