

## Familial Pityriasis Rotunda

Sir,

Pityriasis rotunda (PR) may be regarded as a distinct form of acquired ichthyosis. It is manifested by asymptomatic, round or polycyclic, sharply demarcated, uniformly scaly patches, located primarily over the trunk. Histologically, PR is indistinguishable from ichthyosis vulgaris. By 1960 over 150 cases were reported from Japan and reviewed by Ito & Tanaka (1). The age distribution was 20–45, with a male: female ratio of 73:101 and a prevalence of 0.2 per 1,000 among dermatological patients. They also reported 24 cases of their own, of which 5 were associated with ichthyosis vulgaris (1).

Later reports described PR in non-Japanese patients, including several reports of familial occurrence (2–4).

We report yet another case of familial PR.

### Clinical findings

The propositus was a 16-year-old male, generally in good health, who was examined in the dermatology clinic of the Hadassah University Hospital for asymptomatic skin lesions, which he had noticed since the age of 7. On physical examination he was noted to have five perfectly round, sharply demarcated, flat, uniformly scaly, hyperpigmented lesions with a diameter of 1–6 cm on his upper body (Fig. 1). The patient's sister, aged 14, had also had similar skin lesions since the age of 7. The patient's father, aged 43, had had similar lesions since he was 10 years old and, interestingly, had developed ichthyosis vulgaris of the limbs at the age of 30. The patient's paternal uncle, grandfather and great grandfather all had a skin disorder, the description of which matched the clinical findings found in the patient and was compatible with PR. The family tree revealed an autosomal dominant mode of inheritance with variable penetrance. Apart from the patient's father none of the other afflicted members of the family had ichthyosis vulgaris lesions.

### Laboratory and histopathological examination

KOH testing for dermatophytes of scales taken from lesions of the first patient was negative.

A biopsy revealed compact hyperkeratosis with follicular plugging, irregular lentiginous hyperplasia of the epidermis with markedly increased melanin pigment along the basal layer and a scant perivascular lymphocytic infiltrate with a few melanophages in the dermis.

There seems to be sufficient evidence to attempt to classify PR into three different categories:

- (1) PR associated with systemic disease, mainly malignancy, tuberculosis, chronic infections, liver disease, ovarian and uterine diseases and undernutrition. It is hard to find out whether these associations are actually causative or just

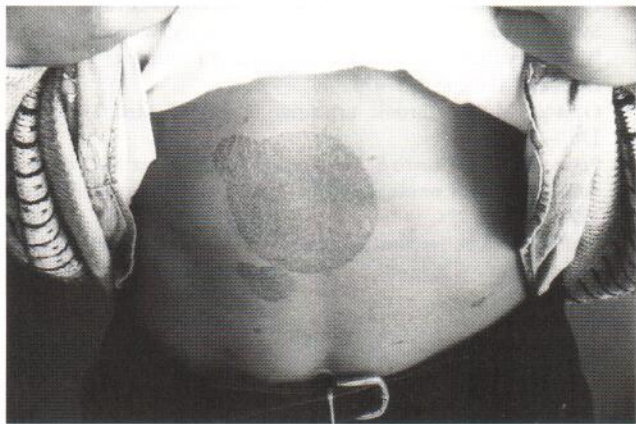


Fig. 1. A perfectly round, sharply demarcated, flat, uniformly scaly, hyperpigmented lesion with a diameter of 8 cm on the skin of the upper part of the abdomen.

- incidental; like acquired ichthyosis vulgaris, non-familial acquired PR should probably merit a malignancy screen.
- (2) Sporadic occurrence of PR in otherwise healthy individuals.
- (3) Familial PR, inherited in an autosomal dominant mode.

PR has been observed to heal spontaneously in a few cases, or to wax and wane (1), but no effective treatment exists. Treatment of the underlying disease may improve the cutaneous disorder, and improvement after oral vitamin A has also been observed.

### REFERENCES

1. Ito M, Tanaka T. Pseudo-ichthyose acquise en taches circulaires. *Ann Dermatol Syphilol* 1960; 87: 26–37.
2. Grimalt R, Gelmetti C, Brusasco A, et al. Pityriasis rotunda: report of a familial occurrence and review of the literature. *J Am Acad Dermatol* 1994; 31: 866–871.
3. Lodi A, Betti R, Chiarelli G, Carducci M, Crosti C. Familial pityriasis rotunda. *Int J Dermatol* 1990; 29: 483–485.
4. Zina AM, Ubertalli S, Bundino S. Pityriasis rotunda. *Int J Dermatol* 1986; 25: 56–57.

Accepted September 5, 1996.

D. Guberman<sup>1</sup>, D. A. Lichtenstein<sup>2</sup>, L. Gilead\*<sup>2</sup>, D. A. Vardy<sup>2</sup> and S. N. Klaus<sup>2</sup>

<sup>1</sup>The Medical Corps, Israel Defense Army, and <sup>2</sup>Department of Dermatology, Hadassah University Hospital, P.O. Box 12000, IL-91-120 Jerusalem, Israel.

\* Offprint requests.