

Spontaneous Photo-onycholysis in a West Indian with Type V Skin*

Sir,

Numerous drugs have occasionally been incriminated as causing photo-onycholysis. Three different clinical varieties of drug-induced photo-onycholysis have been described (1). In all of them, the lateral margins of the affected nails are never involved in the process. In contrast to drug-induced photo-onycholysis, which most commonly occurs with the use of tetracyclines or psoralens, both with natural sunlight and with artificial light sources in psoralens and ultraviolet A, spontaneous photo-onycholysis is an unusual condition (2-4).

CASE REPORT

A 39-year-old mechanical engineer of West Indian origin presented with isolated onycholysis of the first three fingers of each hand (Fig. 1), with sparing of the lateral margins of the involved nail plates; this onycholysis was preceded by subungual pain. The toenails were spared (the subject always wore shoes). According to the patient, this nail dystrophy had appeared every July since his arrival in France, 18 years previously. He also developed a recurrence one December when he returned to his native Martinique.

Investigations revealed a normal full blood count, liver function tests, blood urine and stool porphyrins, and antibody screen including ANF.

Protein electrophoresis, serum iron and pyridoxine did not show any abnormalities. The patient did not receive any medication.

Cutaneous phototesting of the patient, an Afro-Caribbean with type V skin, demonstrated an MED to UVB of 72 mJ/cm², and immediate pigment darkening (IPD) to UVA at 6 J/cm², which was normal. Irradiation tests were also performed on different finger nails with UVB (150 mJ/cm²) and UVA (60 J/cm²); both failed to repro-

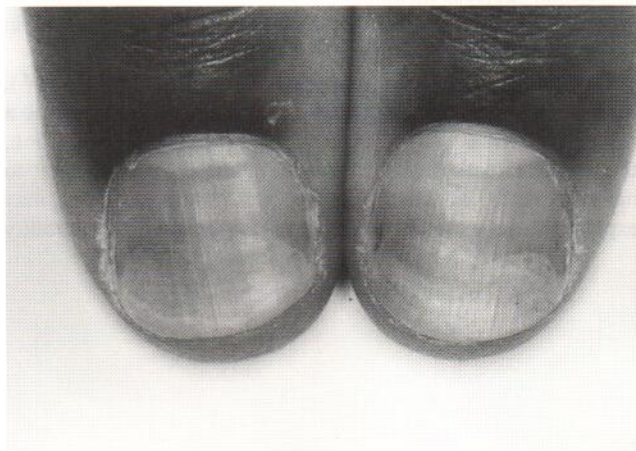


Fig. 1. Photo-onycholysis of both thumbs.

duce onycholysis. The radiation source was Osram Xenon lamps 2,500 W and metal halide UVA lamp.

In an ideal case the following investigations would be indicated, that is provocation using repeated UVA radiation to the nail plate during the period of May and June, (before the onset of the recurrent photo-onycholysis).

Trimming of the distal portion of the nail plate of the right third finger showed keratin dust, an aspect identical to that already described in the trimmed nails of patients presenting with drug-induced photo-onycholysis.

The nail matrix biopsy demonstrated melanin granules forming dark columns and keratinocytes containing non-aggregated melanosomes (of negroid type), along with keratinocytes containing rapidly digested melanosome complexes (as observed in Caucasians) (Fig. 2).

* Presented at the Vth. Jean-Louis ALIBERT International Symposium (19-21 May, 1995, Munich. *Akt Dermatol* 1996; 22:70-71).

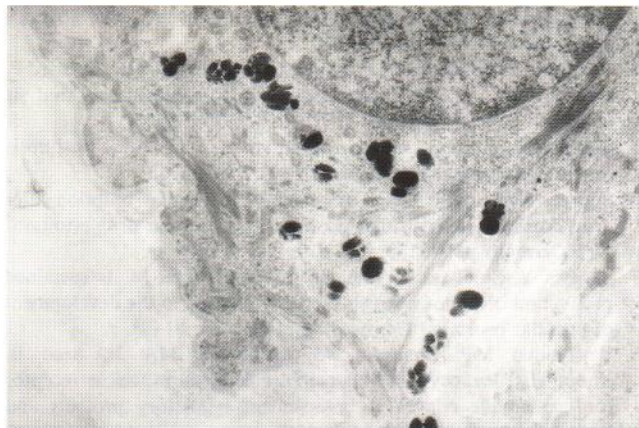


Fig. 2. Keratinocyte with compound melanosomes in the process of digestion. In the same cell are found isolated large melanosomes characteristic of the negroid type. (Electronic microscopy $\times 20,000$).

DISCUSSION

The nail bed is relatively lacking in melanin. Our inquiries at a number of American Universities dealing predominantly with Afro-Americans suggested that drug-induced photo-onycholysis was not recognised as a problem (1). This may indicate that the melanosomes of these subjects have a protective effect, since variations in racial pigmentation are due to the number and size of melanosomes produced. Moreover, in Caucasian subjects, melanosomes contain only a few melanized type IV melanosomes (opaque to electrons) which are, in contrast, abundant in other races before irradiation.

Despite the specific phototype of our patient (type V), biopsy demonstrated large areas of subungual tissue lacking a protective melanin shield against solar radiation. In addition, the photoprotection which the opaque melanosomes ought to have provided, at least partially, was ineffectual: this may explain the appearance of the photo-onycholysis. The inability

to reproduce photo-onycholysis with phototest implies the existence of factors other than light which may also play a role in the separation of the nail plate from the nail bed. Parodi et al. (3) thought that specific components of the solar spectrum, such as infra-red, deserved further investigation, unless endogenous photosensitizing factors or exogenous factors acting beneath the free edge of the nail plate or the hyponychium were instead responsible. The possibility of varying individual thresholds of sensitivity to light exposure remains hypothetical. We are therefore forced to assume an additional unknown factor. Interestingly, 4 out of the 6 recorded patients with photo-onycholysis were Caucasian males (2-3), one a West Indian, while the female patient was Japanese (4). In 3 cases, the presenting symptom was subungual pain (2).

There is no specific treatment for recurrent spontaneous photo-onycholysis. Azathioprine, effective in actinic reticuloid, given 1 month before the anticipated onset, could be considered, as well as nail varnish protection.

REFERENCES

1. Baran R, Juhlin L. Drug-induced photo-onycholysis. Three subtypes identified in a study of 15 cases. *J Am Acad Dermatol* 1987; 17: 1012-1016.
2. Logan RA, Hawk JLM. Spontaneous photo-onycholysis. *Br J Dermatol* 1985; 113: 605-610.
3. Parodi A, Guarrera M, Rebora A. Spontaneous photo-onycholysis. *Photodermatology* 1987; 4: 160-161.
4. Horio T. Spontaneous photo-onycholysis. *J Dermatol* 1988; 15: 540-542.

Accepted September 4, 1996.

R. Baran¹, M. Jeanmougin² and J. P. Cesarini³

¹ Nail Disease Centre, 42, Rue des Serbes, FR-06400 Cannes, ² Photobiology Department, Hôpital Saint-Louis, and, ³ Laboratoire de Recherche sur les Tumeurs de la Peau Humaine, Fondation A. de Rothschild, Paris, France.