

## Evaluation of PUVA Bath Phototoxicity

NORBERT J. NEUMANN<sup>1</sup>, MARTINA KERSCHER<sup>2</sup>, THOMAS RUZICKA<sup>1</sup> and PERCY LEHMANN<sup>1</sup>

Departments of Dermatology, <sup>1</sup>Heinrich-Heine-University, Düsseldorf, and <sup>2</sup>University of Bochum, Germany

**Administration of 8-methoxypsoralen in a dilute bath water solution is an effective therapeutic alternative to its systemic application, avoiding systemic side effects. Although PUVA bath photochemotherapy is now widely used, standardized guidelines are not yet available. Therefore, the aim of our study was to determine the optimal time interval between 8-methoxypsoralen bath and UVA irradiation and the persistence of photosensitivity after PUVA bath treatment. In volunteers the highest photosensitivity was observed following UVA irradiation immediately after PUVA bath. A sharp increase of the minimal phototoxic dose could be demonstrated after only 1 h, indicating a rapid loss of 8-methoxypsoralen activity. Irradiation 2 h after 8-methoxypsoralen bath failed to induce any PUVA erythema. This indicates that the optimal time for UVA irradiation is immediately after the 8-methoxypsoralen bath. In contrast to systemic PUVA therapy, 2 h after PUVA bath therapy, the remaining phototoxicity is minimal, so that no stringent restrictions of the patient's behaviour are needed. Key words: 8-methoxypsoralen; side-effects; PUVA bath therapy.**

(Accepted February 12, 1997.)

Acta Derm Venereol (Stockh) 1997; 77: 385–387.

N.J. Neumann, M.D., Department of Dermatology, Heinrich-Heine-University Düsseldorf, Moorenstr. 5, DE-40225 Düsseldorf, Germany.

Systemic PUVA photochemotherapy was introduced by Parrish et al. (1), as a new treatment modality for psoriasis in 1974. Subsequently, various well-conducted multicenter studies demonstrated PUVA photochemotherapy to be a very effective therapeutic modality for psoriasis. However, systemic administration of 8-methoxypsoralen (8-MOP) may be associated with systemic side effects (e.g. nausea) and requires special sun glasses (protection) to prevent cataractogenesis. Furthermore, drug bioavailability is a major problem in systemic PUVA photochemotherapy (2, 3). Topical application of psoralens followed by UVA irradiation has been suggested as an alternative to systemic PUVA photochemotherapy. The methods of topical administration comprise a variety of lotion, cream and ointment vehicles. But these methods are sometimes laborious, and the treatment often causes uneven, persistent hyperpigmentations in combination with poorly controlled phototoxicity (4, 6, 7). This is not the case with PUVA bath photochemotherapy: erythema and blistering were less common (4, 5, 8, 9) in patients treated with PUVA bath, compared with patients treated with systemic or topical PUVA administration. In 1986 Lowe et al. (4) compared systemic PUVA therapy with PUVA bath treatment, using 8-MOP. Both procedures showed a similar therapeutic efficacy, but following PUVA bath treatment no systemic side-effects were observed. Moreover, plasma levels of 8-MOP are significantly lower following a PUVA bath procedure (2). Additionally, the cumulative UVA dosage needed was significantly lower

employing PUVA bath photochemotherapy. Thus, administration of 8-MOP in a dilute bath water solution in combination with UVA irradiation has proved to be an effective therapeutic alternative for systemic application of 8-MOP, avoiding systemic side-effects. Therefore, PUVA bath photochemotherapy is now increasingly used for a variety of dermatoses (4, 6, 8, 9). Although Fischer & Alsins (10) and Koulu & Jansén (11) described the photosensitivity of normal skin irradiated immediately after an 8-MOP bath, study-generated standardized guidelines concerning 8-MOP concentration and time interval between bath and UVA irradiation are still lacking. Therefore, the aim of our study was to determine the optimal time interval between an 8-MOP bath and UVA irradiation, as well as the persistence of photosensitivity in normal skin after PUVA bath treatment.

### MATERIALS AND METHODS

Eleven volunteers (2 females and 9 males, 22–45 years old), with no history of skin diseases, were enrolled in this study after giving informed consent.

The right or left forearm was immersed for 20 min in a 5-mg/l water solution of 8-MOP (Meladinine<sup>®</sup> 0.15%, Basotherm Biberach, Germany) at a constant temperature of 37.5°C. This concentration was chosen according to the concentrations used for PUVA bath therapy (0.5–10 mg/l), as described in the literature (4, 6–11). Immediately after bathing, the volar site of the lower forearms was exposed to UVA (320–400 nm, Philips 20W/TL09 fluorescence bulbs). Doses of 0.25, 0.5, 1, 1.25, and 1.5 J/cm<sup>2</sup> UVA were applied on 1-cm<sup>2</sup> test sites immediately, 20, 40, 60, and 120 min after the 8-MOP bath. The Minimal Phototoxicity Dose (MPD) was evaluated 72 h after irradiation.

In order to determine the optimal time interval between the 8-MOP bath and UVA irradiation as well as the persistence of photosensitivity in normal skin after PUVA bath treatment, in addition to the detection of the MPD, the degree of skin erythema was assessed 72 h after the PUVA bath, using a semiquantitative five-point rating scale: 0 = no reaction; 1 = faint erythema with indefinite borders; 2 = erythema with sharp borders; 3 = erythema with oedema; 4 = erythema with vesicles or bullae. For comparison of the erythematous reactions the erythema scores of all test sites were added together to estimate the erythema sum score.

### RESULTS

In skin areas irradiated immediately after the PUVA bath, the MPD ranged from 0.25 to 1 J/cm<sup>2</sup>. Following an irradiation 20 min after PUVA bath, the MPD ranged from 0.5 J/cm<sup>2</sup> to 1.25 J/cm<sup>2</sup> and 40 min after PUVA bath, the MPD ranged from 0.5–1.5 J/cm<sup>2</sup>, but a phototoxic reaction could be provoked only in 57.4% (*n* = 6) of the volunteers. Irradiated 60 min after PUVA bath, only 2 volunteers showed a relevant phototoxic reaction, with an MPD of 1.5 and 1.25 J/cm<sup>2</sup>. The MPD was relatively uniform in the test areas, which were irradiated immediately and 20 min after the 8-MOP bath (Fig. 1).

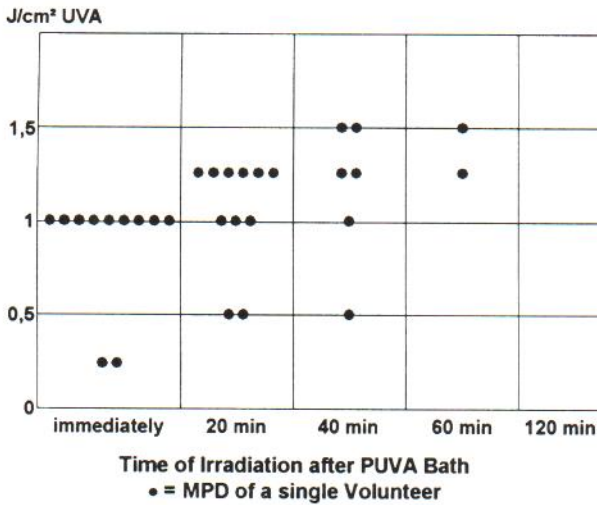


Fig. 1. Minimal phototoxicity dose (●) 72h after UVA irradiation. Irradiation immediately, 20, 40, 60, and 120 min after PUVA bath.

For comparison of the erythematous reactions, the erythema scores of all test sites of any irradiation series were added together by employing the five-point erythema rating scale to estimate the erythema sum score.

In test areas irradiated immediately after PUVA bath, the erythema sum score showed the highest values (Fig. 2). The erythema sum score showed a slightly reduced phototoxicity in test areas irradiated only 20 min after PUVA bath. A sharp increase of the MPD ( $>1.5$  J/cm<sup>2</sup> UVA) and a very low erythema sum score could be demonstrated in the test areas which were irradiated 60 min after the 8-MOP bath (Figs. 1,2). In 9 volunteers (81.8%) no PUVA erythema could be detected up to 1.5 J/cm<sup>2</sup> UVA. These findings indicate a sharp loss of 8-MOP photoactivity after only 1 h. Accordingly, irradiation 2 h after the 8-MOP bath failed to induce any PUVA erythema in our subjects (Figs. 1,2).

## DISCUSSION

In Scandinavia and Germany PUVA bath photochemotherapy is widely used for a variety of dermatoses (4, 6–8). Standardized guidelines concerning 8-MOP concentration and time interval between bath and UVA irradiation are not yet available. Therefore, it is important to determine the optimal time between the 8-MOP bath and the UVA irradiation, as well as the persistence of photosensitivity in normal skin after PUVA bath treatment. In contrast to Koulu & Jansén (11), we observed that the erythematous reaction most often peaked 72 h after the UVA irradiation. So, following our experience and guided by Calzara-Pinton et al. (8) and Kerscher et al. (12), we performed the readings 72 h after application of UVA. The photosensitivity reaches its maximum in test areas irradiated immediately after the PUVA bath. Looking at the MPD and the erythema sum score (Figs. 1,2), the photosensitivity was slightly decreased only 20 min after irradiation. A sharp increase of the MPD ( $>1.5$  J/cm<sup>2</sup> UVA) and only a low erythema sum score could be demonstrated in the volunteers,

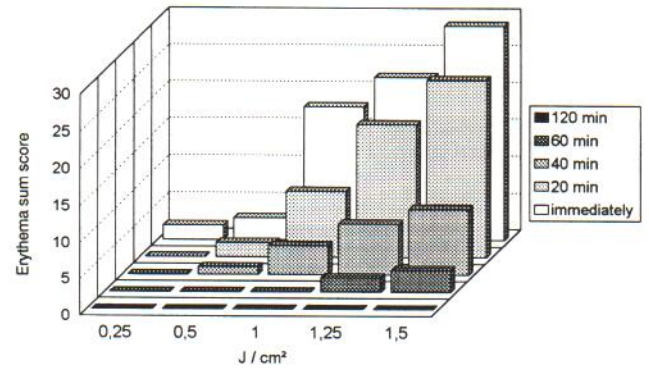


Fig. 2. Erythema sum score 72 h after UVA irradiation. Irradiation immediately, 20, 40, 60, and 120 min after PUVA bath.

who were irradiated 60 min after the 8-MOP bath. These findings indicate a sharp loss of 8-MOP activity after only 1 h. Irradiation 2 h after 8-MOP bath failed to induce any PUVA erythema with the used UVA doses.

Following our results, the optimal time for UVA irradiation seems to be immediately after the PUVA bath but should not be performed more than 20 min later, since 40 min after the PUVA bath a relevant phototoxic reaction was observed only in 54.5% ( $n=6$ ) of the treated volunteers. For practical use, it is therefore mandatory to have the bath tube near the phototherapy unit. Moreover, the patients should be carefully monitored concerning the time between bath and irradiation. Although this requires a rigid management, the patients profit immensely due to the rapid loss of phototoxicity, since no stringent restrictions concerning their everyday life have to be followed. Data of our long-term phototoxicity study showed no risk of a relevant phototoxic skin damage 5 h after PUVA bath (13).

## REFERENCES

- Parrish JA, Fitzpatrick TB, Tannenbaum L, Pathak MA. Photochemotherapy of psoriasis with oral methoxypsoralen and long wave ultraviolet light. *N Engl J Med* 1974; 291: 1207–1212.
- Thomas SE, O'Sullivan J, Balac N. Plasma levels of 8-methoxypsoralen following oral or bath-water treatment. *Br J Dermatol* 1991; 125: 56–58.
- Gasparro FP. Current opinion in dermatology. 2nd edn. 1995: 167–172.
- Lowe N, Weingarten D, Bourget T, L Moy L. PUVA therapy for psoriasis: comparison of oral and bath-water delivery of 8-methoxypsoralen. *J Am Acad Dermatol* 1986; 14: 754–760.
- Kerscher M, Gruss C, von Kobyletzki G, Volkenandt M, Neumann NJ, Altmeyer P, et al. Time course of 8-MOP-induced skin photosensitization in PUVA bath photochemotherapy. *Br J Dermatol* 1996; in press.
- Grimes E, Minus H, Chakrabarti S. Determination of optimal photochemotherapy for vitiligo. *J Am Acad Dermatol* 1982; 7: 771–778.
- Collins P, Rogers S. Bath water compared with oral delivery of 8-methoxypsoralen PUVA therapy for chronic plaque psoriasis. *Br J Dermatol* 1992; 27: 392–395.
- Calzavara-Pinton PG, Ortel B, Hönigsmann H, Zane C, De

- Panfilis G. Safety and effectiveness of an aggressive and individualized bath PUVA regimen in the treatment of psoriasis. *Dermatology* 1994; 189: 256–259.
9. Kerscher M, Lehmann P, Plewig G. PUVA-Bad-Therapie. *Hautarzt* 1994; 45: 526–528.
  10. Fischer T, Alsins J. Treatment of psoriasis with trioxsalen baths and dysprosium lamps. *Acta Derm Venereol (Stockh)* 1976; 56: 383–390.
  11. Koulu L, Jansén CT. Skin photosensitizing and Langerhans' cell depleting activity of topical (bath) PUVA therapy: comparison of trimethylpsoralen and 8-methoxypsoralen. *Acta Derm Venereol (Stockh)* 1983; 63: 137–141.
  12. Kerscher M, Volkenandt M, Meurer M, Lehmann P, Plewig G, Röcken M. Treatment of localised scleroderma with PUVA bath photochemotherapy. *Lancet* 1994; 14: 343; 1233.
  13. Neumann NJ, Kerscher M, Ruzicka T, Lehmann P. Rapid decrease of phototoxicity after PUVA bath therapy with 8-methoxypsoralen. *Arch Dermatol* 1996; 132: 1394.