

## White Sponge Naevus Successfully Treated with Tetracycline Mouth Rinse

Sir,

White sponge naevus is a rare autosomal dominant benign condition, characterized by non-painful spongy corrugated whitish plaques of the oral mucosa. More rarely, the nasal, vaginal and anal mucosa may be affected (1, 2). Differential diagnosis includes lichen planus, candidiasis, human papillomavirus infection, verrucous epidermal naevus, hereditary benign intraepithelial dyskeratosis, hereditary mucoepithelial dysplasia and pachyonychia congenita.

We report the sporadic case of a 12-year-old girl with a 6-year history of ill-defined folded white plaques of nearly the entire oral cavity, with predominant involvement of the buccal mucosa (Fig. 1). No lesions were found on the genital and anal mucosa. For the last 3 years the patient had experienced discomfort due to stringy desquamation, which caught between the teeth.

Oral candidiasis was ruled out by repeated negative cultures on Sabouraud's medium. Histological examination showed groups of pale-staining and vacuolated cells within the spinous layer of a markedly acanthotic epidermis. Results of immunohistochemical studies on paraffin-embedded sections were negative for human papillomavirus DNA. On ultrastructural examination, an atypical paranuclear aggregation of tonofilaments in suprabasal keratinocytes was observed. On the basis of history, clinical appearance, histological and ultrastructural findings a white sponge naevus was diagnosed (1-3).

The therapy of white sponge naevus is often problematic. Antihistamines, nystatin, vitamins and liquid nitrogen have been tried but are mostly unsuccessful. Parenteral penicillin, ampicillin and topical 0.05% tretinoin have been used with varying success. In view of 2 encouraging recent reports our patient was treated with 0.25% aqueous tetracycline mouth rinse twice daily (4, 5). On re-examination after 3 weeks, the oral plaques had considerably flattened and the patient was free of symptoms. In the following months, she was able to control exacerbations by demand application. The mode of action of tetracyclines is unknown but appears to be related not solely to its antibiotic effect (4, 5).

Discoloration of the teeth is a well-known side-effect in children who receive tetracyclines during mineralization of the deciduous or permanent teeth, i.e. before the age of 8 years. Therefore, in children dental examinations should be performed before and during treatment with tetracyclines.

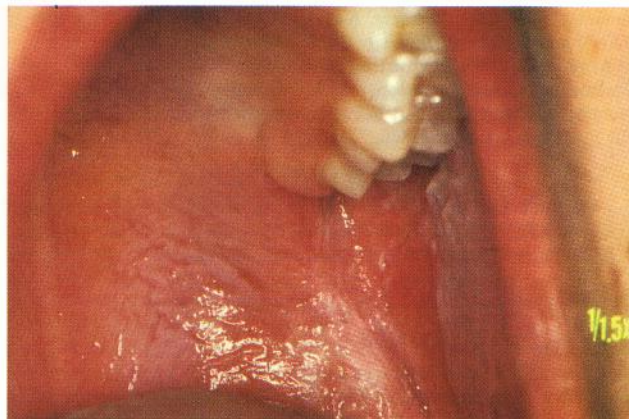


Fig. 1. White sponge naevus of the oral mucosa in a 12-year-old girl before treatment.

In conclusion, tetracycline mouth rinse appears to be an effective and safe treatment in symptomatic cases of white sponge naevus.

### REFERENCES

1. Schaarschmidt H, Wollina U, Roth H. Naevus spongiosus et albus mucosae. *Hautarzt* 1992; 43: 35-37.
2. Jorgenson RJ, Levin LS. White sponge nevus. *Arch Dermatol* 1981; 117: 73-76.
3. Frithiof L, Banoczy J. White sponge nevus (leukoedema exfoliativum mucosae oris): ultrastructural observations. *Oral Surg* 1980; 41: 607-622.
4. McDonagh AJG, Gawkrödger DJ, Walker AE. White sponge nevus successfully treated with topical tetracycline. *Clin Exp Dermatol* 1990; 15: 152-153.
5. Lim J, Ng SK. Oral tetracycline rinse improves symptoms of white sponge nevus. *J Am Acad Dermatol* 1992; 26: 1003-1005.

Accepted April 14, 1997.

L. R. Becker, C. Lurz, H. Erhard, E.-B. Bröcker and H. Hamm  
Department of Dermatology, University of Würzburg, Josef-Schneider-Str. 2, DE-97080 Würzburg, Germany.