

REVIEW ARTICLE

Genital Psoriasis: A Systematic Literature Review on this Hidden Skin Disease

Kim A. P. MEEUWIS^{1,2}, Joanne A. DE HULLU², Leon F. A. G. MASSUGER², Peter C. M. VAN DE KERKHOF¹ and Michelle M. VAN ROSSUM¹

Departments of ¹Dermatology and ²Obstetrics and Gynaecology, Radboud University Nijmegen Medical Centre, Nijmegen, The Netherlands

It is well known that the genital skin may be affected by psoriasis. However, little is known about the prevalence and clinical appearance of genital psoriasis, and genital skin is often neglected in the treatment of psoriatic patients. We performed an extensive systematic literature search for evidence-based data on genital psoriasis with respect to epidemiology, aetiology, clinical and histopathological presentation, diagnosis and treatment. Three bibliographical databases (PubMed, EMBASE and the Cochrane Library) were used as data sources. Fifty-nine articles on genital psoriasis were included. The results show that psoriasis frequently affects the genital skin, but that evidence-based data with respect to the efficacy and safety of treatments for genital psoriasis are extremely limited. An advised treatment paradigm for genital psoriasis, based on the levels of evidence, is: first-line: (weak) topical corticosteroids; second-line: vitamin D preparations or tar-based treatments. Key words: psoriasis; inverse psoriasis; flexural psoriasis; male/female genital diseases; genital; treatment.

(Accepted June 29, 2010.)

Acta Derm Venereol 2011; 91: 5–11.

Kim A. P. Meeuwis, Department of Dermatology (370), Radboud University Nijmegen Medical Centre, PO Box 9101, NL-6500 HB Nijmegen, The Netherlands. E-mail: k.meeuwis@derma.umcn.nl

A wide range of cutaneous diseases can affect the female and male genital skin. Some of these dermatoses are entirely or predominantly present in this region, while others, such as psoriasis, primarily involve non-genital skin.

Psoriasis is a chronic, inflammatory epidermal skin disease with a high prevalence in the general population of approximately 2% (1–3). It is one of the most commonly seen dermatoses of genital skin, although often limited attention is paid to the genital presentation of this skin disease. In many cases, genital psoriasis is part of a more generalised plaque psoriasis, although the external genitalia may be the only area affected. However, the isolated presentation of psoriasis solely on genital skin seems to be rare and occurs in only 2–5% of the psoriatic patients (4, 5). Genital skin can also be affected in cases

of inverse psoriasis (synonym: flexural or intertriginous psoriasis) (2, 4, 5).

The external genital skin is generally classified as flexural skin, although it forms a unique area comprising different structures and types of epithelium. The epithelium covering the different structures of the vulva changes from stratified, keratinised squamous cell epithelium on the outer parts to mucosa on the innermost regions (5, 6). Similarly, the male genital epithelium has a different pattern of keratinisation throughout the genital area. The prepuce forms the anatomical covering of the glans penis and is the junction between the mucosal surface of the glans and coronal sulcus and the keratinised squamous cell epithelium of the remaining external genital skin (7).

In general, the unique microenvironment of the genital region may have consequences for the clinical appearance of skin diseases. Genital skin folds are susceptible to maceration and fissuring due to the combination of moisture, warmth and friction. In addition, the genital area is often exposed to mechanical and chemical irritation. Consequently, the normal characteristics of common dermatoses may be lost or modified in the genital region. Moreover, as a result of their location, these dermatoses may be confused with sexually transmitted diseases. Because of the high sensitivity of the vulnerable, thin genital skin and the increased penetration of topical treatments applied to this site of the body, treatment of genital lesions is a challenge.

Psoriasis affecting genital skin may be associated with considerable morbidity, discomfort and embarrassment and may considerably impair quality of life and psychosexual wellbeing. This review covers both female and male genital psoriatic lesions. Epidemiology, aetiology, clinical and histopathological findings, diagnosis and the various treatment options are described.

MATERIALS AND METHODS

An extensive literature search was performed to collect evidence-based data on genital psoriasis. Relevant literature published between January 1988 and June 2009 was obtained from three computerised bibliographical databases: PubMed, EMBASE and the Cochrane Library. Additional papers were identified using the “related articles” button in PubMed.

Key words and selection criteria

As key words we used “psoriasis” or “psoriatic”, combined with “inverse”, “inversa”, “intertriginous”, “flexural” or “flexures”. Subsequently, these key words were combined with the following search terms: “groin”, “groins”, “genital*” (truncated), “anogenital*” (truncated), “vulva*” (truncated), “penis”, “penile”, “foreskin”, “prepuce”, “preputial”, “penoscrotal”, “scrotal”, “scrotum”, “inguinal”, “anal”, “anus”, “diaper” and “napkin”. The search and selection of the literature was restricted to publications written in English, Dutch, German or French. Because published data specific for genital psoriasis are extremely limited, we reviewed all available literature, including clinical trials, case reports, retrospective studies, and letters to the editor concerning all types of genital psoriasis.

Study selection: inclusion and exclusion criteria

The selection of studies involved a two-stage process. Titles and abstracts of all identified citations were screened; full-text articles were obtained if potentially relevant according to the abstract. Articles without information on flexural or genital psoriasis were excluded during this first selection step. Articles present in more than one database were included once. Subsequently, two reviewers (KM and MvR) independently and critically assessed the articles for inclusion or exclusion, using a checklist. Levels of evidence and grading recommendations were determined according to the “Oxford Centre for Evidence-based Medicine Levels of Evidence” guidelines, version March 2009 (adapted from <http://www.cebm.net/index.aspx?o=1025>). The Oxford Centre for Evidence-based Medicine suggests levels of evidence (LoE) according to the study design. These levels vary between 1a and 5 – the higher the number, the worse the quality of the evidence. Recommendations are graded from A (strong) to D (weak) based on the LoE.

Articles covering all types of genital psoriatic lesions in all age groups were included. Articles on flexural psoriasis with inadequate/insufficient data on genital psoriasis (e.g. articles that did not discriminate between flexural and genital psoriasis or trials that did not assess the safety and efficacy of the investigated

therapy on genital skin) were excluded. In addition, articles that referred only to other publications were excluded and the source data were retrieved instead. Articles in which genital psoriasis cases were excluded from the analysis, as well as articles about secondary outcome measures, case reports without any supplementary information, and articles that were not available were also excluded. When there was disagreement about article selection, a third investigator (JdH) was consulted. Reference lists in the selected articles were scrutinised to identify other relevant articles that had been overlooked in the database search. Fig. 1 illustrates the complete selection process.

RESULTS

A total of 798 citations that were potentially relevant were identified. Of these, 184 articles seemed to be relevant according to their title and abstract and were selected for detailed evaluation. Forty-two articles were not available since they were published in journals that were unavailable via the libraries of nine European universities. For 98 articles the exclusion criteria appeared to be applicable on closer evaluation. These articles were excluded from further evaluation. In addition, a manual search of the reference lists retrieved a further 15 articles. Consequently, 59 full-text articles were considered appropriate for detailed evaluation (see references 8–66).

Epidemiology

Table I recapitulates the results of several questionnaire-based surveys, showing that involvement of the genital skin occurs in 29–40% of patients with psoriasis (8–12) [LoE: 4]. The genital area may frequently be involved in cases of inverse psoriasis. Of 48 patients with inverse psoriasis, the external genitalia were involved in 38 (79.2%). All the cases concerned were diagnosed by two dermatologists (13) [LoE: 4].

Vulvar psoriasis [LoE: 4]. Psoriasis of the vulva was found in 25 of 1,000 women referred to special vulval clinics (14). In addition, in a group of 101 patients with chronic symptomatic (predominantly itching) vulvar disorders, two (2%) were caused by psoriasis (15).

Two articles focused on non-neoplastic vulvar biopsies. Two biopsies from 114 women who visited a multidisciplinary clinic specialising in non-neoplastic diseases of the vagina and vulva were histologically diagnosed as vulvar psoriasis (16). Of 43 cases with clinical and pathological diagnoses of non-neoplastic alterations of the vulva, three were found to be suffering from psoriasis (17).

An investigation into the pattern of non-venereal dermatoses of the female external genitalia, conducted in a dermatology and gynaecology outpatient department in South India, revealed that five patients out of a total of 120 (4.2%) had psoriasis (18).

Vulvar psoriasis is also frequently seen in children. In an evaluation of 130 prepubertal girls with vulvar

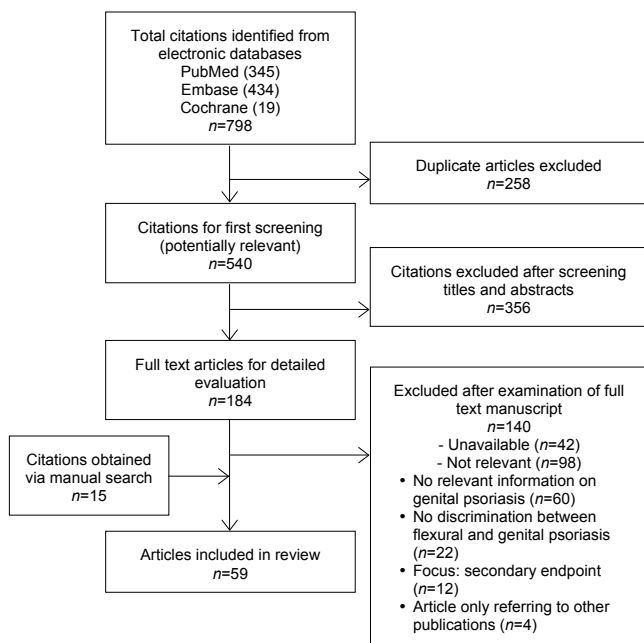


Fig. 1. The selection process for relevant articles on genital psoriasis.

Table I. Involvement of the genital skin in patients with psoriasis

| Source Author, year (ref.) | Number of patients | | | Genital involvement | | |
|----------------------------------|--------------------|------|--------|---------------------|------|----------------------|
| | Total | Male | Female | n | % | Male: Female (%) |
| Hellgren, 1964 (8) | 119 | 73 | 46 | 34 | 28.6 | 24:10 (32.9:21.7) |
| Farber et al., 1968 (9) | 2144 | 968 | 1176 | 663 | 30.9 | 416:247 (43.0:21.0) |
| Farber & Nall, 1974 (10) | 5600 | 2562 | 3038 | 2245 | 40.1 | 1251:994 (48.8:32.7) |
| van de Kerkhof et al., 2000 (11) | 839 | 386 | 453 | 243 | 29.0 | N/A |
| Fouéré et al., 2005 (12) | 1281 | N/A | N/A | 410 | 32.0 | N/A |

N/A: not applicable.

complaints, psoriasis (17%) was the third most common cutaneous condition, after atopic or irritant dermatitis (33%) and lichen sclerosus (18%) (19). Additionally, others found psoriasis to be one of the most common non-venereal dermatoses in a group of prepubertal girls, affecting two (9.5%) of the 21 patients studied (18).

Penile psoriasis [LoE: 5]. One report stated that psoriasis of the penis can be diagnosed in 3% of male patients with alterations of the penile skin who visit specialised clinics (20).

Aetiology

No articles describing or discussing the aetiology of genital psoriasis were retrieved in this systematic review of the literature.

Clinical presentation [LoE: 5]

Psoriatic lesions on the genital skin often present as well-demarcated, brightly erythematous, thin plaques and usually lack, due to maceration, the typical scaling that is apparent on other parts of the body (21–39). However, scales may be seen on the more keratinised regions of the genital skin (34, 40, 41). When scaling is present, it is often minimal and can easily be scraped off, leaving pinpoint bleedings (26, 27, 38, 42).

The appearance of vulvar psoriasis is often symmetrical and can vary from silvery, scaling patches adjacent to the outer parts of the labia majora to moist greyish plaques or glossy red plaques without scaling in the skin folds (33, 35, 40, 42–45).

In male patients, both scrotal and penile skin may be affected. The glans penis is the area of male genital skin that is most commonly affected. Occasionally the entire penis, scrotum, and inguinal folds are involved (25, 26, 30, 41, 46). Whereas in uncircumcised males the well-defined non-scaling plaques are most common under the prepuce and on the proximal glans, in circumcised male patients the red lesions are usually present on the glans and corona (25, 30, 41). Psoriatic genital lesions of the glans and corona in circumcised males can be more scaly than those usually seen in genital skin (25, 41, 47). Some authors suggest that involvement of the genital mucosa may be diagnosed less frequently in women than in men (32, 34, 36).

Genital lesions may be accompanied by rhagades or fissures, which can cause definite soreness (28, 48). Patients with genital psoriasis may also experience pruritus and/or a burning sensation in the affected area, which can range from minimal to marked (23, 26, 30, 36, 42, 49). Psoriasis is generally not associated with scarring. However, one case report described two patients with long-standing severe anogenital psoriasis that was associated with loss of the labia minora. Clinically, this mimicked the scarring associated with lichen sclerosus, but histopathologically the lesions were diagnosed as psoriasis (50). No other reports of genital scarring due to psoriasis were found in our systematic review of the literature.

Due to the Koebner phenomenon, genital psoriasis may be worsened by irritation from urine and faeces, tight-fitting clothes and sexual intercourse (26, 38, 40, 47).

Pustular psoriasis. Although most genital psoriatic lesions represent plaque-type psoriasis, the genital area may also be affected by pustular psoriasis. Both generalised and localised pustular psoriatic eruptions may affect the genital skin (51–53). A case of a 23-year-old man with pustular psoriasis limited to the penis was described. The lesions presented as numerous white papules and pustules on an erythematous base (52). Another patient with recurrent episodes of multiple, painless, circinate, pustular eruptions over the glans penis was found to be suffering from pustular psoriasis on histopathological examination (53). No reports of female genital pustular psoriasis were found in our systematic review of the literature.

Children. Although there is no difference in the presentation of genital psoriasis between children and adults, psoriatic napkin eruption deserves special attention in this review. It has been debated whether this condition should be regarded as psoriasis, seborrhoeic dermatitis or a *Candida* infection, although it is currently assumed that both localised and disseminated psoriatic napkin eruptions may represent psoriasis or a precursor to psoriasis in some children (37, 54–58) [LoE: 4]. The eruption is characterised by confluent erythematous, and sometimes silvery-squamous, plaques with well-defined borders in the napkin area, with the genitals possibly also being affected. Most often the lesions are surrounded by psoriasis-like papules, and may spread to the trunk, limbs and, very frequently, the scalp and

face (37, 55, 56, 58–61) [LoE: 4 and 5]. In a clinical review of 1,262 cases of childhood psoriasis, 13% of the children studied had a psoriatic napkin eruption with dissemination and approximately 4% had a localised psoriatic napkin eruption. In children younger than two years of age psoriatic napkin eruption with dissemination was the most common type of psoriasis. Moreover, anogenital psoriasis occurred four times more often in children over two years of age than in children under two years of age (37) [LoE: 4].

Diagnosis [LoE: 4 and 5]

The diagnosis of genital psoriasis can usually be made on the basis of its clinical appearance. Genital psoriatic lesions may be the only psoriatic features in a particular patient, but more often they are part of a more generalised form of psoriasis. Confirmatory lesions elsewhere or other clinical signs of psoriasis (such as nail deformities or joint complaints) may be present (19, 22–25, 27, 28, 30, 31, 33, 35, 36, 41–43, 45, 46). Skin biopsies are therefore rarely needed, but should not be omitted in inconclusive cases. Table II shows the possible differential diagnoses in cases of genital psoriasis, as mentioned in source articles.

Histologically there is no apparent difference between genital and non-genital psoriasis (14, 16, 17, 22, 23, 27, 28, 34, 41). However, the typical characteristics of psoriasis may be less evident in vulvar and penile psoriatic lesions, which may necessitate a careful search for subtle signs in these cases (17, 50).

Therapy

Case reports [LoE: 4 and 5]. The current literature provides extremely limited evidence for the efficacy and safety of treatment options for genital psoriasis.

Table II. Possible differential diagnoses in cases of genital psoriasis, as mentioned in source articles

| Differential diagnosis | References |
|---|--|
| Dermatitis (variants: seborrhoeic dermatitis, contact dermatitis, atopic dermatitis, spongiotic dermatitis) | 16, 22, 23, 34, 35, 42, 45, 52, 55, 59 |
| Dermatophytosis or candidiasis | 16, 22, 34, 40, 42, 47, 59 |
| Squamous cell carcinoma (<i>in situ</i>) (variants: morbus Bowen, Bowenoid papulosis, erythroplasia de Queyrat) | 21, 26, 30, 34, 41, 46, 52 |
| Plasma-cell balanitis or vulvitis | 21, 34, 40, 41, 46, 52 |
| Lichen planus | 22, 41, 42, 46, 52 |
| Secondary or tertiary (pustular) syphilis | 22, 42, 46, 52, 53 |
| Reiter's syndrome (balanitis circinata) | 41, 47, 52, 53 |
| Lichen simplex chronicus (excoriated) | 16, 23, 42 |
| Extramammary Paget disease | 21, 42 |
| Intertrigo | 22, 34 |
| Fixed drug eruption | 41, 52 |
| Lichen nitidus | 52 |
| Lichen sclerosus | 23 |
| Scabies or pediculosis pubis | 42 |

Only six casuistic reports and one open-label study have roughly described the effects of therapies used. An overview of these reports can be found in Table III. Based on these reports, 1% pimecrolimus cream and topical cyclosporine may produce beneficial effects when used to treat plaque psoriasis of the glans penis and prepuce (62, 63). The application of an ointment containing betamethasone-17-valerate (a potent corticosteroid) three times a day was useful for psoriasis of the labium majus in one patient (42). Corticosteroid ointment was effective in only three out of 67 children with napkin plaque psoriasis, while coal-tar preparations were helpful in the remaining 64 patients. Therapy with zinc paste and salicylic acid was ineffective in these patients (54). Ketoconazole cream was effective against lesions in the napkin area of a four-month-old boy suffering from napkin psoriasis with pustular dissemination, where examination of the scales was positive for fungal infection (64).

Two case reports of pustular psoriasis of the glans and penile shaft were included in our study. One of these suggests a minor effect of the combination of a weak corticosteroid with coal-tar. Systemic treatment with itraconazole (200 mg twice daily for 6 weeks) demonstrated some effect, whereas dapsone (100 mg daily for 4 weeks) was very effective (52, 53).

Expert opinions [LoE: 5]. Twenty-four articles reflected merely the opinions of experts on the preferred treatments for genital psoriasis. We have summarised these different opinions in Table SI (<http://adv.medicaljournals.se/article/abstract/10.2340.00015555-0988>).

Corticosteroids. All authors advise the use of topical corticosteroids. Most of the authors are reluctant in the prescription of corticosteroids for genital psoriasis and only recommend the use of weak (and sometimes, if necessary, moderate) steroids, which may be combined with vitamin D analogues or mild tar preparations (25, 26, 32–34, 40, 41, 47, 60, 61). Although weak corticosteroids are preferable because of their mild side-effects, they often seem insufficiently potent to induce a response. Some experts therefore advise short-term, intermittent use of moderate-to-potent corticosteroids to induce a response, followed by a subsequent gradual shift towards a weaker steroid preparation (14, 35, 36, 43–45, 65). On the contrary, other authors advise intensive, short-term, intermittent use of potent corticosteroids (22, 23, 29, 30, 46, 59, 66).

Coal-tar preparations. The use of mild topical tar preparations (i.e. 1–5% liquor carbonis detergens in aqueous cream) for the treatment of genital psoriasis is frequently recommended and is the second most advised topical therapy after corticosteroids. Tar may be used as an individual topical therapy or, when (maintenance) treatment with weak potent corticosteroids is insufficient, be combined or alternated with topical steroids (25, 35, 36, 40, 41, 44, 45, 65). Tar may also be used

Table III. Case reports/series on treatment of genital psoriasis

| Study characteristics | | | Treatments and outcomes | | | |
|-------------------------------|-------------------|-------------------------------|-------------------------|--|---|---|
| Source | Type of psoriasis | Cohort | Therapy 1 | Therapy 2 | Conclusion/remarks | |
| First author, year (ref.) | Study design | No. patients (M/F, age group) | LoE | Site | | |
| Amichai, 2004 (62) | Case report | 1 (1/0, C) | 5 | Glans penis | 1% pimecrolimus cream, 3 weeks, topical | Treatment was effective and recurrence was treated successfully |
| Jemec & Baadsgaard, 1993 (63) | Open label | 3 (3/0, A) | 4 | Glans penis & inner fold prepuce (=mucosal skin) | Topical cyclosporine (100 mg/ml) as a wet dressing, 3 times a day | Marked local improvement within 4 weeks; no side effects |
| Weinrauch & Katz, 1986 (42) | Case report | 1 (0/1, A) | 5 | Labium majus | Betamethasone-17-valerate ointment, 3 times a day | Lesions disappeared in several days |
| Andersen & Thomsen, 1971 (54) | Case series | 67 (35/32, C) | 4 | Napkin area | Corticosteroid ointment: only effective in three patients | Zinc paste and salicylic acid ointment were ineffective |
| Watanabe et al., 2002 (64) | Case report | 1 (1/0, C) | 5 | Napkin area | 0.2% ketoconazole cream | Lesions gradually resolved (complete clearance within one month) |
| Quan & Ruben, 1996 (52) | Case report | 1 (1/0, A) | 5 | Glans penis and distal penile shaft | 1% hydrocortisone and 2% coal-tar: little improvement | Itraconazole 200 mg, twice daily for 6 weeks: possible Candida colonization |
| Singh & Thappa, 2008 (53) | Case report | 1 (1/0, A) | 5 | Glans | Dapsone, 100 mg daily | Lesions subsided completely in 4 weeks |

M: male; F: female; LoE: level of evidence; C: children; A: adults.

for napkin psoriasis, for example mixed with zinc oxide (60, 61). Despite these positive opinions regarding the use of coal-tar preparations, there are also reports that advise against the use of tar preparations because of their potential to cause irritation (22, 29, 32, 33). Others point out the importance of the choice of the vehicle, as tar gels may be too irritating to sensitive genital skin and tar ointment may cause folliculitis in hairy areas. They suggest that mixing a tar preparation with a steroid preparation may reduce irritation (40).

Vitamin D analogues. Vitamin D analogues are another possible non-steroidal treatment for genital psoriatic lesions, in particular those affecting male genital skin (25, 26, 30, 46). They can be prescribed as monotherapy or in combination with steroid preparations (25). Vitamin D analogues may cause irritation, which may be minimised by their combination with steroids (25, 46). Nevertheless, some authors advise against the use of vitamin D analogues, as these may be too irritating to apply to the genital area (33, 60).

Immunomodulators. One author expressed the opinion that the use of pimecrolimus ointment or tacrolimus cream may be useful (33), while acknowledging that they may cause local irritation and stinging. Monitoring of possible complications of immunomodulators is advised, as they can cause irritant or allergic contact dermatitis, candidiasis, or (re)activation of viral skin infections.

Other modalities/General advice. Suspected concurrent bacterial or fungal infections of the genital area should be treated with topical antibiotics or ketoconazole/miconazole, respectively, to eliminate the possible Koebner effect (23, 26, 30, 32, 35, 36, 40, 46, 60). Moreover, minimising contact with local irritating factors and the use of mild emollients may be useful in the treatment of genital psoriasis (29, 40, 46, 59).

Systemic therapy is no common practice for isolated genital psoriasis. Nevertheless, such treatment modalities may also be beneficial for genital lesions if prescribed because of severe and extensive psoriasis (32, 33).

Anthralin, tazarotene, ultraviolet (UV)-light and laser therapy should be avoided in the genital area (22, 33, 40).

Therapy-resistant penile and vulvar plaques should always be clinically and histologically re-evaluated to rule out malignancy (26, 30, 42).

CONCLUSION

An extensive, systematic literature search revealed data concerning the epidemiology, clinical presentation and therapy of psoriasis of the genital skin. Remarkably few studies have been published on this topic. Our literature review demonstrates that this hidden skin disease will affect a significant proportion of patients with psoriasis at some time during their disease and is a frequent cause of genital complaints.

It remains to be established whether genital discomfort in psoriatic patients is caused by genital psoriasis or by a comorbidity of the genital skin/mucosa. Examination of the whole skin, including the genital region, is important and should be implemented in daily clinical practice.

Unfortunately, there is often no discrimination between flexural and genital psoriasis in existing publications. Moreover, the current literature often lacks data on the efficacy and safety of investigated treatments for genital skin, and therefore the treatment of genital psoriasis is often empirical. Based on the available literature, the following treatment paradigm is advised for genital psoriasis:

First-line treatment: topical corticosteroid. Second-line treatment: vitamin D preparation or tar-based treatment.

The general advice is to start with weak corticosteroids and, in cases of resistance to treatment, to increase the strength of the corticosteroid preparation. Treatment with potent corticosteroids should be limited to a few weeks in view of their atrophic effects, in particular on genital skin. The addition of topical vitamin D or coal-tar preparations has been suggested to be effective. They can reduce the side-effects of corticosteroids, although irritation may restrict their application. Evidence for the use of immunomodulators on genital skin is scarce. They should be regarded as third-line treatment options.

These recommendations are based on case series and expert opinions only (grade of recommendation: D). Further studies are urgently needed to determine the efficacy and safety of potential treatments and to improve care for patients with genital psoriasis.

ACKNOWLEDGEMENTS

This systematic review was funded by LEO Pharma. LEO Pharma played no role in the design and conduct of the study or in data collection, data management, data analysis, interpretation of the data, manuscript preparation, manuscript review or manuscript approval.

The authors declare no conflicts of interest.

REFERENCES

1. Christophers E. Psoriasis – epidemiology and clinical spectrum. *Clin Exp Dermatol* 2001; 26: 314–320.
2. Myers WA, Gottlieb AB, Mease P. Psoriasis and psoriatic arthritis: clinical features and disease mechanisms. *Clin Dermatol* 2006; 24: 438–447.
3. Raychaudhuri SP, Farber EM. The prevalence of psoriasis in the world. *J Eur Acad Dermatol Venereol* 2001; 15: 16–17.
4. van de Kerkhof PCM. Clinical Features. In: van de Kerkhof PCM, editor. *Textbook of Psoriasis*. Oxford: Blackwell Publishing Ltd, 2003; p. 3–29.
5. Stoof TJ, van der Meijden WI. Psoriasis. In: van der Meijden WI, ter Harsmel WA, editors. *Vulvopathologie*. Assen: Koninklijke Van Gorcum BV, 2007; 137–146.
6. Bunker CB, Neill SM. The genital, perianal and umbilical regions. In: Rook A, Burns T, Breathnach SM, Cox N, Griffiths CE, editors. *Rook's textbook of dermatology*. Oxford: Blackwell Publishing, 2004; 68.1–68.57.
7. Cold CJ, Taylor JR. The prepuce. *BJU Int* 1999; 83 Suppl 1: 34–44.
8. Hellgren L. Psoriasis. A statistical, clinical and laboratory investigation of 255 psoriatics and matched healthy controls. *Acta Derm Venereol* 1964; 44: 191–207.
9. Farber EM, Bright RD, Nall ML. Psoriasis. A questionnaire survey of 2,144 patients. *Arch Dermatol* 1968; 98: 248–259.
10. Farber EM, Nall ML. The natural history of psoriasis in 5,600 patients. *Dermatologica* 1974; 148: 1–18.
11. van de Kerkhof PCM, de Hoop D, de Korte J, Cobelens SA, Kuipers MV. Patient compliance and disease management in the treatment of psoriasis in the Netherlands. *Dermatology* 2000; 200: 292–298.
12. Fouéré S, Adjadj L, Pawin H. How patients experience psoriasis: results from a European survey. *J Eur Acad Dermatol Venereol* 2005; 19 Suppl 3: 2–6.
13. Wang G, Li C, Gao T, Liu Y. Clinical analysis of 48 cases of inverse psoriasis: a hospital-based study. *Eur J Dermatol* 2005; 15: 176–178.
14. MacLean AB, Roberts DT, Reid WMN. Review of 1000 women seen at two specially designated vulval clinics. *Curr Obstet Gynaecol* 1998; 8: 159–162.
15. Fischer G, Spurrett B, Fischer A. The chronically symptomatic vulva: aetiology and management. *Br J Obstet Gynaecol* 1995; 102: 773–779.
16. O'Keefe RJ, Scurry JP, Dennerstein G, Sfameni S, Brennan J. Audit of 114 non-neoplastic vulvar biopsies. *Br J Obstet Gynaecol* 1995; 102: 780–786.
17. Ambros RA, Malfetano JH, Carlson JA, Mihm MC Jr. Non-neoplastic epithelial alterations of the vulva: recognition assessment and comparisons of terminologies used among the various specialties. *Mod Pathol* 1997; 10: 401–408.
18. Singh N, Thappa DM, Jaisankar TJ, Habeebullah S. Pattern of non-venereal dermatoses of female external genitalia in South India. *Dermatol Online J* 2008; 14: 1.
19. Fischer G, Rogers M. Vulvar disease in children: a clinical audit of 130 cases. *Pediatr Dermatol* 2000; 17: 1–6.
20. Kohn FM. Hautveränderungen des Penis. Differenzieren Sie den Lokalbefund von generalisierten Erkrankungen! *MMW Fortschr Med* 2002; 144: 30–35.
21. Lisi P. Differential diagnosis of psoriasis. *Reumatismo* 2007; 59 Suppl 1: 56–60.
22. Mroczkowski TF. Common nonvenereal genital lesions. *Med Clin North Am* 1990; 74: 1507–1528.
23. Pincus SH. Vulvar dermatoses and pruritus vulvae. *Dermatol Clin* 1992; 10: 297–308.
24. Apgar BS, Cox JT. Differentiating normal and abnormal findings of the vulva. *Am Fam Physician* 1996; 53: 1171–1180.
25. Buechner SA. Common skin disorders of the penis. *BJU Int* 2002; 90: 498–506.
26. Goldman BD. Common dermatoses of the male genitalia. Recognition of differences in genital rashes and lesions is essential and attainable. *Postgrad Med* 2000; 108: 89–86.
27. Golombowski G, Anthuber S, Anthuber C. Vulvaerkrankungen im Kindesalter. *Gynakologie* 1998; 31: 558–565.
28. Gross G. Dermatologische Befunde an Mamma und Genitale. *Gynakologie* 2001; 34: 940–948.
29. Nunns D. Pruritus vulvae. *Curr Obs Gynaecol* 2002; 12: 231–234.
30. van Dijk F, Thio HB, Neumann HAM. Non-oncological and non-infectious diseases of the penis (penile lesions). *EAU-EBU Update Series* 2006; 4: 13–19.

31. Rosen T. Update on genital lesions. *JAMA* 2003; 290: 1001–1005.
32. Salim A, Wojnarowska F. Skin diseases affecting the vulva. *Curr Obstet Gynaecol* 2002; 12: 81–89.
33. Trager JDK. What's your diagnosis? Well-demarcated vulvar erythema in two girls. *J Pediatr Adolesc Gynecol* 2005; 18: 43–46.
34. Varghese M, Kindel S. Pigmentary disorders and inflammatory lesions of the external genitalia. *Urol Clin North Am* 1992; 19: 111–121.
35. Welsh B, Howard A, Cook K. Vulval itch. *Aust Fam Physician* 2004; 33: 505–510.
36. Fischer GO. Vulval disease in pre-pubertal girls. *Australas J Dermatol* 2001; 42: 225–234.
37. Morris A, Rogers M, Fischer G, Williams K. Childhood psoriasis: a clinical review of 1262 cases. *Pediatr Dermatol* 2001; 18: 188–198.
38. Fiumara NJ. Psoriasis of the penis: Koebner reaction. Following oral genital exposure. *J Am Vener Dis Assoc* 1976; 3: 59–60.
39. Eichmann AR. Dermatoses of the male genital area. *Dermatology* 2005; 210: 150–156.
40. Farber EM, Nall L. Genital psoriasis. *Cutis* 1992; 50: 263–266.
41. Coldiron BM, Jacobson C. Common penile lesions. *Urol Clin North Am* 1988; 15: 671–685.
42. Weinrauch L, Katz M. Psoriasis vulgaris of labium majus. *Cutis* 1986; 38: 333–334.
43. McKay M. Vulvitis and vulvovaginitis: cutaneous considerations. *Am J Obstet Gynecol* 1991; 165: 1176–1182.
44. Paek SC, Merritt DF, Mallory SB. Pruritus vulvae in prepubertal children. *J Am Acad Dermatol* 2001; 44: 795–802.
45. Welsh BM, Berzins KN, Cook KA, Fairley CK. Management of common vulval conditions. *Med J Aust* 2003; 178: 391–395.
46. Bonnetblanc J-M. Psoriasis. *Ann Dermatol Venereol* 2006; 133: 298–299.
47. Shenberger DW. Curbing the psoriasis cascade: Therapies to minimize flares and frustration. *Postgrad Med* 2005; 117: 9–16.
48. Porter WM, Bunker CB. The dysfunctional foreskin. *Int J STD AIDS* 2001; 12: 216–220.
49. Zamirska A, Reich A, Berny-Moreno J, Salomon J, Szepletowski JC. Vulvar pruritus and burning sensation in women with psoriasis. *Acta Derm Venereol* 2008; 88: 132–135.
50. Albert S, Neill S, Derrick EK, Calonje E. Psoriasis associated with vulval scarring. *Clin Exp Dermatol* 2004; 29: 354–356.
51. Tolman MM, Moschella SL. Pustular psoriasis (Zumbusch). *Arch Dermatol* 1960; 81: 400–404.
52. Quan MB, Ruben BS. Pustular psoriasis limited to the penis. *Int J Dermatol* 1996; 35: 202–204.
53. Singh N, Thappa DM. Circinate pustular psoriasis localized to glans penis mimicking 'circinate balanitis' and responsive to dapson. *Indian J Dermatol Venereol Leprol* 2008; 74: 388–389.
54. Andersen SL, Thomsen K. Psoriasiform napkin dermatitis. *Br J Dermatol* 1971; 84: 316–319.
55. Warin RP, Faulkner KE. Napkin psoriasis. *Br J Dermatol* 1961; 73: 445–447.
56. de Raeye L. Etiology, diagnosis and treatment of diaper dermatitis. [Dutch]. *Tijdschrift voor Geneeskunde* 1991; 47: 1595–1598.
57. Neville EA, Finn OA. Psoriasiform napkin dermatitis – a follow-up study. *Br J Dermatol* 1975; 92: 279–285.
58. Boje Rasmussen H, Hagdrup H, Schmidt H. Psoriasiform napkin dermatitis. *Acta Derm Venereol* 1986; 66: 534–536.
59. Fond L, Michel JL, Gentil-Perret A, Eve B, Montelimard N, Perrot JL, et al. Psoriasis chez l'enfant. *Arch Pediatr* 1999; 6: 669–674.
60. Camilleri MJ, Calobrisi SD. Skin eruptions in the diaper area. *Curr Problems Dermatol* 1999; 11: 214–243.
61. Hogan P. Irritant napkin dermatitis. *Aust Fam Physician* 1999; 28: 385–386.
62. Amichai B. Psoriasis of the glans penis in a child successfully treated with Elidel (pimecrolimus) cream. *J Eur Acad Dermatol Venereol* 2004; 18: 742–743.
63. Jemec GB, Baadsgaard O. Effect of cyclosporine on genital psoriasis and lichen planus. *J Am Acad Dermatol* 1993; 29: 1048–1049.
64. Watanabe M, Tabata N, Tagami H. Explosive diaper pustular psoriasis. *Pediatr Dermatol* 2002; 19: 564–565.
65. Siddha SK, Burden AD. Recognition and treatment of psoriasis in children. *Paediatr Child Health* 2007; 17: 390–394.
66. Quint EH, Smith YR. Vulvar disorders in adolescent patients. *Pediatr Clin North Am* 1999; 46: 593–606.