

Necrobiosis Lipoidica of the Glans Penis

María Luisa Alonso¹, Juan C. Ríos², María José González-Beato² and Pedro Herranz¹

Dermatology Service and ²Pathology Department, "La Paz" University Hospital, Paseo de la Castellana 261, ES-28046 Madrid, Spain. E-mail: mlalonsop@yahoo.es

Accepted July 1, 2010.

Necrobiosis lipoidica (NL) is a distinctive chronic inflammatory disease typified microscopically by dermal and/or subcutaneous palisades of histiocytes surrounding a zone of degenerated collagen. It is therefore a so-called "necrobiotic" granulomatous condition. Though its cause is unknown, two in three patients with NL have diabetes. NL is typically characterised by brownish-yellow ovoid plaques on pretibial skin, with an irregular indurated violaceous contour and a yellow atrophic central area. Thirty percent of cases ulcerate due to minor trauma (1).

CASE REPORT

In June 2007, a 72-year-old man presented with a one-year history of ulceration on the glans penis. He reported that it had appeared after minor trauma involving the zip of his trousers. He had a history of hypertension, gout and kidney stones, and was taking enalapril, colchicine and ibuprofen. He had undergone circumcision at 20 years of age due to phimosis.

Physical examination of the penis revealed an ulcer measuring 2 × 1.5 cm on the right inferior quadrant of the glans penis. The ulcer had an erythematous base, a necrotic centre covered with fibrin, and red borders (Fig. 1A). Suspicion of squamous cell carcinoma prompted us to take a 4-mm skin biopsy.

Microscopy revealed deep, large, palisaded granulomas surrounding extensive zones of degenerated collagen and mucin (Fig. 1B–C). Periodic acid-Schiff and Fite staining (2) did not reveal fungi or mycobacteria. Polarising microscopic analysis of tissue sections did not reveal any foreign material.

Additional testing revealed blood glucose levels, urinalysis and rheumatoid arthritis factor values, and the results of a complete blood count within the normal range. However, cholesterol, gamma-glutamyl transferase and uric acid were abnormal, and a Mantoux test gave a result of 32 mm. Mycobacterial cultures from the skin and urine were negative, as were cultures for other bacteria and fungi. Serology for syphilis, HIV, and hepatitis B and C were negative.

A chest X-ray revealed signs of degeneration of the dorsal vertebrae, and renal and prostatic ultrasonography showed kidney stones in the left renal sinus. Barium X-ray transit studies and intestinal scintigraphy with HMPAO-99mTc leukocytes did not show signs of any intestinal inflammatory disease.

After diagnosis of NL of the glans penis, the patient was treated with 2% fusidic acid cream for one week, leading to progressively spontaneous re-epithelisation. After 3 months, the lesion had healed, leaving a depressed scar (Fig. 1D). After 2 years of follow-up with euglycaemia, the lesion had not reappeared.

DISCUSSION

NL on the glans penis is an uncommon condition – only five cases have been reported to date (3–7) (Table I). The mean age of previous cases was 66 years. In four of these five cases, the lesion was on the glans penis only (extension to the prepuce occurred in the remaining case (6)). NL was also found on the lower limbs in one patient (3).

All but one of the previous cases presented with multiple lesions of 2 to 5 mm in diameter with well-defined borders and yellowish necrotic bases. The remaining patient (5) had a single ulcer of 2 cm in diameter. In three of the five cases, the ulcers were painful (4–6), and the time from the onset of symptoms to diagnosis ranged from 3 months to 15 years (mean 4 years). The disease was recurrent in four of the five cases (3–6), with periods of spontaneous re-epithelisation in some or all lesions (5), which left depressed scars after remission, as in the present case. In the remaining case, the disease was persistent, but the lesion ultimately healed with a depressed scar (7). Only two of the five patients had a history of diabetes (3, 7).

In all cases, the diagnosis was based on microscopic so-called "necrobiotic granulomas". In 3 of the 5 cases, more than one biopsy was necessary (in one case, 4) (7) to confirm the diagnosis. The presence of degenerative collagen fibres surrounded by palisading histiocytes in the deep dermis was the principal histological feature.

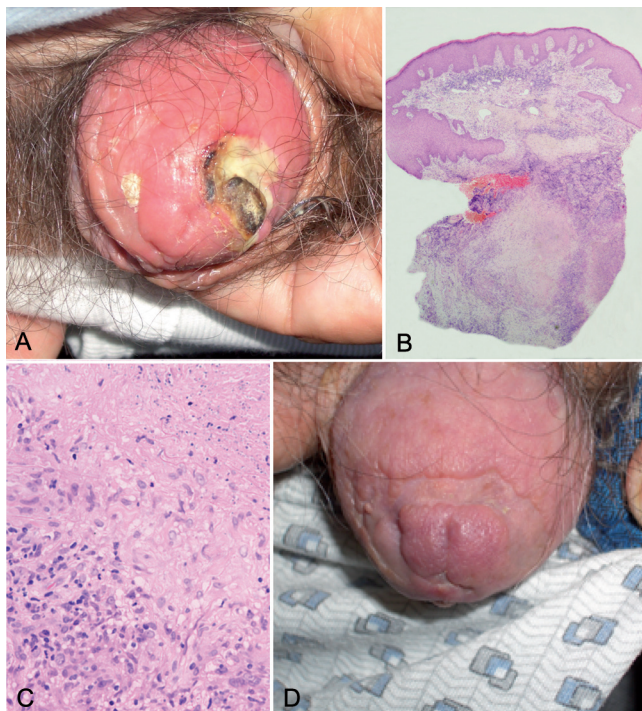


Fig. 1. (A) Ulcer on the glans penis with a necrotic centre and erythematous surrounding skin. (B) Deep, large, palisaded granulomas around extensive zones of degenerated collagen. Haematoxylin-eosin (H&E); ×40. (C) Mucinous degenerative collagen fibres surrounded by histiocytes arranged in palisades. H&E; ×200. (D) Depressed scars after clinical remission.

Table I. *Necrobiosis lipoidica* of the glans penis. Reported cases

| Reference | Age, years | Site | Clinical features | Duration | Diabetes | Mucin staining | Treatment |
|--------------------------|------------|------------|-------------------------|----------|----------|----------------|-------------------------------|
| Lecroq, 1984 (2) | 73 | Limbs | Ulcers | 3 months | + | Not reported | ASA + dipyridamole |
| España, 1994 (3) | 81 | Glans only | Ulcers, depressed scars | 15 years | - | + | Pentoxifylline |
| Velasco-Pastor, 1996 (4) | 57 | Glans only | Ulcers, depressed scars | 2 years | - | - | Pentoxifylline + dipyridamole |
| El Sabed, 1997 (5) | 48 | Prepuce | Ulcers, depressed scars | 4 years | - | + | Circumcision |
| Tokura, 2003 (6) | 65 | Glans only | Ulcer, depressed scars | 6 months | + | + | Pentoxifylline |
| Current case | 72 | Glans only | Ulcer, depressed scars | 1 year | - | + | Spontaneous healing |

ASA: acetylsalicylic acid.

Epithelioid and giant cells were not found in all cases (3, 4, 6). In 3 of the 4 cases in which this feature was mentioned there were deposits of mucin, along with degenerated collagen (4, 6, 7). Plasma cells, which are very common in typical pretibial NL, seem not to be a remarkable feature in cases involving the penis (3–7).

During microscopic diagnosis, various granulomatous conditions, including granuloma annulare (GA), rheumatoid nodules and foreign-body reactions, were considered. The last two were ruled out due to the patient's clinical history and negative results for rheumatoid factor, and no findings in polarising microscopic analyses, respectively.

The condition with which NL of the glans penis is most likely to be confused in microscopic diagnosis is GA. The latter usually has better defined, smaller granulomas separated by normal dermis. The granulomas are typically more superficial with larger amounts of mucin in their centres. However, distinguishing these two diseases can be very difficult (1).

A number of cases of GA located only on the penis have been reported (8–11). All of these cases bore marked clinical differences from the patients who had NL of the glans penis. All were non-diabetic young men (mean age 23 years). The key clinical feature was the presence of firm, asymptomatic nodules on the shaft of the penis that did not ulcerate and did not leave scars. In some cases, spontaneous remission and remission after skin biopsy was reported (8–11).

Histopathology revealed dermal necrobiotic granulomas. Mucin was present in the majority of cases (8, 11), in one case with giant cells (9). In most cases, the granulomas were located in the mid/deep dermis and subcutaneous tissue and were diagnosed as deep or subcutaneous GA (8, 10). These observations suggest that NL of the glans penis and GA have distinct clinical features. Nonetheless, distinguishing them histopathologically is quite difficult (7).

Other diseases that have been described on the glans penis and that should be considered include sarcoidosis and epithelioid sarcoma. The former presents as well-defined granulomas. However, its histiocytes are not arranged in palisades. Epithelioid sarcoma, meanwhile, has a granulomatous appearance due to the growth of epithelioid nodules, and is palisade-like in appearance

due to central zones of necrosis. However, the lesions are ill-defined and the cells atypical (4, 5, 7).

Remission of NL on the glans penis (over the course of 1 to 3 months) has been achieved with oral pentoxifylline (4, 7), pentoxifylline plus dipyridamole (5) and dipyridamole plus acetylsalicylic acid (3), and after circumcision (6). None of these patients exhibited spontaneous remission, as was the case with our patient. Spontaneous remission has been reported in 19% of patients with NL affecting other body sites (1).

In conclusion, our case illustrates a peculiar manifestation of NL of the glans penis, a condition typified by one or more ulcers on the glans penis with erythematous bases that heal with characteristic depressed scars. It affects elderly males with or without diabetes, and should be suspected when necrobiotic granulomas are found in microscopic analyses.

REFERENCES

- Lowit MH, Dover JS. *Necrobiosis lipoidica*. *J Am Acad Dermatol* 1991; 25: 735–748.
- Fite GL, Fite CW. Dye adsorption by mycobacteria. *Int J Lepr* 1965 ;33: 324–341.
- Lecroq C, Thomine E, Bouille MC, Lauret P. *Nécrobiose lipéidique atypique génitale*. *Ann Dermatol Venereol* 1984; 111: 717–718.
- España A, Sánchez-Yus E, Serna MJ, Redondo P, Robledo A. Chronic balanitis with palisadig granuloma: an atypical genital localization of *necrobiosis lipoidica* responsive to pentoxifylline. *Dermatology* 1994; 188: 222–225.
- Velasco-Pastor AM, del Pino M, Martínez-Aparicio A, Aliaga-Boniche A. *Necrobiosis lipoidica* of the glans penis. *Br J Dermatol* 1996; 135: 154–155.
- El Sayed F, Elbadir S, Ferrere J, Marguery MC, Bazex J. Chronic balanitis: an unusual localisation of *necrobiosis lipoidica*. *Genitourin Med* 1997; 73: 579–580.
- Tokura Y, Mizushima Y, Hata M, Takigawa M. *Necrobiosis lipoidica* of the glans penis. *J Am Acad Dermatol* 2003; 49: 921–924.
- Kossard S, Collins AG, Wegman MR. Necrobiotic granulomas localised to the penis: a possible variant of subcutaneous granuloma annulare. *J Cutan Pathol* 1990; 17: 101–114.
- Hillman RJ, Waldron S, Walker MM, Harris JRW. Granuloma annulare of the penis. *Genitourin Med* 1992; 68: 47–49.
- Narouz N, Allan OS, Wade AH. Penile granuloma annulare. *Sex Transm Infect* 1999; 75: 186–187.
- Sidwell R, Green JSA, Agnew K, Francis ND, Roberts NM, Yates VM, et al. Subcutaneous granuloma annulare of the penis in 2 adolescents. *J Pediatr Surg* 2005; 40: 1329–1331.