

Psoriasiform Drug Eruption due to Abatacept

Kohei Kato, Takahiro Satoh*, Aya Nishizawa and Hiroo Yokozeki

Department of Dermatology, Graduate School, Tokyo Medical and Dental University, Tokyo, 1-5-45 Yushima, Bunkyo-ku, Tokyo 113-8519, Japan. *E-mail: tasa-1688.derm@tmd.ac.jp
Accepted October 18, 2010.

Abatacept is a biological agent that modifies immune responses and has been used for the treatment of rheumatoid arthritis (RA). Cutaneous adverse effects due to abatacept are rare. We report here a psoriasiform drug rash in a patient with RA who was being treated with abatacept.

CASE REPORT

A 59-year-old woman presented with a 4-month history of erythematous plaques on her palms and extremities. The patient had a long-term history of using methotrexate (8 mg/week) and oral prednisolone (10 mg/day) as therapy for RA, which had been diagnosed at the age of 37. Laboratory findings were as follows: white blood cell count 10,300 / μ l; C-reactive protein 1.27 mg/dl (normal <0.3 mg/dl); anti-nuclear antibody \times 40; rheumatoid factor 68 IU/ml (normal <20 IU/ml); rheumatoid arthritis particle agglutination \times 320 (normal < \times 40); autoantibody to galactose-deficient IgG 74.9 AU/ml (normal <6 AU/ml); and matrix metalloproteinase-3 195 ng/ml (normal 17.3–59.1 ng/ml). Three years previously, the patient had enrolled in a clinical trial to study the effects of abatacept (750 mg/day, once every 4 weeks). The patient's clinical symptoms of RA were well-controlled with abatacept, and thus oral prednisolone was ceased approximately 4 months before her admission to our department. Physical examination revealed that erythematous plaques of various sizes with scales were present on the patient's extremities, palms and soles (Fig. 1). Microscopically, there was

a parakeratotic hyperkeratosis with irregular acanthosis and a localized thinning of the granular layer (Fig. 2A). Cellular infiltrate comprising mononuclear cells and a few neutrophils was found around perivascular areas in the upper dermis. Inflammatory cells infiltrated into the epidermis and an accumulation of neutrophils in the cornified layer was found (Fig. 2B). The patient had no medical or family history of psoriasis. The eruptions were initially resistant to topical corticosteroids, but gradually improved within a few weeks. Skin patch-testing with abatacept (10% and 20%) was negative. After the remission of skin symptoms, abatacept was re-administered, resulting in the recurrence of skin symptoms within a few days. The patient is being controlled with reduced doses of abatacept (less than 500 mg/day) together with occasional use of topical corticosteroids.

DISCUSSION

Abatacept is a dimeric, soluble, fusion protein consisting of an extracellular binding domain of human cytotoxic T-lymphocyte antigen 4 (CTLA-4) and human IgG. It blocks the binding of CD28 to CD80/CD86, thereby inducing the down-regulation of T-cell

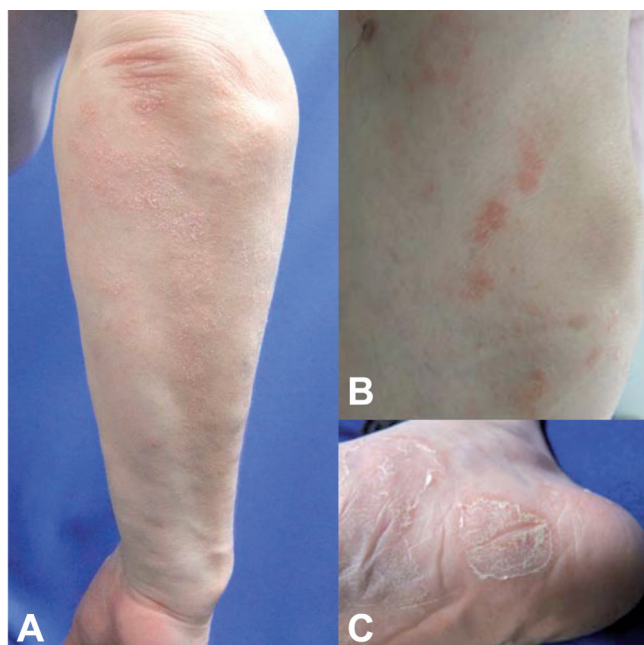

Fig. 1. Clinical features of the skin lesions. (A and B) Erythematous plaques with scales are distributed on the extensor surfaces of the extremities. (C) Keratotic erythematous plaques on the soles.

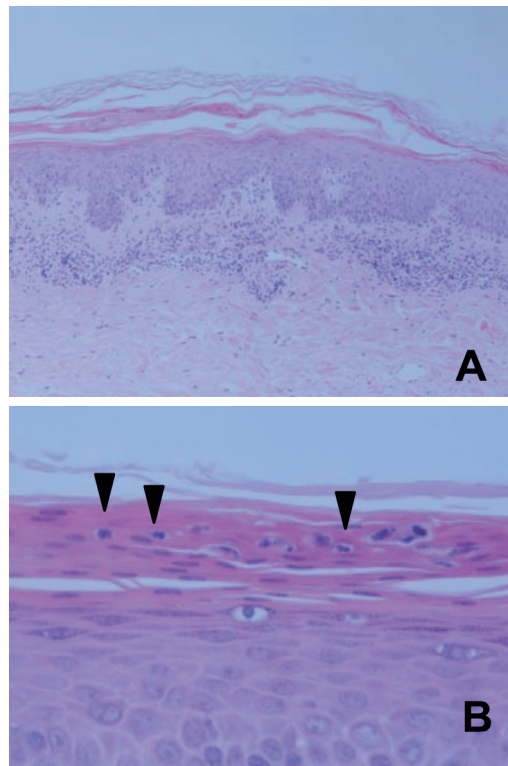


Fig. 2. Histopathological characteristics of the skin lesions. (A) Hyperkeratosis with parakeratosis and moderate acanthosis. (Original magnification \times 100). (B) Accumulation of neutrophils in the stratum corneum (arrowheads). (Original magnification \times 400).

proliferation (1). This agent has potential for treating patients with RA. It is likely that the skin eruptions that occurred in our patient were caused by abatacept, as the re-administration of abatacept resulted in the recurrence of skin lesions. A 3-year latency period is longer than that of eruptions caused by most other drugs. Possibly oral prednisolone had a masking effect on the development of the skin lesions until it was interrupted 4 months before the patient was seen by us.

Histopathological changes in the present case appeared to share some morphological similarities with psoriatic reactions by way of parakeratotic acanthosis, which was accompanied by thinning of the granular layer and neutrophilic accumulation in the stratum corneum. Psoriatic skin lesions evoked by abatacept in a case of RA have also been reported in another study (2). Psoriasiform and/or pustular eruptions are well-known cutaneous adverse effects of anti-tumour necrosis factor alpha (TNF- α) antagonists (3–5). This is explained by cytokine imbalance with an increase in interferon- α (4, 5). In a further report, patient with a juvenile RA receiving abatacept treatment developed erythema elevatum diutinum, a disease characterized by extensive neutrophil infiltration in the dermis. However, in that study it remained to be determined whether abatacept actually contributed to the skin lesions (6). Considering the infiltration of neutrophils in the skin lesions of our patient, anti-TNF- α antagonists and abatacept may share common modulatory effects on the immune system, hence leading to the activation of neutrophils. Alternatively, abatacept may interfere

with CTLA-4 signals in regulatory T cells (7), which results in the impaired suppressive functions of those cells and in the exacerbation of Th17 immunity. Further research is needed in order to elucidate the mechanisms responsible for skin eruptions due to abatacept.

The authors declare no conflicts of interest.

REFERENCES

1. Vital EM, Emery P. Abatacept in the treatment of rheumatoid arthritis. *Ther Clin Risk Manag* 2006; 2: 365–375.
2. Brunasso AM, Laimer M, Massone C. Paradoxical reactions to targeted biological treatments: A way to treat and trigger? *Acta Derm Venereol* 2010; 90: 183–185.
3. Kuhara T, Watanabe D, Iwahori Y, Tamada Y, Yamamura M, Matsumoto Y. Psoriasiform and pustular eruption induced by etanercept and infliximab. *Eur J Dermatol* 2009; 19: 388–389.
4. Seneschal J, Milpied B, Vergier B, Lepreux S, Schaefferbeke T, Taieb A. Cytokine imbalance with increased production of interferon-alpha in psoriasiform eruptions associated with antitumour necrosis factor-alpha treatments. *Br J Dermatol* 2009; 161: 1081–1088.
5. Collamer AN, Guerrero KT, Henning JS, Battafarano DF. Psoriatic skin lesions induced by tumor necrosis factor antagonist therapy: a literature review and potential mechanisms of action. *Arthritis Rheum* 2008; 59: 996–1001.
6. Golmia A, Grinblat B, Finger E, Klieman C, Assir F, Scheinberg M. The development of erythema elevatum diutinum in a patient with juvenile idiopathic arthritis under treatment with abatacept. *Clin Rheumatol* 2008; 27: 105–106.
7. Jain N, Nguyen H, Chambers C, Kang J. Dual function of CTLA-4 in regulatory T cells and conventional T cells to prevent multiorgan autoimmunity. *Proc Natl Acad Sci USA* 2010; 107: 1524–1528.