

## Recurrence of Hydroxyurea-induced Leg Ulcer After Discontinuation of Treatment

Kazuhiro Kikuchi<sup>1</sup>, Ken Arita<sup>1</sup>, Yasuki Tateishi<sup>1</sup>, Masahiro Onozawa<sup>2</sup>, Masashi Akiyama<sup>1</sup> and Hiroshi Shimizu<sup>1</sup>

Departments of <sup>1</sup>Dermatology and <sup>2</sup>Hematology, Hokkaido University Graduate School of Medicine, North 15 West 7, Kita-ku, Sapporo 060-8638, Japan.

E-mail: kikku@med.hokudai.ac.jp

Accepted November 1, 2010.

Hydroxyurea (HU) is a hydroxylated derivative of urea that has been recognized since 1960 as effective against cancer (1). It is an inhibitor of cellular DNA synthesis, and it promotes cell death in the S phase of the cell cycle through inhibition of the enzyme ribonucleotide reductase (2). The most common indications for HU therapy are chronic myeloid leukaemia and other myeloproliferative disorders (3, 4) such as essential thrombocythemia (5) and polycythemia vera (PV) (6). Cutaneous side-effects, such as alopecia, diffuse hyperpigmentation, scaling, lichen planus-like lesions, poikiloderma, atrophy of the skin and subcutaneous tissues, and nail changes, can occur during the treatment with HU (7–9). The occurrence of painful leg ulcers represents another rare and incompletely characterized complication that has been described in patients with myeloproliferative diseases receiving high-dose long-term HU treatment (10). While the mode of action of HU on bone marrow elements is well established, its effects on actively proliferating epithelial cells remain less described (11). Poor response to traditional local and systemic therapy is a typical feature of HU-induced leg ulcers, and discontinuation of the drug is often required to achieve complete wound healing (6, 8). Cessation of the drug usually improves the skin ulcer; although, in some cases, the ulcer remains and additional therapies, such as skin grafting, are needed (12). We report here the first case of a leg ulcer that recurred even after discontinuation of HU treatment.

### CASE REPORT

The patient was an 82-year-old Japanese male who had been diagnosed with PV 9 years before and had been treated only with phlebotomy and an anti-platelet agent for several years. Due to splenomegaly and elevated blood cell counts, HU therapy was started 3 years ago at a dosage of 1 g daily for a month, followed by 1.0 or 1.5 g daily for 28 months. A good clinical response was achieved. However, the patient developed painful ulcers on the left second toe after two years of HU treatment.

He visited our outpatient clinic and was diagnosed with an HU-induced skin ulcer. HU was discontinued, topical application of sulfadiazine silver was performed, an oral antibiotic (cefдинir) was administered, and the ulcer epithelialized. However, a new ulcer appeared on the left lateral malleolar area 46 days after cessation of HU and gradually enlarged in size. The patient was admitted to our hospital for treatment of the ulcer.

Examination revealed a 48 × 56 mm ulcer with yellow necrotic tissue and marginal erythematous oedema (Fig. 1). Laboratory examination revealed a white blood cell count of  $11.6 \times 10^3/\mu\text{l}$ , a platelet count of  $64.2 \times 10^4/\text{l}$ , and a red blood cell count of  $5.07 \times 10^6/\mu\text{l}$ . Anti-nuclear antibody, anti-neutrophilic cytoplasmic antibodies, anti-cardiolipin antibody, and cryoglobulin were negative. A skin biopsy taken from the margin of the ulcer demonstrated leukocytoclastic vasculitis in the upper dermis (Fig. 2). A wound-healing strategy of surgical debridement, intravenous prostaglandin E1 administration, and topical application of beta-fibroblast growth factor, sulfadiazine silver and alprostadil alfadex was started, and the ulcer began to epithelialize. After 4 months, re-epithelialization was complete. The PV was treated with busulfan, achieving a good clinical response.

### DISCUSSION

HU is usually well tolerated and has low toxicity (1). However, cutaneous adverse effects such as diffuse hyperpigmentation, brown discoloration of the nails, acral erythema, photosensitization, fixed drug eruption, alopecia, and oral ulceration have been reported (7–9). Stahl & Silber (10) first reported HU-induced skin ulcers in 1985. Montefusco et al. (11) reported

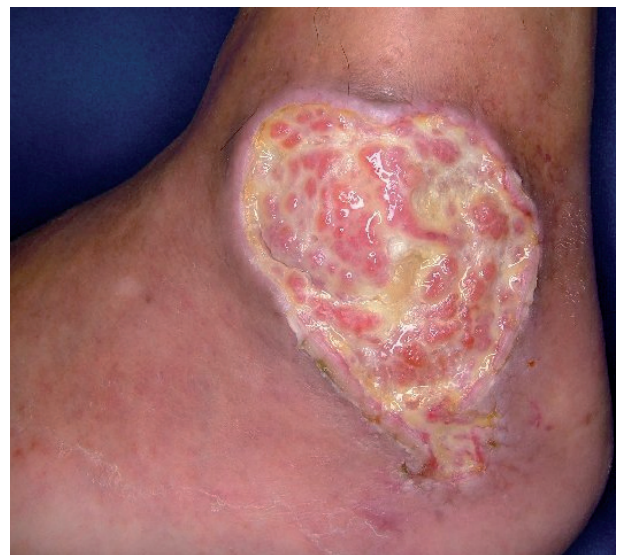

Fig. 1. Left foot with an ulcer on the lateral malleolar area after two months free of hydroxyurea administration. The ulcer was covered with yellow necrotic tissue and surrounded by oedematous erythema.

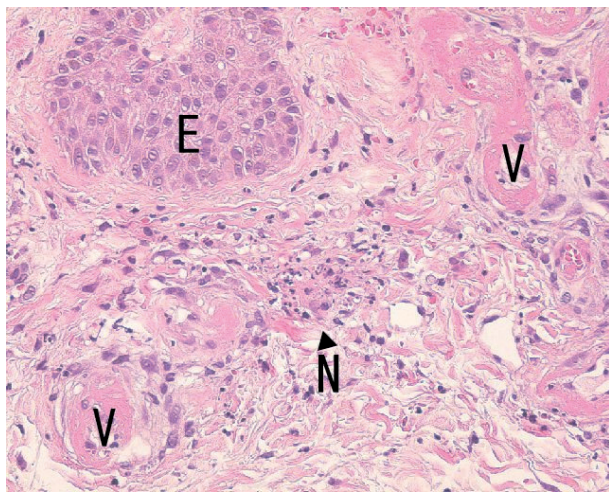


Fig. 2. Histology of erythema on the margin of the ulcer (haematoxylin-eosin staining). Fibrin deposition on the vascular wall and nucleic debris were evident around small vessels ( $\times 100$ ). (E: epidermis; V: blood vessels; N: neutrophilic nuclear debris).

that, among 200 chronic myeloid leukaemia patients treated with HU, 17 (8.5%) developed leg ulcers. However, they achieved complete resolution or significant improvement after discontinuation of HU therapy (11). HU-induced leg ulcer and complete resolution within several months after drug discontinuation has also been reported in other myeloproliferative disorder, such as PV (6) and essential thrombocythemia (5). In those cases, as in ours, most of the patients had been treated with  $> 1$  g of HU per day for at least one year (8). In the present case, the patient was treated with  $> 1$  g of HU per day for 28 months. The ulcer occurred on his lateral malleolus, which histologically showed leukocytoclastic vasculitis. These features are consistent with previous reports of HU-induced leg ulcer.

From previous reports, the pathogenesis of HU-induced ulceration remains unclear and it may be multifactorial. It has been postulated that ulcers may be the result of: (i) interruption of microcirculation due to leukocytoclastic vasculitis or arterial microthrombi related to platelet dysregulation (13, 14); (ii) cumulative toxicity in the basal layer of the epidermis through inhibition of DNA synthesis (8); and (iii) repeated mechanical injury in areas subject to trauma: a perimalleolar area for instance (15).

In the case described here, a new ulcer developed even after cessation of HU administration. As for the pathogenic mechanism of recurrence, (i) interruption of microcirculation could result from hyperviscosity due to the elevated platelet count (as high as  $100 \times 10^4/l$  in one measurement) (13, 14), although no thrombi were observed histologically in the capillaries or small vessels. (ii) The direct cytotoxic effect of HU (8) may

continue even after the withdrawal of the drug, and it may inhibit the repair of (iii) small injuries in the perimalleolar area: the one of the area susceptible to physical trauma (15). These assumptions can be made from the pathogenesis of HU-induced ulcer reported previously (8, 13–15).

To our knowledge, this is the first report of recurrence of HU-related leg ulcer after the discontinuation of medication. The case suggests that it is important to pay careful attention to recurrence even after cessation of HU therapy. Precise, early treatment for microtraumas and small ulcers should be administered to patients with a long history of HU medication.

## REFERENCES

- Boyd AS, Neldner KH. Hydroxyurea therapy. *J Am Acad Dermatol* 1991; 25: 518–524.
- Yarbro JW. Mechanism of action of hydroxyurea. *Semin Oncol* 1992; 19: 1–10.
- Goldman JM. Therapeutic strategies for chronic myeloid leukemia in the chronic (stable) phase. *Semin Hematol* 2003; 40: 10–17.
- Rice L, Baker KR. Current management of the myeloproliferative disorders: a case-based review. *Arch Pathol Lab Med* 2006; 130: 1151–1156.
- Demirçay Z, Cömert A, Adigüzel C. Leg ulcers and hydroxyurea: report of three cases with essential thrombocythemia. *Int J Dermatol* 2002; 41: 872–874.
- Bader U, Banyai M, Böni R, Burg G, Hafner J. Leg ulcers in patients with myeloproliferative disorders: disease- or treatment-related? *Dermatology* 2000; 200: 45–48.
- Najejan Y, Rain JD. Treatment of polycythemia vera: the use of hydroxyurea and pipobroman in 292 patients under the age of 65 years. *Blood* 1997; 90: 3370–3377.
- Weinlich G, Schuler G, Greil R, Kofler H, Fritsch P. Leg ulcers associated with long-term hydroxyurea therapy. *J Am Acad Dermatol* 1998; 39: 372–374.
- Daoud MS, Gibson LE, Pittelkow MR. Hydroxyurea dermatopathy: a unique lichenoid eruption complicating long-term therapy with hydroxyurea. *J Am Acad Dermatol* 1997; 36: 178–182.
- Stahl RL, Silber R. Vasculitic leg ulcers in chronic myelogenous leukemia. *Am J Hematol* 1985; 78: 869–872.
- Montefusco E, Alimena G, Gastaldi R, Carlesimo OA, Valesini G, Mandelli F. Unusual dermatologic toxicity of long-term therapy with hydroxyurea in chronic myelogenous leukaemia. *Tumori* 1986; 72: 317–321.
- Kato N, Kimura K, Yasukawa K, Yoshida K. Hydroxyurea-related leg ulcers in a patient with chronic myelogenous leukemia: a case report and review of the literature. *J Dermatol* 1999; 26: 56–62.
- Sirieix ME, Debure C, Baudot N, Dubertret L, Roux ME, Morel P, et al. Leg ulcers and hydroxyurea: forty-one cases. *Arch Dermatol* 1999; 135: 818–820.
- Chaine B, Neonato MG, Girot R, Aractingi S. Cutaneous adverse reactions to hydroxyurea in patients with sickle cell disease. *Arch Dermatol* 2001; 137: 467–470.
- Saravu K, Velappan P, Lakshmi N, Shastry BA, Thomas J. Hydroxyurea induced perimalleolar ulcers. *J Korean Med Sci* 2006; 21: 177–179.