

## Difficulty to Identify Sentinel Lymph Nodes with Computed Tomography-lymphography in Patients with Cutaneous Melanoma

Yuichi Yoshida<sup>1</sup>, Koji Adachi<sup>1</sup>, Keiko Nakashima<sup>1</sup>, Takefumi Yamane<sup>2</sup> and Osamu Yamamoto<sup>1</sup>

<sup>1</sup>Division of Dermatology, Department of Medicine of Sensory and Motor Organs, and <sup>2</sup>Division of Clinical Radiology, Faculty of Medicine, Tottori University, 86 Nishi-cho, Yonago-shi, Tottori 683-8503, Japan. E-mail: yxy@grape.med.tottori-u.ac.jp  
Accepted November 1, 2010.

Since the report on the sentinel lymph node (SLN) concept by Morton et al. (1), SLN biopsy has become a standard method for assessing occult metastases in regional lymph nodes in various cancers, including cutaneous malignant melanoma, head and neck squamous cell carcinoma, and breast cancer (1–3). The combined use of vital blue dye and radioactive tracer with a hand-held gamma probe in addition to preoperative lymphoscintigraphy is a reliable method to search for SLNs (4). The single-photon-emission computed tomography/computed tomography (SPECT/CT) system is also useful for determining the anatomical location of SLNs, though the specialized equipment is expensive (5, 6). Another method using CT-lymphography with a non-ionic contrast medium for identification of SLNs has been reported to be useful in many institutions in Japan that do not have the necessary facilities for radioisotopes (7–9). The aim of this study was therefore to evaluate the efficacy of CT-lymphography compared with that of the ordinary method for identification of SLNs in patients with cutaneous melanoma.

### PATIENTS AND METHODS

Eight patients (4 men and 4 women; age range 56–94 years; mean age 73.5 years) with cutaneous melanoma were included in this study at the Division of Dermatology, Tottori University Hospital, from March 2009 to April 2010 after informed consent had been obtained. The diagnosis was based on histopathological examination. The study protocol was approved by the ethics committee of Tottori University.

CT-lymphography was performed using a multi-detector row helical CT scanner (Aquilion 64, Toshiba Medical Systems, Tokyo, Japan). A non-ionic contrast medium, iopamidol (Iopamiron 300, Bayer Schering Pharma, Osaka, Japan), was injected both intradermally and subcutaneously using a tuberculin syringe (27 gauge) around the primary lesion (1–5 ml per site), as previously reported (7–9). The injection site was then massaged gently for 5 min. CT images from the primary lesion to regional lymph nodes were obtained before and 10 min after injection. When an SLN was identified, a 3-dimensional CT image was reconstructed. In addition, preoperative lymphoscintigraphy with <sup>99m</sup>Tc-labelled phytate (Techne Phytate Kit, Fujifilm RI Pharma, Tokyo, Japan) was performed 4 days later in 7 patients (1 ml of 50–100 mBq per site). At the time of surgery (next day), an ordinary combination method of dye (2% patent blue violet, 0.5–1 ml for sites) and radioactive tracer with a hand-held gamma probe for SLN mapping was used to compare the efficacy of identification by the two methods (the dye method only was used in one patient (patient 3)).

Table I. Characteristics of patients

No.	Age, years/ sex	Tumour location	SLN location	Iopamidol CT ml	Dye+ RI	SLNs <i>n</i>	Meta- stasis	
1	82/F	Dorsum of hand	Axilla	–	2	+	2	–
			Cubitus	–		+	1	–
2	94/F	Arm	Axilla	–	2	+	2	–
3	60/M	Thigh	Groin	+	4	+	1	+
4	56/M	Thigh	Groin	–	3.5	+	1	–
5	85/M	3 <sup>rd</sup> finger	Axilla	–	1	+	3	–
6	60/M	Thigh	Groin	+	5	+	1	–
7	73/F	Thumb	Axilla	–	1	+	1	–
8	78/F	Heel	Groin	–	4	+	2	–
			Popliteus	–		+	1	–

F: female; M: male; SLN: sentinel lymph node; CT: computed tomography lymphography method; Dye+RI: dye+radio isotope method; +: detected; –: not detected.

### RESULTS

The characteristics of the patients are shown in Table I. Primary tumours were located on various areas of the extremities. The tumour thickness was 0.7–5 mm. SLNs were detected in 2 of the 8 patients (patients 3 and 6) by CT-lymphography (Fig. 1). The primary tumour was located on the thigh in both cases. Lymph flow was recognized only in patient 3.

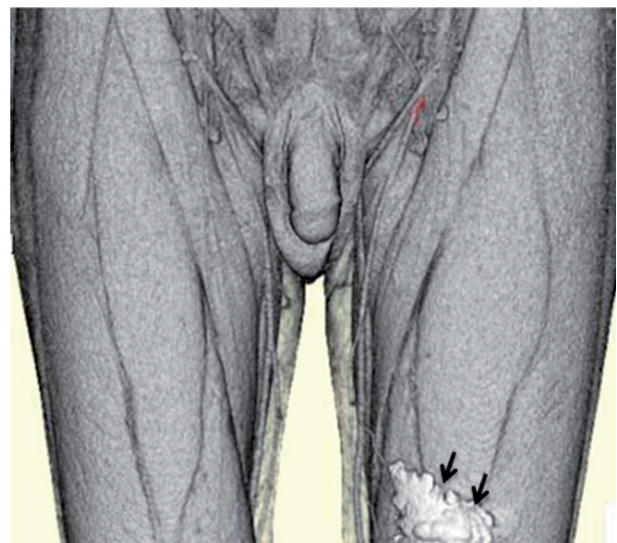


Fig. 1. Sentinel lymph node (red colour; since the colour was faint it was converted into red) detected by 3-dimensional computed tomography image with iopamidol in patient 6 (arrows: the remains of the contrast medium injected at the site of the tumour).

Using the ordinary combination method of dye and radioactive tracer with a hand-held gamma probe during surgery, SLNs (mean 1.9 nodes) were identified in all patients. Regional lymph nodes were located in the axilla or groin, although interval nodes (cubitus and popliteus) were also detected in two patients (patients 1 and 8). Tumour cells were histopathologically detected only in an SLN of patient 3.

## DISCUSSION

Immediate lymphadenectomy according to the results of SLN biopsy has been shown to improve overall survival (10). The SLN is usually identified using a combination of dye and radioactive tracer. However, there are many institutions that are not equipped with facilities for radioisotopes. Therefore, another method using CT-lymphography for SLN mapping has been attempted in patients with breast cancer (7–9). Remarkably, Takahashi et al. (9) reported that the identification rate was 212 (96%) in 221 cases, in which the CT-lymphography method was used, which was better than the rate of 92% using a dye method.

In our study, SLNs were identified in all patients by an ordinary combination method. However, SLNs were identified in only 2 (25%) of the 8 patients by CT-lymphography, and signals from iopamidol in SLNs were relatively weak. In addition, a lymphatic pathway was recognized in only one patient. In some patients, CT images were repeated 30–60 min later, but SLNs were not detected (not shown). Although 1–5 ml iopamidol was injected around the primary tumour of breast cancer (7–9), it was difficult to inject a large volume of iopamidol into the hand or foot of melanoma patients. There was a discrepancy in identification rate by CT-lymphography between our results and those of previous studies. It is unlikely that nodal status affected the identification of SLNs in this study because an SLN was also detected in patient 3 (SLN being positive for tumour cells). The primary tumour was located on the thigh in both cases with successful identification of SLNs. We speculate that an increased distance from the primary tumour to regional SLNs is related to a poorer detection by CT-lymphography. In addition, the number and size of lymphatic vessels at the site of injection could influence SLN mapping by the CT-lymphography method. It is difficult to identify an interval node, such as a cubital or popliteal lymph node, by CT-lymphography alone.

Our results indicate that the application of CT-lymphography instead of an ordinary method to map SLNs in cutaneous melanoma should be used with care. The ordinary combination method of dye and radioactive tracer with a hand-held gamma probe is the gold standard for SLN biopsy in patients with cutaneous melanoma.

## ACKNOWLEDGEMENT

This work was supported in part by Tottori University Faculty of Medicine Research grant for 2009.

## REFERENCES

1. Morton DL, Wen DR, Wong JH, Economou JS, Cagle LA, Storm FK, et al. Technical details of intraoperative lymphatic mapping for early stage melanoma. *Arch Surg* 1992; 127: 392–399.
2. Shoaib T, Soutar DS, Prosser JE, Dunaway DJ, Gray HW, McCurrach GM, et al. A suggested method for sentinel node biopsy in squamous cell carcinoma of the head and neck. *Head Neck* 1999; 21: 728–733.
3. Cody HS 3rd, Borgen PI. State-of-the-art approaches to sentinel node biopsy for breast cancer: study design, patient selection, technique, and quality control at Memorial Sloan-Kettering Cancer Center. *Surg Oncol* 1999; 8: 85–91.
4. Bagaria SP, Faries MB, Morton DL. Sentinel node biopsy in melanoma: technical considerations of the procedure as performed at the John Wayne Cancer Institute. *J Surg Oncol* 2010; 101: 669–676.
5. Even-Sapir E, Lerman H, Lievshitz G, Khafif A, Fliss DM, Schwartz A, et al. Lymphoscintigraphy for sentinel node mapping using a hybrid SPECT/CT system. *J Nucl Med* 2003; 44: 1413–1420.
6. Ishihara T, Kaguchi A, Matsushita S, Shiraishi S, Tomiguchi S, Yamashita Y, et al. Management of sentinel lymph nodes in malignant skin tumors using lymphoscintigraphy and the single-photon-emission computed tomography/computed tomography combined system. *Int J Clin Oncol* 2006; 11: 214–220.
7. Suga K, Yuan Y, Okada M, Matsunaga N, Tangoku A, Yamamoto S, Oka M. Breast sentinel lymph node mapping at CT lymphography with iopamidol: preliminary experience. *Radiology* 2004; 230: 543–552.
8. Tangoku A, Yamamoto S, Suga K, Ueda K, Nagashima Y, Hida M, et al. Sentinel lymph node biopsy using computed tomography-lymphography in patients with breast cancer. *Surgery* 2004; 135: 258–265.
9. Takahashi M, Sasa M, Hirose C, Hisaoka S, Taki M, Hirose T, Bando Y. Clinical efficacy and problems with CT lymphography in identifying the sentinel node in breast cancer. *World J Surg Oncol* 2008; 6: 57.
10. Morton DL, Thompson JF, Cochran AJ, Mozzillo N, Elashoff R, Essner R, et al. Sentinel-node biopsy or nodal observation in melanoma. *N Engl J Med* 2006; 355: 1307–1317.