

Oral Mucous Membrane Pemphigoid: Complete Response to Topical Tacrolimus

Haur Yueh Lee, Claudia Blazek, Helmut Beltraminelli and Luca Borradori*

Department of Dermatology, Inselspital, University of Bern, CH-3010 Bern, Switzerland. *E-mail: luca.borradori@insel.ch

Accepted March 4, 2011.

Mucous membrane pemphigoid includes a heterogeneous group of blistering diseases, which have in common the involvement of the mucosae, a chronic course and a scarring tendency (1–3). The oral mucosa, conjunctiva, and, less frequently, the nose, oesophagus, larynx and genitals may be affected (1–3). Erosions and scarring of the mucosae might result in significant morbidity, and treatment is usually challenging. We report here a case of oral mucous membrane pemphigoid that was treated successfully with oral rinses of topical tacrolimus.

CASE REPORT

An 84-year-old man was referred for evaluation of recurrent painful oral ulcers of 6 months' duration. His past medical history was significant for coronary heart disease, stroke, paroxysmal atrial fibrillation and chronic renal impairment. Clinical examination showed angulated erosions and white plaques over the buccal mucosa with atrophic scars. The rest of the oral cavity was uninvolved, and physical examination did not reveal any other muco-cutaneous lesions (Fig. 1A). A biopsy specimen obtained from the oral mucosa showed sub-epithelial clefting with dermal oedema. Direct immunofluorescence microscopy studies demonstrated linear deposits of IgG and C3 along the epithelial basement membrane. Indirect immunofluorescence microscopy disclosed circulating autoantibodies binding to the epidermal side of NaCl-separated normal human skin, whereas testing by enzyme-linked immunoassay (ELISA)-BP 180 and ELISA-BP 230 were both negative. A diagnosis of mucous membrane pemphigoid was made. Based on the limited extent of the condition, the patient's age and co-morbidities, he was treated with an oral suspension of tacrolimus 0.03% (tacrolimus; Prograf® tablets reconstituted at a concentration of 0.03% in an aqueous solution of sodium carboxymethylcellulose 1%, methyl parahydroxybenzoate 0.07%, propylparahydroxybenzoate 0.03%, water 98.9%), applied twice daily as a 5-min rinse. After 2 months, there was complete resolution of the erosions of the whitish papules. After reduction of the oral rinses to once daily, then once every second day the disease remained quiescent for the following 2 months (Fig. 1B).

DISCUSSION

Mucous membrane pemphigoid (MMP) is a rare autoimmune subepidermal blistering disorder characterized by a predominant involvement of the external mucosal surfaces. It is associated with IgG and/or IgA autoantibodies of different specificity, that recognizes BP180 and BP230, (3) the 97/120 kDa LABD antigen, laminin-332 (Laminin-5) and laminin-311 (Laminin-6), (4, 5) type VII collagen (6), or the β 4 integrin subunit (7). Within MMP, there exists a significant variation in clinical presentations. Variants include predominant ocular disease, predominant oral involvement (oral pemphigoid), as well as generalized mucocutaneous involvement (3). MMP can be difficult and often disappointing to treat. Therapeutic regimens in MMP are based primarily on clinical experience. Local therapy may be sufficient to control the disease, but systemic medications are indicated for severe ocular, laryngeal or oesophageal involvement, as well as for oral or cutaneous disease unresponsive to topical therapy. While potent topical corticosteroids are usually tried and are sometimes sufficient to control the disease, cases can be treatment-resistant or develop complications such as oral candidiasis or mucosal atrophy (8). There have been only a few reports on the use of tacrolimus in MMP, with only one previous case with localized oral involvement. Ocular membrane pemphigoid has been successfully treated with tacrolimus 1% in combination with topical dexamethasone/tobramycin (9), whilst in a case of MMP with genital involvement, topical tacrolimus ointment 0.1% in combination with a systemic steroid was effective in a patient in whom treatment with a combination of systemic steroids and immunosuppressive agents (mycophenolate mofetil, azathioprine) failed (10). Topical tacrolimus ointment 0.1% applied on affected

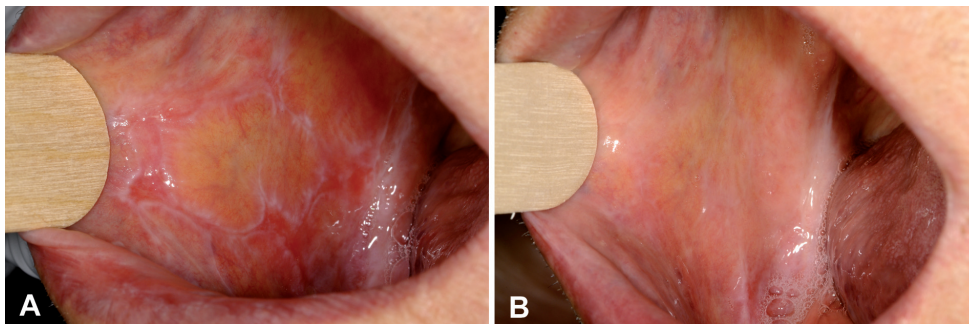


Fig. 1. (A) Erosions with whitish plaques and atrophic scars over the right buccal mucosa. (B) Resolution of erosions with no new lesions on follow-up.

areas twice daily with subsequent rinsing has previously been found to be effective in the treatment of oral MMP (8). In line with this last observation, our case further underscores the usefulness of topical tacrolimus, which may result in full remission of the disease within 2–3 months of treatment. Possible mechanisms of action of tacrolimus include the suppression of the activation and differentiation of T lymphocytes, eosinophils and neutrophils via the inhibition of nuclear gene transcription of interleukin (IL)-2 and other several pro-inflammatory cytokines, such as IL-4 and IL-5 (8).

In the evaluation and treatment of MMP, the extent of disease, co-morbidities and the age of the patient are important considerations. Hence, topical tacrolimus can be a safe, and effective treatment in patients with limited disease, obviating the side-effects and complications associated with systemic immunosuppression, particularly in elderly patients.

REFERENCES

1. Mutasim DF, Pelc NJ, Anhalt GJ. Cicatricial pemphigoid. *Dermatol Clin* 1993; 11: 499–510.
2. Chan LS, Yancey KB, Hammerberg C, Soong HK, Regezi JA, Johnson K, et al. Immune-mediated subepithelial blistering diseases of mucous membranes. Pure ocular cicatricial pemphigoid is a unique clinical and immunopathological entity distinct form of bullous pemphigoid and other subsets identified by antigenic specificity of autoantibodies. *Arch Dermatol* 1993; 129: 448–455.
3. Borradori L, Bernard P. Pemphigoid group (bullous pemphigoid, cicatricial pemphigoid, epidermolysis bullosa acquisita). In: *Dermatology*, Bologna JL, Jorizzo JL, Rapini RP, editors. London: Elsevier Science, 2006: p. 431–445.
4. Domloge-Hultsch N, Gammon WR, Briggaman RA, Gil SG, Carter WG, Yancey KB. Epiligrin, the major human keratinocyte integrin ligand, is a target in both an acquired autoimmune and an inherited subepidermal blistering skin disease. *J Clin Invest* 1992; 90: 1628–1633.
5. Chan LS, Majmudar AA, Tran HH, Meier F, Schaumburg-Lever G, Chen M, et al. Laminin-6 and Laminin-5 are recognized by autoantibodies in a subset of cicatricial pemphigoid. *J Invest Dermatol* 1997; 108: 848–853.
6. Luke MC, Darling TN, Hsu R, Summers RM, Smith JA, Solomon BI, et al. Mucosal morbidity in patients with epidermolysis bullosa acquisita. *Arch Dermatol* 1999; 135: 954–959.
7. Tyagi S, Bhol K, Natarajan K, Livir-Rallatos C, Foster CS, Ahmed AR. Ocular cicatricial pemphigoid antigen: partial sequence and biochemical characterization. *Proc Natl Acad Sci USA* 1996; 93: 14714–14719.
8. Assmann T, Becker J, Ruzicka T, Megahed M. Topical tacrolimus for oral cicatricial pemphigoid. *Clin Exp Dermatol* 2004; 29: 674–676.
9. Hall VC, Liesegang TJ, Kostick DA, Lookingbill DP. Ocular mucous membrane pemphigoid and ocular pemphigus vulgaris treated topically with tacrolimus ointment. *Arch Dermatol* 2003; 139: 1083–1084.
10. Gunther C, Wozel G, Meurer M, Pfeifer C. Topical tacrolimus treatment for cicatricial pemphigoid. *J Am Acad Dermatol* 2004; 50: 325–326.