

A Case of Epidermolysis Bullosa Acquisita Associated with Laryngeal Stenosis

Yukiko Kuniwa¹, Atsuko Ashida¹, Atsuko Ohashi¹, Ryosuke Kitoh², Shunpei Fukuda³, Takashi Hashimoto³ and Ryuhei Okuyama¹

Departments of ¹Dermatology and ²Otolaryngology, Shinshu University School of Medicine, 3-1-1 Asahi, Matsumoto, Nagano, 390-8621, and ³Department of Dermatology, Kurume University School of Medicine, and Kurume University Institute of Cutaneous Cell Biology, Kurume, Japan. E-mail: ykuniwa@shinshu-u.ac.jp

Accepted March 18, 2011.

Epidermolysis bullosa acquisita (EBA) is an acquired inflammatory subepidermal blistering disease characterized by immunoglobulin G (IgG) auto-antibodies to type VII collagen in the dermal–epidermal junction of the skin (1). Patients usually present with skin fragility and tense bullae over areas of trauma. Occasionally, the clinical features of EBA are indistinguishable from those of mucous membrane pemphigoid (MMP) (formerly, cicatricial pemphigoid), when the main symptoms are seen on mucosae. However, cases with laryngeal lesions are uncommon. We report here a case of EBA with laryngeal stenosis occurring in a 73-year-old woman.

CASE REPORT

A 73-year-old Japanese woman noticed aphtha and dry mouth in May 2009. The primary physician suspected herpes simplex. Several months later, she noticed tense blisters on her waist. Skin biopsy showed subepidermal bullae with inflammatory cell infiltration including eosinophils in the upper dermis. Direct immunofluorescence analysis demonstrated deposition of C3 on the epidermal basement membrane. Serum anti-bullous pemphigoid antigen 180 (BP180) antibody was positive. A diagnosis of bullous pemphigoid was made. From February 2010, she was treated with oral prednisolone, 30 mg/day, which improved the blisters with erosions on her waist, but not the oral mucosal erosions.

She was referred to our hospital. Physical examination showed multiple erosions on the tongue, palate and buccal mucosa,

together with an erosion 8 cm in diameter on the left waist (Fig. 1a, b). Blood examination demonstrated hypoproteinaemia (5.8 g/dl; normal 6.8–8.3 g/dl), hypokalaemia (3.2 mEq/l; normal 3.4–4.5 mEq/l), and anaemia (red blood cell count 3.72×10^6 /ml; normal 3.73 – 4.95×10^6 /ml, haemoglobin 10.3 g/dl; normal 10.7–15.3 g/dl). Enzyme-linked immunosorbent assay (ELISA) revealed increased levels of antibodies to BP180 (51; normal <9.0), but not desmoglein 1 or desmoglein 3. Although she did not have difficulty swallowing, upper gastrointestinal endoscopy demonstrated scarring in the oesophagus. A biopsy specimen obtained from a bullous lesion on her waist revealed subepidermal cleft without acantholysis. Indirect immunofluorescence analysis of 1 mol/l sodium chloride-split human skin revealed dermal side staining up to a titre of 1:10 (Fig. 1c). Immunoblotting analysis using an ethylenediaminetetraacetic acid (EDTA)-separated human dermal extract was performed as described previously (2) and revealed the presence of auto-antibodies reactive with the 290-kDa type VII collagen (Fig. 2). The patient's serum did not recognize epidermal extracts, recombinant BP180 NC16a, recombinant C-terminus of BP180, purified laminin-332, or concentrated supernatant of HaCaT cells. A diagnosis of EBA was made based on the clinical, histological and immunopathological findings. An increase in oral prednisolone to 50 mg daily failed to resolve the mucosal manifestations. Dyspnoea occurred together with hoarseness. Laryngeal endoscopy showed supraglottic stenosis due to swollen bilateral aryepiglottis associated with severe oedema, erosion and erythema (Fig. 1d), which required tracheotomy. Furthermore, she was treated with 1 g methylprednisolone for 3 days twice, followed by prednisolone 50 mg daily. These therapies improved erosion in the oral cavity and swelling in the aryepiglottis, leading to removal of the tracheotomy tube. As small blisters relapsed in the oral mucosa during gradual tapering of the prednisolone dose, colchicine was added at a

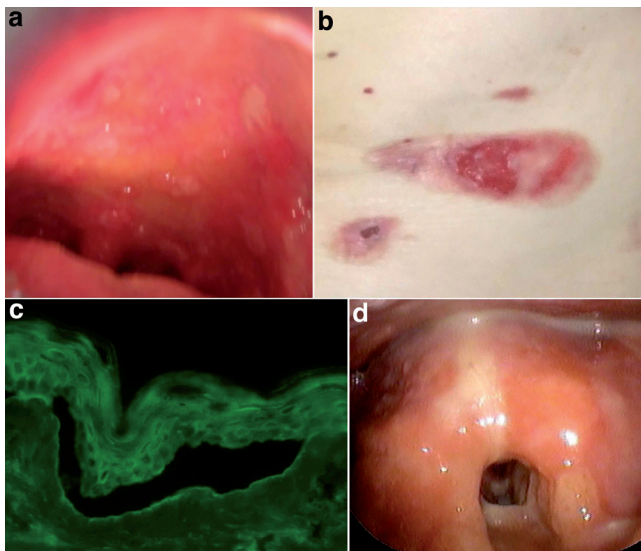


Fig. 1. (a) Multiple erosions in the oral mucosa. (b) Erosions on the waist. (c) Indirect immunofluorescence of patient serum on split human skin demonstrating binding of immunoglobulin G (IgG) to the dermal aspects of the blister. (d) Bilateral aryepiglottitis with severe swelling.




Fig. 2. Results of immunoblot analysis. Sera were reacted with human dermal extracts. Patient serum (lane 3) recognized 290-kDa type VII collagen, which was also detected by control epidermolysis bullosa acquisita (EBA) serum (lane 1). Lanes 1–2 show the reactivity of the control sera. Anti-p200 pemphigoid serum reacted with 200-kDa Laminin $\gamma 1$ (lane 2).

dose of 1 mg daily. Thereafter, relapse has not been observed and no laryngeal stenosis has developed.

DISCUSSION

We diagnosed this case as EBA, because of the dermal binding on salt-split indirect immunofluorescence, and the detection of type VII collagen on immunoblotting using dermal extract. However, the most intriguing issue in this case was a role of anti-BP180 antibodies detected by ELISA, which made it necessary to differentiate from anti-BP180 type MMP. However, there was no reactivity to the epidermal side of salt-split skin. Moreover, this patient serum did not show IgG or IgA antibodies to the recombinant protein of BP180 C-terminal domain, which is responsible for mucosal lesions. The negative IgG reactivity to BP180 NCI6a domain on immunoblotting also suggested that the positive result on ELISA might be non-specific. Therefore, we excluded the diagnosis of MMP.

The cutaneous lesions of EBA are varied and can mimic other types of acquired autoimmune bullous disease. The classical presentation is a mechanobullous disease marked by skin fragility, and the lesions are chiefly distributed in acral regions. Similar to our patient, some cases of EBA show predominant mucosal involvement with cicatricial pemphigoid-like clinical appearance. Our case was unique in the wide involvement of mucosal sites, such as the oral cavity, larynx and oesophagus. The mechanism of mucosal predominance remains to be determined. Three epitopes within the N-terminal non-collagenous (NC)-1 domain, the NC-2 domain and the triple-helical collagenous domain recognized by sera have been reported. Previous reports suggested that reactivity to different epitopes might be associated with variation of clinical phenotypes (2–4).

In EBA erosions and scars develop on the mucosal surfaces of the mouth, upper oesophagus, conjunctiva or anus with or without vesiculobullous lesions on the skin. However, laryngeal involvement is not a well-known complication of EBA, in contrast to that in cicatricial pemphigoid (5, 6). Luke et al. (6) reported four cases of EBA with manifestations in the pharynx and larynx. One of these patients had severe symptoms developing to airway deformity. Laryngeal damage occasionally caused hoarseness, impaired phonation and loss of voice, and led to irreversible respiratory distress. Although the symptoms are sometimes minimal and subclinical, disease activity may be extended to this area and be life-threatening. Accordingly, a laryngeal evaluation should be performed in cases of EBA with mucosal symptoms.

EBA usually responds poorly to treatment, and is often refractory to high doses of systemic corticosteroids. Cyclosporin A has been shown to be beneficial, but side-effects on renal function may limit its use (7). Intravenous immunoglobulin (IVIg) and rituximab have been successfully used for treatment of EBA (8, 9). Colchicine has also been recommended as a treatment option for EBA, although some patients did not respond to this agent (1, 10). In the present case, colchicine was useful for tapering of prednisolone.

At the time of writing, the patient has been in remission on 1 mg/day colchicine and prednisolone for 10 months.

REFERENCES

1. Ishii N, Hamada T, Dainichi T, Karashima T, Nakama T, Yasumoto S, et al. Epidermolysis bullosa acquisita: what's new? *J Dermatol* 2010; 37: 220–230.
2. Ishii N, Yoshida M, Hisamatsu Y, Ishida-Yamamoto A, Nakane H, Iizuka H, et al. Epidermolysis bullosa acquisita sera react with distinct epitopes on the NC1 and NC2 domains of type VII collagen: study using immunoblotting of domain-specific recombinant proteins and postembedding immunoelectron microscopy. *Br J Dermatol* 2004; 150: 843–851.
3. Jones DA, Hunt SW 3rd, Prisayanh PS, Briggaman RA, Gammon WR. Immunodominant autoepitopes of type VII collagen are short, paired peptide sequences within the fibronectin type III homology region of the noncollagenous (NC1) domain. *J Invest Dermatol* 1995; 104: 231–235.
4. Lapiere JC, Woodley DT, Parente MG, Iwasaki T, Wynn KC, Christiano AM, et al. Epitope mapping of type VII collagen. Identification of discrete peptide sequences recognized by sera from patients with acquired epidermolysis bullosa. *J Clin Invest* 1993; 92: 1831–1839.
5. Hester JE, Arnstein DP, Woodley D. Laryngeal manifestations of epidermolysis bullosa acquisita. *Arch Otolaryngol Head Neck Surg* 1995; 121: 1042–1044.
6. Luke MC, Darling TN, Hsu R, Summers RM, Smith JA, Solomon BI, et al. Mucosal morbidity in patients with epidermolysis bullosa acquisita. *Arch Dermatol* 1999; 135: 954–959.
7. Crow LL, Finkle JP, Gammon WR, Woodley DT. Clearing of epidermolysis bullosa acquisita with cyclosporine. *J Am Acad Dermatol* 1988; 19: 937–942.
8. Campos M, Silvente C, Lecona M, Suarez R, Lazaro P. Epidermolysis bullosa acquisita: diagnosis by fluorescence overlay antigen mapping and clinical response to high-dose intravenous immunoglobulin. *Clin Exp Dermatol* 2006; 31: 71–73.
9. Niedermeier A, Eming R, Pfütze M, Neumann CR, Happel C, Reich K, et al. Clinical response of severe mechanobullous epidermolysis bullosa acquisita to combined treatment with immunoadsorption and rituximab (anti-CD20 monoclonal antibodies). *Arch Dermatol* 2007; 143: 192–198.
10. Cunningham BB, Kirchmann TT, Woodley D. Colchicine for epidermolysis bullosa acquisita. *J Am Acad Dermatol* 1996; 34: 781–784.