

Melanoma in a 5-year-old Child with a Giant Congenital Melanocytic Naevus

Tiziana Surrenti¹, Andrea Diociaiuti¹, Alessandro Inserra², Antonella Accinni², Loredana Giraldi¹, Francesco Callea³ and May El Hachem¹

Departments of ¹Dermatology, ²Surgery and ³Pathology, Children's Hospital and Research Institute "Bambino Gesù", Piazza Sant'Onofrio, IT-00165 Rome, Italy. E-mail: tiziana.surrenti@opbg.net

Accepted September 28, 2011.

Melanoma, which is a rare neoplasm in the paediatric age-group, represents 1–3% of malignancies in children.

We describe here a 5-year-old child with a giant congenital melanocytic naevus (GCMN) who developed a malignant melanoma with rapid progression, metastases and death. This case emphasizes strongly the importance of an accurate and complete body inspection during the follow-up of children with GCMN and its preventive early surgical treatment.

CASE REPORT

A 5-year-old Caucasian child was referred to the Department of Surgery of our hospital for the presence of a subcutaneous palpable mass in the right inguinal region, which had been present for several months and was suspected to be an inguinal hernia. The patient underwent an ultrasound examination of the abdomen, which revealed a 4.5 × 3.8 cm mass, which was hypoechoic with a vascular component. Magnetic resonance imaging (MRI) of the pelvis showed that the inguinal mass was located very close to the bladder. The mass was surgically removed. Histopathological examination revealed a highly malignant tumour containing a variable amount of mostly extracellular melanin. The tumour was widely infiltrating the soft tissue and composed of large epithelioid or spindle cells arranged in a solid or fasciculated pattern with melanin pigment (Fig. 1A). Four nodes included within the mass were colonized by the tumour as a massive sinus involvement (Fig. 1B).

The tumour cells were positive on immunostaining for Vimentin, MART 1, S100, HMB45 (insert Fig. 1B), and negative for cytokeratin, desmin, actin, myogenin, CD99, LCA, synaptophysin, CD34, and chromogranin. On the basis of these results, a diagnosis of metastasis of melanoma was made, with the recommendation to search for the primary tumour. The requested dermatological examination revealed the presence of a giant melanocytic

naevus appearing as multiple pigmented and irregularly shaped hairy papules, patches and plaques covering the buttocks, the lower back, and the thighs, with a size for an area of more than 20 cm². The entire skin surface was examined carefully, and an asymmetrical pigmented black-bluish nodule was identified on the internal medial right gluteus (Fig. 2A). The clinical aspect and the dermoscopic examination, which revealed the presence of a large blue-grey veil and irregular globules, were suggestive for melanoma (Fig. 2B). The lesion had been present since birth. There was no family history of GCMN or melanoma.

The nodular atypical lesion was surgically removed with narrow margins and histology revealed a nodular melanoma composed of medium-large sized malignant cells exhibiting atypical vesicular nuclei and prominent nucleoli. The cytoplasm contained fine melanin granules. Mitoses were numerous and atypical. The tumour was infiltrating the entire dermis up to the hypodermis (Clark level V, Breslow 1.2 cm) with lymphatic emboli (Fig. 1C). The phenotype of tumour cells was identical to that of the inguinal/pelvic mass, HMB45, S100 and MART1 being intensively positive.

Total body contrast-enhanced computerized tomography (CT) examination did not reveal any further secondary localizations. Chemotherapy with weekly cycles of vinblastine, dacarbazine, cisplatin was performed without response. The child died 4 months later.

DISCUSSION

Melanoma is defined as paediatric when occurring from the *in utero* stage up to a cut-off ranging from 13 to 21 years (1). Paediatric melanoma accounts for 1–4% of all cases of melanoma (2). From 1973 to 2001, the incidence of paediatric melanoma has increased by 2.9% per year (2, 3). This increase is more rapid for adolescents than for children aged <10 years. The incidence

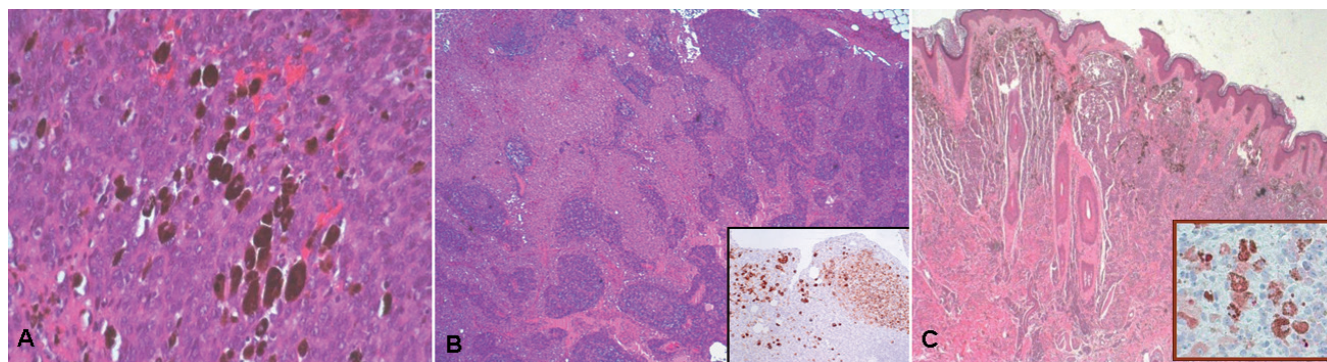


Fig. 1. (A) Malignant tumour with a solid pattern, made up of large macronucleated atypical cells and plugs of extracellular melanin pigment (haematoxylin and eosin (H&E) × 40). (B) Lymph node with massive sinus replacement by large epithelioid atypical cells with eosinophilic cytoplasm. The cells are positive for HMB45 staining (insert immunostaining × 10). (C) Nodular melanoma made up atypical epithelioid melanocytes. The tumour is widely invasive and is filling the entire dermis. Melanin pigment is abundant in the superficial part of the lesion. The tumour cells stain positively for HMB45 (H&E × 2.5, insert immunostaining × 40).

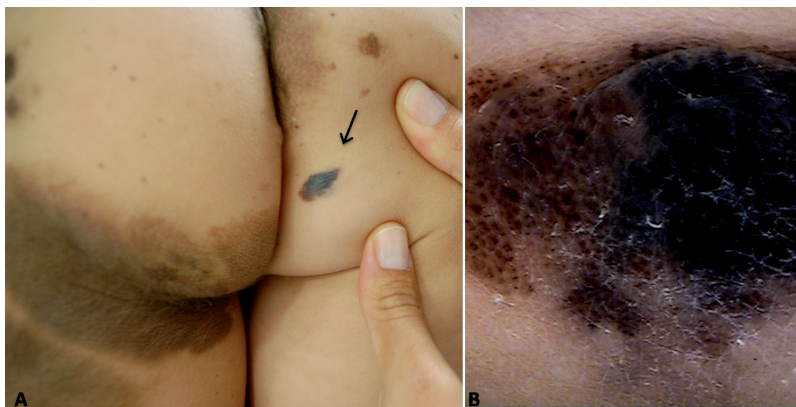

Fig. 2. (A) Melanoma arising in congenital giant melanocytic naevus. (B) Dermoscopic features.

of melanoma in the general population between the age of 10 and 14 years is 0.5% per 100,000 per year (4).

Congenital melanocytic naevi (CMN) are benign pigmented skin disorders found in approximately 1–2% of all newborns (5). The vast majority of CMN are of small size with low potential malignancy; giant lesions are 200 times less frequent than small ones, occurring in 1:20,000 in Caucasians, but involve a significantly higher risk of developing malignant melanoma (5, 6).

Kopf et al., (7) in 1979, proposed to classify CMN according to their largest diameter in adulthood into: small (<1.5 cm), medium (1.5–19.9 cm) and giant (>20 cm). However, some studies have demonstrated that the vast majority of melanomas arise in very large CMN with an adult diameter of ≥ 50 cm (8). For these reasons, in 2004 Ruiz-Maldonado recommended classifying CMN according to their largest diameter, as follows: small <1.5 cm; medium 1.5–10 cm; large 11–20 cm; giant G >20 cm; G1 21–30 cm; G2 31–40 cm; G3 >40 cm (9). In a systematic review of the melanoma risk in patients with CMN by Krenzel et al. (10), the overall risk from 14 studies was calculated to be 0.7%. This study confirms that the melanoma risk depends strongly on the size of CMN, with a lifetime risk of 3.1% for GCMN.

Melanomas developing in small-to-medium CMN begin to arise around puberty. In these lesions melanoma develops at the dermo-epidermal junction as melanoma *in situ*. There is an increased risk for malignant transformation in GCMN, and in such cases it generally starts before 10 years of age in the deep dermal component of the lesion (11, 12).

The majority of paediatric malignant melanomas arise *de novo* (13, 14). A significant proportion (up to 50%) of paediatric melanomas are amelanotic and show a nodular configuration (up to 30%) compared with adult melanomas (15). In addition, children's melanomas present a greater median thickness (Breslow 3.5 mm), possibly related to reluctance to perform biopsies in

children and, consequently, to delayed diagnosis (15).

It is generally accepted that a complete excision in early childhood decreases the risk of malignancy. Another option is a close monitoring by physical examination, including lymph node palpation and dermoscopy, with periodic follow-up and prompt excision if the lesion presents variations.

REFERENCES

1. Strouse JJ, Fears TR, Tucker MA, Wayne AS. Pediatric melanoma: risk factor and survival analysis of the surveillance, epidemiology and end results database. *J Clin Oncol* 2005; 23: 4735–4741.
2. Linabery AM, Ross JA. Trends in childhood cancer incidence in the US (1992–2004). *Cancer* 2008; 112: 416–432.
3. Fisher DE, Medrano EE, McMahon M, Soengas MS, Schuchter L, Wolchok JD, et al. Meeting report: Fourth International Congress of the Society for Melanoma Research. *Pigment Cell Melanoma Res* 2008; 21: 15–26.
4. Ries LAG, Eisner MP, Kosary CL, Hankey BF, Miller BA, Clegg L, et al. SEER Cancer Statistics Review, 1975–2002. Bethesda, MD: National Cancer Institute, 2005.
5. Mills O, Messin JL. Pediatric melanoma: a review. *Cancer Control* 2009; 16: 225–233.
6. Fishman C, Mihm MC, Sober AJ. Diagnosis and management of nevi and cutaneous melanoma in infants and children. *Clin Dermatol* 2002; 20: 44–50.
7. Kopf AW, Bart RS, Hennessey P. Congenital melanocytic nevi and malignant melanomas. *J Am Acad Dermatol* 1979; 1: 123–130.
8. Bett BJ. Large or multiple congenital melanocytic nevi: occurrence of cutaneous melanoma in 1008 persons. *J Am Acad Dermatol* 2005; 52: 793–797.
9. Ruiz-Maldonado R. Measuring congenital melanocytic nevi. *Pediatr Dermatol* 2004; 21: 178–179.
10. Krenzel S, Hauschild A, Schäfer T. Melanoma risk in congenital melanocytic naevi: a systematic review. *Br J Dermatol* 2006; 155: 1–8.
11. Ruiz-Maldonado R, del Rosario Barona-Mazuera M, Hidalgo-Galván LR, Medina-Crespo V, Durán-Mckinster C, et al. Giant congenital melanocytic nevi, neurocutaneous melanosis and neurological alterations. *Dermatology* 1997; 195: 125–128.
12. Ruiz-Maldonado R, Orozco-Covarrubias ML. Malignant melanoma in children. A review. *Arch Dermatol* 1997; 133: 363–371. Erratum in: *Arch Dermatol* 1997; 133: 833.
13. Downard CD, Rapkin LB, Gow KW. Melanoma in children and adolescents. *Surg Oncol* 2007; 16: 215–220.
14. Jafarian F, Powell J, Kokta V, Champagne M, Hatami A, McCuaig C, et al. Malignant melanoma in childhood and adolescence: report of 13 cases. *J Am Acad Dermatol* 2005; 53: 816–822.
15. Ferrari A, Bono A, Baldi M, Collini P, Casanova M, Pennacchioli E, et al. Does melanoma behave differently in younger children than in adults? A retrospective study of 33 cases of childhood melanoma from a single institution. *Pediatrics* 2005; 115: 649–654.