

CLINICAL REPORT

Cutaneous Manifestations of *Helicobacter cinaedi* Infection

Satoko SHIMIZU¹, Daisuke INOKUMA¹, Mika WATANABE¹, Toshiya SAKAI², Satoshi YAMAMOTO², Kikuo TSUCHIYA¹ and Hiroshi SHIMIZU³

Departments of ¹Dermatology and ²Hematology, Sapporo City General Hospital, and ³Department of Dermatology, Hokkaido University Graduate School of Medicine, Sapporo, Hokkaido, Japan

***Helicobacter cinaedi* causes gastroenteritis and bacteraemia, particularly in immunocompromised individuals. Although cellulitis is sometimes reported to accompany infection by this pathogen, the cutaneous manifestations are poorly understood. To clarify the characteristic cutaneous features, 47 cases of *H. cinaedi* bacteraemia experienced at Sapporo City General Hospital as nosocomial infection were retrospectively evaluated. Thirty-four percent (16 cases) of the patients showed cutaneous lesions. They all had sudden onset of erythemas accompanied by high temperature. The most common cutaneous manifestations were found to be superficial cellulitis, which results in painful erythemas or infiltrated erythematous plaques on the extremities. These skin lesions can be an early clinical indicator of *H. cinaedi* bacteraemia in the setting of nosocomial infection. Key words: *Helicobacter cinaedi*; cellulitis; infection; cutaneous manifestation.**

Accepted Mar 26, 2012; Epub ahead of print Jun 27, 2012

Acta Derm Venereol 2013; 93: 165–167.

Satoko Shimizu, Department of Dermatology, Sapporo City General Hospital, North 11, West 13, Chuo-ku, Sapporo 060-8604, Japan. E-mail: rxel0376@nifty.com

Helicobacter cinaedi is a Gram-negative spiral bacillus that inhabits the intestinal tracts of mammals and causes gastroenteritis and bacteraemia, particularly in immunocompromised individuals (1). Unlike *H. pylori*, *H. cinaedi* often invades the bloodstream and sometimes causes bacteraemia, cellulitis and other clinical symptoms (2). However, no case has been reported in the major international dermatology literature, and the cutaneous manifestations are poorly understood.

Sapporo City General Hospital experienced nosocomial *H. cinaedi* infection in 2008 (3), and 47 cases of *H. cinaedi* bacteraemia were confirmed as of November 2011. We report here the skin lesions of these patients, all of Japanese origin.

METHODS

Skin lesions of 47 cases of *H. cinaedi* bacteraemia were retrospectively evaluated with the medical charts from March 2008 to November 2011 at Sapporo City General Hospital. Sixteen of the 47 cases showed cutaneous lesions. Nine of the patients who

were referred to the department of dermatology were described in detail by certificated dermatologists. Standard histopathological and immunohistochemical examinations were carried out. Blood culture was performed using an automatic blood culture system (BACTEC9120, Nippon Becton Dickinson Co., Ltd, Japan) with 92F aerobic and 93F anaerobic resin bottles. The culture period was 10 days. The strains that formed distinctive film-like colonies on the plate and presented as Gram-negative spiral bacillus were morphologically identified as *H. cinaedi*. Seventeen of the 47 cases were further identified by PCR in accordance with the method of Ohkusu et al. (3, 4).

RESULTS

Examples of cases

Case 1. A 63-year-old man, who was on haemodialysis due to chronic renal failure, had high fever, rash and arthralgia for 6 days. He presented with 5 painful, dark-red erythemas up to 8 cm in diameter on the upper and lower extremities (Fig. 1A). The patient reported skin tenderness as well as arthralgia. His medication had not been changed for more than one year. Blood tests revealed leukocytosis (9,000/μl; normal range: 4,000–8,000/μl) and elevated C-reactive protein (CRP) (11.6 mg/dl; normal: <0.3 mg/dl). *H. cinaedi* was isolated from blood culture and identified by PCR. Oral clarithromycin and cefdinir reduced the redness and pain of the skin.

Case 2. A 79-year-old man who was undergoing his fourth course of chemotherapy (carboplatin and paclitaxel) for lung cancer had had fever, diarrhoea and rash for 3 days. Twelve painful, reddish-to-violaceous erythemas were observed on the upper and lower extremities (Fig. 1B, C). The erythemas were poorly infiltrated and sized between 3- to 7-cm in diameter. The patient's medication and chemotherapy regimen had not been changed recently. Blood test revealed elevated CRP (16.54 mg/dl). Oral amoxicillin and intravenous meropenem reduced the skin redness. *H. cinaedi* was isolated from blood culture.

Case 3. A 62-year-old man who was undergoing his fourth course of chemotherapy (cisplatin and gemcitabine) for lung cancer had had fever (38.8°C) and rash for 2 days. Two 8-cm infiltrated erythemas were seen on the left leg and a 10-cm indurated erythematous plaque on the right knee (Fig. 1D). He reported experiencing pain and heat on the infiltrated erythematous plaques;

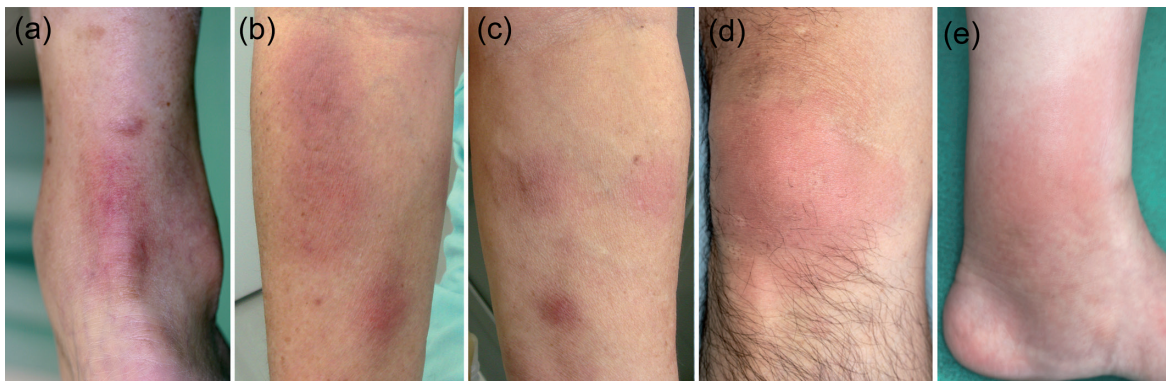


Fig. 1. Clinical appearance of (a) case 1, (b, c) case 2, (d) case 3, and (e) case 4.

however, the induration was less than erythema nodosum. The patient's medication and chemotherapy regimen had not been changed recently. Blood test revealed leukocytosis (8,300/ μ l), and CRP was 5.12 mg/dl. Skin biopsy was taken from the erythematous plaque on the knee. Intravenous ampicillin/sulbactam cleared up the skin lesions in 2 weeks. *H. cinaedi* was isolated from blood culture and identified by PCR.

Case 4. A 56-year-old woman who was undergoing chemotherapy for follicular lymphoma was referred to the department of dermatology with fever (38.0°C) and 5- to 7-cm, tender reddish-to-violaceous, slightly infiltrated erythemas on the left calf and the back of the left foot (Fig. 1E). She had repeatedly experienced fever and rash on the legs for 5 months. The fever and rash disappeared with amoxicillin; however, they recurred after a while. When she consulted the department of dermatology, blood tests revealed elevated CRP (1.79 mg/dl). Blood culture performed on the first day of fever proved positive for *H. cinaedi* after 7 days. Intravenous cefepime reduced the fever and the skin redness; however, symptoms recurred after 2 months without apparent triggers.

Summary of the 47 cases

Sixteen of the 47 cases (34%) of *H. cinaedi* bacteraemia showed cutaneous lesions. The ages of the 16 patients ranged from 37 to 79 years (mean 62.6 years), and all were immunocompromised; 8 lymphoma patients and 4 lung cancer patients were on chemotherapy, 3 were on immunosuppressive therapy for autoimmune haemolytic anaemia, dermatomyositis and Sjögren syndrome, and one was on haemodialysis due to chronic renal failure. They had sudden onset of painful reddish eruption in the extremities, accompanied by high temperature and elevated CRP. *H. cinaedi* was isolated from blood. Detailed observation of the skin lesions in 9 cases by certified dermatologists revealed reddish-to-violaceous erythemas with tenderness and hotness on the extremities (Table SI; available from: <http://www.medicaljournals.se/acta/content/?doi=10.2340/00015555-1396>).

Three cases showed infiltrated erythematous plaques (cases 3, 8 and 9); however, erythemas in 6 cases lacked apparent infiltration. Each erythema or plaque ranged from 2 to 14 cm in diameter, and the numbers of lesions seen in a patient ranged from 2 to 12. Eight of the 9 cases accompanied local pain.

Based on clinical grounds, the differential diagnosis should include Sweet syndrome, fixed drug eruption, urticaria and erythema nodosum. Histopathology of all 5 cases showed inflammatory infiltration of lymphocytes and neutrophils in the reticular dermis and mild septal panniculitis, with small numbers of lymphocytes and neutrophils (Fig. 2). No vasculitis was seen. No pathogens were detected on Giemsa staining or Warthin-Starry staining. All 9 patients responded well to antimicrobial agents, including amoxicillin, ampicillin/sulbactam and meropenem. However, in 5 of the 9 cases, bacteraemia and skin lesions recurred, which is consistent with previous case reports of immunocompromised patients (5). No patient died of *H. cinaedi* infection. Only 2 cases (cases 3 and 8) were correctly and thoroughly diagnosed as cellulitis on the clinical features of skin lesions alone, but other cases were finally diagnosed as mild superficial cellulitis from the overall findings, including the skin pathology, results of blood culture, and good response to the antimicrobial therapy.

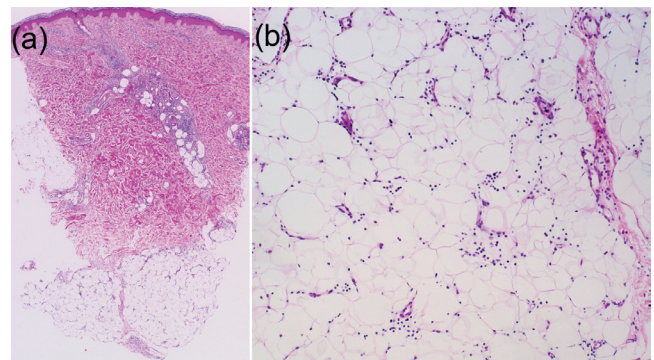


Fig. 2. Histopathology of case 2 (haematoxylin and eosin, original magnification (a) $\times 25$, (b) $\times 200$).

DISCUSSION

A review of the literature revealed 10 reports of *H. cinaedi* bacteraemia with skin lesions, describing a total of 37 cases (1–3, 6–12). There was no dermatological case report. Clinical photographs were provided in only 2 cases (1, 3) and no skin biopsy was performed. The skin manifestations were described as “cellulitis” in 30 cases (11 cases: solitary lesion; 9 cases: cellulitis at more than 1 site; 10 cases: not described), as “erythema nodosum-like eruption” in 1 case, as “erythema” in 1 case, as “pigmented macule” in 1 case and as “erysipelas-like eruption” in 1 case. These symptoms are considered to be secondary bacterial involvement of the skin through haematogenous spread from the gastrointestinal tract (13).

In the present study, only 2 of 9 cases were correctly diagnosed as cellulitis from the skin manifestations alone, because other cases showed no or only slight infiltration and they looked different from common cellulitis as seen in the immunocompetent host. The term “cellulitis” usually applies to inflammation of dermis as well as subcutaneous tissue in which a bacterial cause is assumed (14). All of our cases were compatible with cellulitis or superficial cellulitis according to this usage; however, it should be noted that the predominant cutaneous manifestations of *H. cinaedi* are “painful erythemas” or “infiltrated erythemas” rather than common cellulitis. Erythema nodosum, which also shows septal panniculitis, was excluded because erythemas disappeared completely in several days after the administration of antibiotics, without leaving any indurations. These painful erythemas are not typical cutaneous manifestations as a sign of bacterial infection, and could be overlooked easily. As this organism grows slowly in culture, it usually takes 6–10 days until the existence of the organism can be seen in blood culture. The delay in receiving the culture result could lead to the patients being wrongly diagnosed as Sweet’s syndrome and treated inappropriately if the condition is not considered. These lesions can indeed be an early clinical indicator of *H. cinaedi* bacteraemia in the setting of nosocomial infection.

Bacteraemia caused by Gram-negative enteric bacilli occasionally leads to secondary involvement of the skin and subcutaneous tissues. For example, *Vibrio vulnificus* causes cellulitis or more severe infection of subcutaneous tissue through haematogenous spread from the gastrointestinal tract. A similar syndrome is produced rarely by *Aeromonas hydrophila*, *Bacteroides* species, *Yersinia enterocolitica*, *Serratia marcescens* and *Campylobacter fetus* (15). These symptoms are considered to be those of endovascular infection (13).

In conclusion, the most common cutaneous manifestation of *H. cinaedi* bacteraemia is superficial cellulitis, which usually takes the form of painful erythemas or infiltrated erythematous plaques on the extremities. This

study demonstrates the importance of a high index of suspicion for bacteraemia in immunocompromised patients with this skin lesion in the setting of nosocomial infection. Although the epidemiology of this organism is not fully understood, dermatologists should be aware that painful erythemas are a characteristic skin manifestation of *H. cinaedi* infection.

The authors declare no conflicts of interest.

REFERENCES

1. Kitamura T, Kawamura Y, Ohkusu K, Masaki T, Iwashita H, Sawa T, et al. Helicobacter cinaedi cellulitis and bacteremia in immunocompetent hosts after orthopedic surgery. *J Clin Microbiol* 2007; 45: 31–38.
2. Kiehlbauch JA, Tauxe RV, Baker CN, Wachsmuth IK. Helicobacter cinaedi-associated bacteremia and cellulitis in immunocompromised patients. *Ann Intern Med* 1994; 121: 90–93.
3. Minauchi K, Takahashi S, Sakai T, Kondo M, Shibayama K, Arakawa Y, et al. The nosocomial transmission of Helicobacter cinaedi infections in immunocompromised patients. *Intern Med* 2010; 49: 1733–1739.
4. Ohkusu K, Ezaki T. [Helicobacter cinaedi infection.] *Kansen Ensho Meneki* 2007; 37: 336–339 (in Japanese).
5. Kiehlbauch JA, Brenner DJ, Cameron DN, Steigerwalt AG, Makowski JM, Baker CN, et al. Genotypic and phenotypic characterization of Helicobacter cinaedi and Helicobacter fennelliae strains isolated from humans and animals. *J Clin Microbiol* 1995; 33: 2940–2947.
6. Simons E, Spacek LA, Lederman HM, Winkelstein JA. Helicobacter cinaedi bacteremia presenting as macules in an afebrile patient with X-linked agammaglobulinemia. *Infection* 2004; 32: 367–368.
7. Burman WJ, Cohn DL, Reves RR, Wilson ML. Multifocal cellulitis and monoarticular arthritis as manifestations of Helicobacter cinaedi bacteremia. *Clin Infect Dis* 1995; 20: 564–570.
8. Holst H, Andresen K, Blom J, Hojlyng N, Kemp M, Krogfelt KA, et al. A case of Helicobacter cinaedi bacteraemia in a previously healthy person with cellulitis. *Open Microbiol J* 2008; 2: 29–31.
9. Yoda K, Ito T, Matuda Y, Murotani N. Isolation of Helicobacter cinaedi from a sepsis patient with cellulitis. *Jpn J Infect Dis* 2009; 62: 169–170.
10. Tee W, Street AC, Spelman D, Munckhof W, Mijch A. Helicobacter cinaedi bacteraemia: varied clinical manifestations in three homosexual males. *Scand J Infect Dis* 1996; 28: 199–203.
11. Van Genderen PJ, Goessens WH, Petit PL. Helicobacter cinaedi-associated bacteraemia and erysipelas in an immunocompetent host: a diagnostic challenge. *Scand J Infect Dis* 2005; 37: 382–385.
12. Sullivan AK, Nelson MR, Walsh J, Gazzard BG. Recurrent Helicobacter cinaedi cellulitis and bacteraemia in a patient with HIV Infection. *Int J STD AIDS* 1997; 8: 59–60.
13. van der Ven AJ, Kullberg BJ, Vandamme P, Meis JF. Helicobacter cinaedi bacteremia associated with localized pain but not with cellulitis. *Clin Infect Dis* 1996; 22: 710–711.
14. Burns T, Breathnach S, Cox N, Griffiths C. *Rook’s textbook of dermatology*. 8th edn. Oxford, UK: Wiley-Blackwell, 2010.
15. Carbone K, Heinrich M, Quin T. Thrombophlebitis and cellulitis due to Campylobacter fetus ssp. fetus. *Medicine* 1985; 64: 244–250.