

SHORT COMMUNICATION

A Case of Toxic Epidermal Necrolysis Induced by Allopurinol with Human Herpesvirus-6 Reactivation

Yuko Watanabe¹, Setsuko Matsukura², Yuji Isoda², Akiko Morita², Michiko Aihara¹ and Takeshi Kambara²¹Department of Environmental Immuno-Dermatology, Yokohama City University Graduate School of Medicine, 3-9 Fukuura, Kanazawa-ku, Yokohama, Kanagawa 236-0004, and ²Department of Dermatology, Yokohama City University Medical Center, Yokohama, Japan. E-mail: yukowata@yokohama-cu.ac.jp
Accepted Feb 4, 2013; Epub ahead of print Apr 19, 2013

Stevens-Johnson syndrome (SJS)/toxic epidermal necrolysis (TEN) and drug-induced hypersensitivity syndrome (DIHS) or drug rash with eosinophilia and systemic symptoms (DRESS) (1, 2) are severe adverse drug reactions (ADRs). Recently, human herpesvirus 6 (HHV-6) reactivation has been observed frequently in patients with DIHS/DRESS, but not in SJS/TEN (3–5). Therefore, it has been suggested that HHV-6 is closely related to the pathogenesis of DIHS, but not to that of SJS/TEN (6, 7). We report here a case of TEN induced by allopurinol, accompanied by HHV-6 reactivation.

CASE REPORT

A 73-year-old woman was treated for gout with allopurinol (300 mg/day). Twelve days later, she developed a rash with sore throat and fever. Three days after that, on day 4, erosions appeared on her lips and oral mucosa. She had had a past history of rash induced by allopurinol. She was diagnosed as having SJS, and allopurinol was discontinued. Although systematic betamethasone (6 mg/day) was started the next day, the rash increased rapidly and became confluent. She was referred to our hospital on day 9. Physical examination revealed high fever and haemorrhagic erosions on the lips, oral mucosa (Fig. S1; available from: <http://www.medicaljournals.se/acta/content/?doi=10.2340/00015555-1610>), and genital region, as well as skin rash. Multiple erythematous lesions, including atypical target lesions, were observed on her entire body, and were confluent with blisters and erosions (Fig. 1a). No lymphadenopathy was observed. Approximately 80% of the body surface area was detached. Laboratory investigations disclosed a high white blood cell count ($12.49 \times 10^9/l$) with atypical lymphocytes (1.5%), hypoproteinaemia (4.0 g/dl), increased serum creatinine (1.24 mg/dl), hypoinmunoglobulinaemia (IgG, 352 mg/dl), and a high CD4/CD8 ratio (2.9). There was no liver dysfunction (aspartate aminotransferases (AST) 8 U/l and alanine aminotransferase (ALT) 8 U/l), but there was pulmonary oedema. Eosinophil was not detected in the blood, but increased

later (Fig. 2). A skin biopsy obtained from the left thigh showed epidermal necrosis and subepidermal blisters. Infiltration with mononuclear cells was observed in the upper dermis (Fig. 1b). Taken together, the diagnosis on admission was TEN due to allopurinol. Later, it was established that she had the HLA-B*58:01 leukocyte antigen type.

The patient was treated with steroid pulse therapy with methylprednisolone at 1,000 mg/day for 3 days, and twice with plasma exchange. In addition, 5 g/day of immunoglobulin was administered for 3 days because of hypoinmunoglobulinaemia.

With these treatments, progression of the rash stopped, and re-epithelialization began. Eye lesions, which are often observed in TEN, such as conjunctival injection and pseudomembranes appeared after day 51. The anticytomegalovirus IgG titre was as high as 128 by enzyme-linked immunosorbent assay (ELISA) on day 66.

Peripheral blood samples were obtained for virological examination. Titres of IgG antibodies to HHV-6 were determined using an immunofluorescent (IF) antibody assay. The HHV-6 IgG antibody titre increased from 1:40 on day 12 to 1:1,240 on day 21. The HHV-6 DNA level in a sample of peripheral blood was 3.0×10^4 copies in 10^6 peripheral blood mononuclear cells and 3.5×10^5 copies/ml serum on day 12 by real-time quantitative PCR. There were no significant changes in specific IgG titres for herpes simplex virus, HHV-7, or Epstein-Barr virus during the course of the study. The DNA of these viruses was not detected in the serum.

The results of lymphocyte transformation tests and patch tests were negative for allopurinol and oxypurinol. On day 66, the patient was transferred to another hospital near her home. After that, the patient's erosive rash recurred, and eventually, she died of sepsis.

DISCUSSION

The patient was diagnosed with an ADR due to allopurinol. This diagnosis was supported by the development of a rash after administration of allopurinol, by the past history of allopurinol-induced rash, and by HLA-

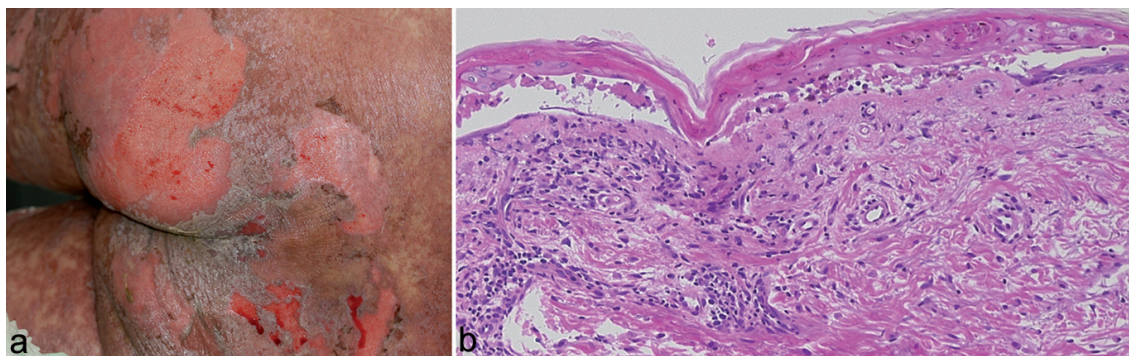


Fig. 1. Clinical features: (a) multiple erythematous lesions were confluent and widely detached. Histopathological features: (b) a skin biopsy showed necrosis of the epidermis and subepidermal blisters.

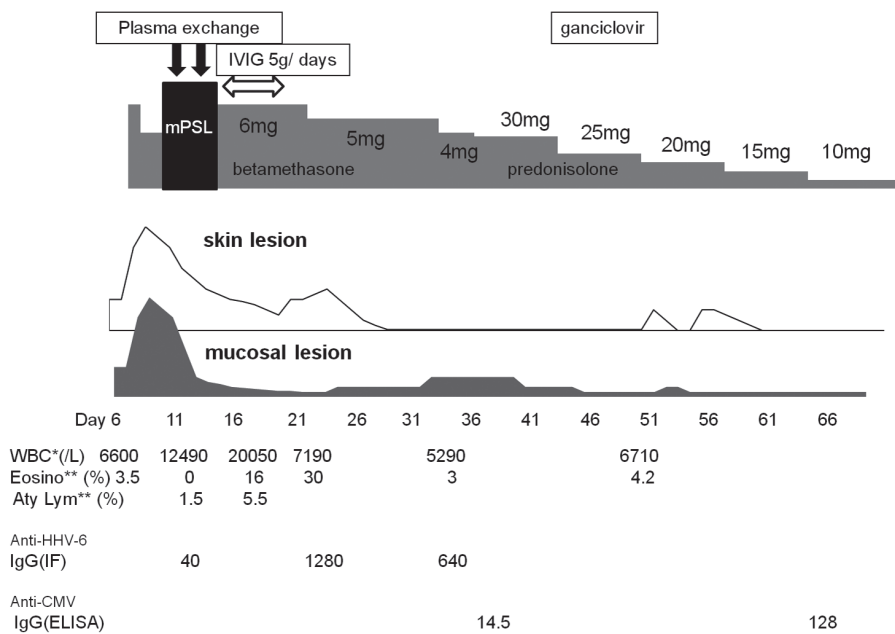


Fig. 2. Clinical course. Lesions on the patient's skin and oral mucosa recurred several times, with high fever, increase in atypical lymphocytes, eosinophilia, and human herpesvirus (HHV)-6 and cytomegalovirus (CMV) reactivation. *WBC: white blood cell count; **Eosino: eosinophils; ***Aty Lym: atypical lymphocytes.

B*58:01 positivity. It was concluded that the type of ADR was TEN with HHV-6 reactivation. Symptoms consistent with TEN were as follows: (i) severe mucosal lesions, (ii) widespread skin detachment, and (iii) histopathological findings of epidermal necrosis and subepidermal blisters. Some symptoms consistent with DRESS were also observed as follows: (i) high fever, (ii) acute skin rash, (iii) peripheral blood abnormalities, such as leukocytosis, eosinophilia, and atypical lymphocytosis. In addition, reactivation of HHV-6 and CMV as well as several recurrences of skin rash were consistent with DIHS. Although serious internal organ involvement was not observed, pulmonary oedema and a mild increase in serum creatinine were observed.

HHV reactivation is rarely observed in patients with SJS/TEN. Only a few cases have been reported as SJS/TEN associated with HHV-6 reactivation (8, 9), and TEN with HHV-7 reactivation (10). These patients did not show frequent recurrence and haematological abnormalities as observed in our patient. Since our patient showed clinical features of TEN accompanied with some symptoms of DRESS with HHV-6 and CMV reactivation, we conclude that viral reactivation is involved in the clinical course. Clinicians should consider sequential testing for HHV-6 with prolonged SJS/TEN, especially when induced by drugs known to be causative of DIHS, including allopurinol and anti-epileptics.

ACKNOWLEDGEMENTS

This work was partly supported by Health and Labor Sciences Research Grants (Research on Intractable Diseases) from the Ministry of Health, Labor and Welfare of Japan.

REFERENCES

- Roujeau JC, Stern RS. Severe cutaneous reactions to drugs. *N Engl J Med* 1994; 331: 1272–1285.
- Cacoub P, Musette P, Descamps V, Meyer O, Speirs C, Finzi L, et al. The DRESS syndrome: a literature review. *Am J Med* 2011; 124: 588–597.
- Descamps V, Valance A, Edlinger C, Fillet AM, Grossin M, Lebrun-Vignes B, et al. Association of human herpesvirus 6 infection with drug reaction with eosinophilia and systematic symptoms. *Arch Dermatol* 2001; 137: 301–304.
- Suzuki Y, Inagi R, Aono T, Yamanishi K, Shiohara T. Human herpesvirus 6 infection as a risk factor for the development of severe drug-induced hypersensitivity syndrome. *Arch Dermatol* 1998; 134: 1108–1112.
- Tohyama M, Yahata Y, Yasukawa M, Inagi R, Urano Y, Yamanishi K, et al. Severe hypersensitivity syndrome due to sulfasalazine associated with reactivation of human herpesvirus 6. *Arch Dermatol* 1998; 134: 1113–1117.
- Shiohara T, Iijima M, Ikezawa Z, Hashimoto K. The diagnosis of a DRESS syndrome has been sufficiently established on the basis of typical clinical features and viral reactivations. *Br J Dermatol* 2007; 156: 1083–1084.
- Tohyama M, Hashimoto K, Yasukawa M, Kimura H, Horikawa T, Nakajima K, et al. Association of human herpesvirus 6 reactivation with the flaring and severity of drug-induced hypersensitivity syndrome. *Br J Dermatol* 2007; 157: 934–940.
- Teraki Y, Murota H, Izaki S. Toxic epidermal necrolysis due to zonisamide associated with reactivation of human herpesvirus 6. *Arch Dermatol* 2008; 144: 232–235.
- Peppercorn AF, Miller MB, Fitzgerald D, Weber DJ, Groben PA, Cairns BA. High-level human herpesvirus-6 viremia associated with onset of Stevens-Johnson syndrome: report of two cases. *J Burn Care Res* 2010; 31: 365–368.
- Honma M, Tobisawa S, Inuma S, Shibuya T, Komatsu S, Takahashi I, et al. Toxic epidermal necrolysis with prominent facial pustules: a case with reactivation of human herpesvirus 7. *Dermatology* 2010; 221: 306–308.