

SHORT COMMUNICATION

Successful Treatment of Anal and Perianal Condyloma Acuminata with Imiquimod

Chisato Tawada¹, Yoko Oshitani¹, Masaki Kimura² and Mariko Seishima^{1*}*Departments of ¹Dermatology and ²General and Cardiothoracic Surgery, Gifu University Graduate School of Medicine, 1-1 Yanagido, Gifu City 501-1194, Japan. *E-mail: marikoseishima@yahoo.co.jp**Accepted Mar 18, 2013, Epub ahead of print Jul 4, 2013*

Condyloma acuminata are genital or perianal warts caused mainly by human papillomavirus (HPV) types 6 and 11. In HIV-positive patients and in men who have sex with men (MSM), the prevalence of anal HPV infection is particularly high (45–95%) (1). Current therapies for condyloma acuminata include surgical excision and ablation by cryotherapy, electrocautery, or lasers. Imiquimod, a topical immune-response modifier, is also effective against condyloma acuminata and skin tumours, such as basal cell carcinoma and actinic keratosis (2). However, it is not practical to apply this cream topically to the mucous membranes of the anal canal, particularly inside the dentate line. Imiquimod has therefore been applied via suppositories (anal tampons) to anal canal condylomas (3). We report here a recurrent case of perianal and anal condyloma acuminata that was treated successfully with topical imiquimod to the perianal area. This report supports the widely held belief that imiquimod can induce a field effect in an area, such that susceptible lesions adjacent to the treated area can also be eradicated.

CASE REPORT

A 21-year-old Japanese man noted anal oozing and an increasing number of small papillomatous papules on his perianal skin 2 months before the first consultation. At the first consultation, several papules and nodules, 2–5 mm in diameter, were observed around the anus (Fig. 1a). A large number of nodules, 5–35 mm in diameter, were observed by colonoscopy on the mucous membrane of the anal canal, around the dentate line (Fig. 1d). Histological examination of a perianal papule biopsy specimen resulted in a diagnosis of condyloma acuminata. The patient was an HIV-positive MSM who had not yet received AIDS therapy because CD4-positive T-cell count was 431/μl.

The perianal condyloma acuminata were treated with cryotherapy. The anal lesions were surgically removed, and they were also histologically confirmed as condyloma acuminata. Only the perianal condyloma acuminata recurred after 2 months (Fig. 1b) and topical treatment with 5% imiquimod cream, 3 times per week for 2 months, resulted in disappearance of these lesions (Fig. 2). However, both the perianal and anal lesions recurred after a further 5 months. Topical treatment with 5% imiquimod cream applied to the perianal lesions, 3 times per week, reduced the perianal lesions. However,

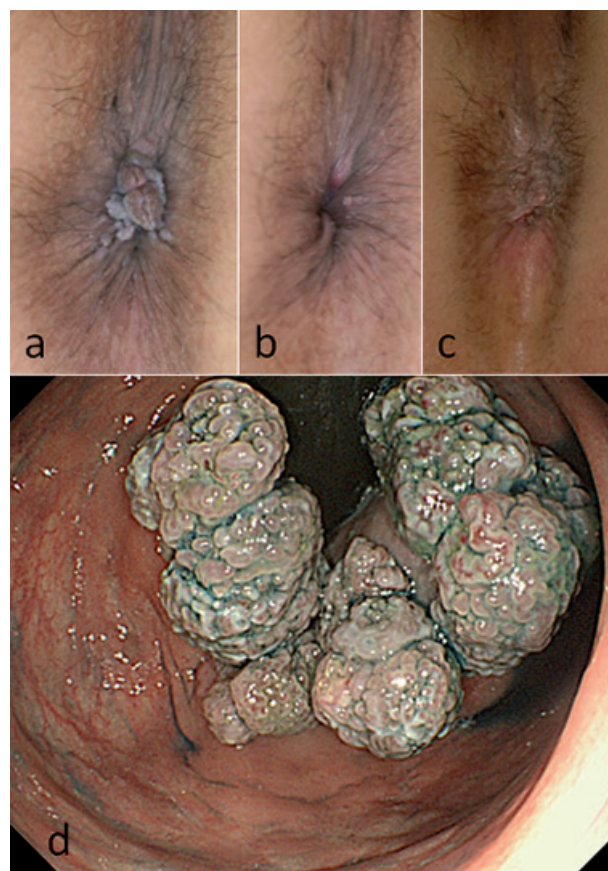


Fig. 1. Clinical presentation of the perianal lesions at (a) the first consultation, (b) the first recurrence, and (c) after imiquimod treatment. (d) Colonoscopic presentation of the anal lesions at the first consultation.

several papules, 2–3 mm in diameter, persisted on the mucous membrane of the anal canal after 3 weeks of treatment. Subsequently, the perianal and anal lesions disappeared by additional imiquimod treatment for 3 weeks (Fig. 1c). No recurrence was observed at least for 3 months.

DISCUSSION

Anal and perianal condyloma acuminata disappeared following topical application of imiquimod to the perianal lesions in the present case. Imiquimod is used for treating condyloma acuminata by dermatologists more often than by colorectal surgeons (1). Although imiquimod can directly induce the apoptosis of virus-infected keratinocytes, its ability to regulate immune cells also

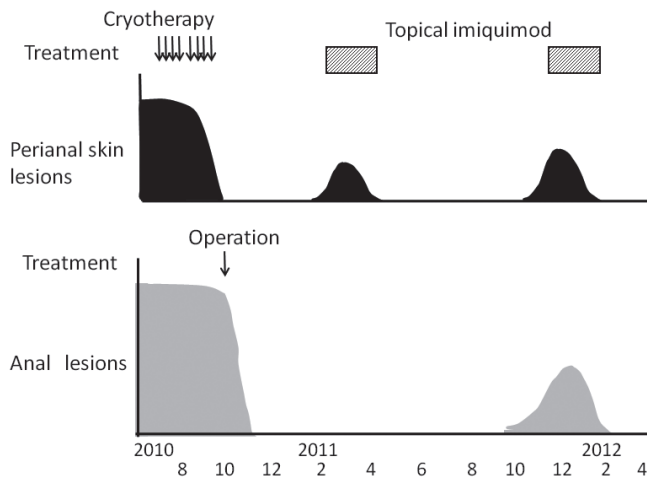


Fig. 2. Clinical findings and treatments.

plays an important role in antiviral effects of imiquimod. The innate immune system is highly developed in its ability to discriminate between self and foreign pathogens. To a great extent, this discrimination relies on a family of evolutionarily conserved receptors, toll-like receptors (TLRs), which play a crucial role in early host defence against pathogens. In addition, activation of the innate immune system results in the secretion of cytokines, including interferon (IFN)- α , interleukin (IL)-12, and tumour necrosis factor (TNF)- α , from monocytes and macrophages. In turn, these cytokines promote the induction of a predominant T helper 1 (Th1)-cell response. Imiquimod, which is a TLR7- and TLR8-specific ligand, promotes an initially low secretion of proinflammatory cytokines, such as TNF- α , IFN- γ , and IL-12, by macrophages and dermal dendritic cells (DCs) (4), thereby attracting an increasing number of type I IFN-producing plasmacytoid DCs from the blood. In response to the proinflammatory cytokines, Langerhans' cells leave the epidermis and migrate into the lymph nodes (5), leading to an increased presentation of viral or tumour antigens in the draining lymph nodes and, consequently, to an increased generation of virus- or tumour-specific T cells. The increased availability of these specific T cells in the peripheral blood, together with increased rolling of lymphocytes on TLR7-triggered endothelia in the vicinity of the treated skin area, leads to a preferential infiltration and accumulation of virucidal or tumoricidal effector cells in the treated skin (6).

Imiquimod has been reported to treat basal cell carcinomas and significantly decrease the number of new tumours (7). This pharmaceutical agent may stimulate

the patient's immune system sufficiently to prevent the development of basal cell carcinomas. In addition, several cases of psoriasis triggered by imiquimod have been reported recently (8–10). In the present case, the recurrent lesions in the anal canal disappeared after topical treatment with imiquimod to the perianal area. These results suggest that topical imiquimod treatment promoted a localized antiviral effect in the anal mucous membrane, adjacent to the perianal area, and/or showed a systemic effect on the anal lesions via the immune response. However, spontaneous regression of anogenital warts, which occurs in 10–30% of patients, due to cell-mediated immunity, cannot be ruled out in the present case (1).

The authors declare no conflict of interest.

REFERENCES

- Dindo D, Nocito A, Schettle M, Clavien PA, Hahnloser D. What should we do about anal condyloma and anal intraepithelial neoplasia? Results of a survey. *Colorectal Dis* 2011; 13: 796–801.
- Tyring SK, Arany I, Stanley MA, Tomai MA, Miller RL, Smith MH, et al. A randomized, controlled, molecular study of condyloma acuminata clearance during treatment with imiquimod. *J Infect Dis* 1998; 178: 551–558.
- Kaspari M, Gutzmer R, Kaspari T, Kapp A, Brodersen JP. Application of imiquimod by suppositories (anal tampons) efficiently prevents recurrences after ablation of anal canal condyloma. *Br J Dermatol* 2002; 147: 757–759.
- Ito T, Amakawa R, Kaisho T, Hemmi H, Tajima K, Uehira K, et al. Interferon- α and interleukin-12 are induced differentially by Toll-like receptor 7 ligands in human blood dendritic cell subsets. *J Exp Med* 2002; 195: 1507–1512.
- Suzuki H, Wang B, Shivji GM, Toto P, Amerio P, Tomai MA, et al. Imiquimod, a topical immune response modifier, induces migration of Langerhans cells. *J Invest Dermatol* 2000; 114: 135–141.
- Schiller M, Metze D, Luger TA, Grabbe S, Gunzer M. Immune response modifiers – mode of action. *Exp Dermatol* 2006; 15: 331–341.
- Czarnecki C, Czarnecki D, Carroll S. Imiquimod treatment associated with a reduction in new skin cancer formation. *Clin Exp Dermatol* 2009; 34: 92.
- Gilliet M, Conrad C, Geiges M, Cozzio A, Thürlimann W, Burg G, et al. Psoriasis triggered by toll-like receptor 7 agonist imiquimod in the presence of dermal plasmacytoid dendritic cell precursors. *Arch Dermatol* 2004; 140: 1490–1495.
- Rajan N, Langtry JA. Generalized exacerbation of psoriasis associated with imiquimod cream treatment of superficial basal cell carcinomas. *Australas J Dermatol* 2004; 45: 47–50.
- Patel U, Mark NM, Machler BC, Levine VJ. Imiquimod 5% cream induced psoriasis: a case report, summary of the literature and mechanism. *Br J Dermatol* 2011; 164: 670–672.